


PATIENT PRESENTING CLINICAL SIGNS

Baby Wist REPORTED SYMPTOMS: Drinking more water than normal, and this needed to urinate more as well. Symptoms began 6/13/23.

SPECIES CURRENT MEDICATIONS: None.

Canine EXAM FINDINGS: Baby lost 1.22 pounds since 3/1/23, and now has a normal body score. Dental disease. Nuclear sclerosis.

BREED LAB RESULTS: Chemistry panel reveals elevated albumin, chronically elevated and increasing alk phos, elevated alt, and significantly elevated glucose at 333. Urinalysis reveals glucose at 250, protein 15 with pH of 6.0 and Specific Gravity: 1.029.

SEX ASSESSMENT AND PLAN: Findings are consistent with early diabetes mellitus. However Cushing's disease testing is recommended. Abdominal ultrasound, fructosamine, and urine culture are also recommended. Diet to help stabilize blood glucose levels was discussed.

Spayed Female

ULTRASONOGRAPHIC EXAMINATION OF THE ABDOMEN
AGE
Urinary System

8 years

The urinary bladder is moderately distended with anechoic urine. The bladder wall, trigone, ureteral papillae and visible urethra (to a depth of 2cm) appear normal with no evidence of wall thickening, mucosal irregularities, masses or cystic calculi.

WEIGHT

12.86 lbs

The left kidney has a normal shape and size (4.19 cm). Overall echogenicity is normal with adequate corticomedullary distinction and a typical 1:3 cortex:medulla ratio. There is no evidence of perinephric inflammation or effusion. There is no evidence of pyelectasia, nephroliths, infarcts or hydroureter. Renal vasculature is normal.

INTERPRETED BY

Kathleen Sennello
 DVM, MS, Diplomate
 ACVIM (Small Animal
 Internal Medicine)

The right kidney has a normal shape and size (4.62 cm). Overall echogenicity is normal with adequate corticomedullary distinction and a typical 1:3 cortex:medulla ratio. There is no evidence of perinephric inflammation or effusion. There is no evidence of pyelectasia, nephroliths, infarcts or hydroureter. Renal vasculature is normal.

IMAGING PERFORMED BY

Agnes Rupley, DVM

Adrenal Glands

The left adrenal gland is normal in size (0.46 cm at the caudal pole). It is observed in its normal position cranial to the left renal artery. It is normal in appearance (uniformly hypoechoic) and shape with no evidence of a mass effect.

HOSPITAL NAME

All Pets MC

The area of the right adrenal gland is normal in size. It is observed in its normal position between the cranial aspect of the right kidney and the caudal vena cava. It is normal in appearance (uniformly hypoechoic) and shape with no evidence of a mass effect.

REFERRING VET

Agnes Rupley, DVM

Spleen

The spleen is subjectively normal in size, echotexture is homogenous, and the splenic capsule is smooth with no irregularities. The blood flow through the hilus and splenic parenchyma appears normal. There is a small hypoechoic nodule visualized within the splenic parenchyma (4.10 cm in diameter).

INVOICE

13417

Liver

The liver is subjectively large and hyperechoic with rounded margins. The parenchyma is hyperechoic and homogenous in echotexture. The visible portions of the vasculature and biliary tract appear normal. There

DATE

6.19.23



PATIENT	are numerous variably-sized, small, ill-defined hypoechoic nodules visualized throughout the hepatic parenchyma (examples measure 0.59 x 0.30, 0.51, 0.33, 0.35 cm)
Baby Wist	The gall bladder lumen is moderately distended. The wall of the gall bladder is not thickened and has a smooth mucosal surface. There is a moderate amount of non-organized echogenic debris. The cystic and common bile ducts are normal/not visible.
SPECIES	
Canine	Gastrointestinal
BREED	The stomach contains minimal luminal contents. It measures at a normal thickness of <0.7cm with some variability due to the presence of rugal folds. The distinction of the gastric wall layers is adequate and there is no impression of reduced peristaltic activity. No masses or focal lesions were observed.
Chiweinie	The visualized areas of duodenum, jejunum and ileum have a relatively uniform diameter with minimal fluid distension. Wall thickness is normal. Bowel loops follow a curvilinear path with distinct wall layering maintaining the typical 1:3 muscularis:mucosa layer ratio. The duodenum measured as normal (between 0.3-0.5cm in wall thickness) and the jejunum measured as normal (between 0.2-0.47cm) Visualized peristalsis appears appropriate. There were no focal lesions consistent with obstruction or a mass effect observed.
SEX	
Spayed Female	
AGE	The ileocecal junction was visualized and exhibited normal intact wall layering and is subjectively of normal thickness. Sections of colon are visualized with formed fecal material and gas shadowing distally. There is no observed focal or generalized colon wall thickening or loss of layering.
8 years	
WEIGHT	Pancreas
12.86 lbs	The area of the pancreas is normal and isoechoic to surrounding mesentery. There is no evidence of nodules or cystic lesions. There is no evidence of regional mesenteric inflammation or fluid.
INTERPRETED BY	Free Abdomen
Kathleen Sennello DVM, MS, Diplomate ACVIM (Small Animal Internal Medicine)	Evaluation of the peritoneal cavity did not reveal any evidence of effusion, or subjective lymphadenomegaly. The Medial iliac nodes appear normal and there was no evidence of a caudal aortic thrombus at the bifurcation. The omentum is of normal uniform echogenicity.
IMAGING PERFORMED BY	ULTRASONOGRAPHIC FINDINGS'
Agnes Rupley, DVM	Primary Findings
HOSPITAL NAME	<ul style="list-style-type: none"> Hypoechoic nodule visualized within the spleen - There is a non-cavitated, hypoechoic splenic nodule visualized. Differentials include lymphoid hyperplasia, extramedullary hematopoiesis, infiltrative neoplasia, inflammation, other. Cytology or histopathology would be necessary to get a definitive diagnosis. Large hyperechoic liver with ill-defined hypoechoic nodules – The diffuse hepatic changes are non-specific and can be seen with vacuolar hepatopathy, reactive change, nodular hyperplasia or, less likely, inflammatory/immune-mediated disease, infiltrative neoplasia, or other hepatopathy. The appearance of the ill-defined nodules trends toward the benign process. This is likely consistent with a diabetes hepatopathy. Moderate gallbladder debris - The significance of the aggregated gallbladder debris is unclear. This could represent an early mucocele, cholestasis, or may be secondary to fasting but seems unlikely to be causing a current issue. Recommend continued monitoring.
All Pets MC	
REFERRING VET	
Agnes Rupley, DVM	
INVOICE	
13417	
DATE	
6.19.23	



PATIENT INTERPRETATION OF THE FINDINGS & FURTHER RECOMMENDATIONS

Baby Wist There is a small hypoechoic nodule visualized within the splenic parenchyma. Options for further evaluation would include a fine-needle aspirate or continued monitoring with ultrasound, this could represent a benign or early neoplastic lesion.

SPECIES

Canine The changes observed in the liver are most consistent with a diabetes hepatopathy. It is likely that insulin therapy will need to be instituted in this patient.

BREED

Chiweinie

There is a moderate amount of debris visualized in the gallbladder, but no evidence of inflammation or wall thickening. Recommend continued monitoring +/- Ursodiol therapy. No obvious factors are identified to complicate a diagnosis of diabetes mellites.

SEX

Recommend three-view thoracic radiographs to evaluate for possible concurrent thoracic disease/involvement.

Spayed Female

AGE

8 years

WEIGHT

12.86 lbs

INTERPRETED BY

Kathleen Sennello
DVM, MS, Diplomate
ACVIM (Small Animal
Internal Medicine)

IMAGING PERFORMED BY

Agnes Rupley, DVM

HOSPITAL NAME

All Pets MC

REFERRING VET

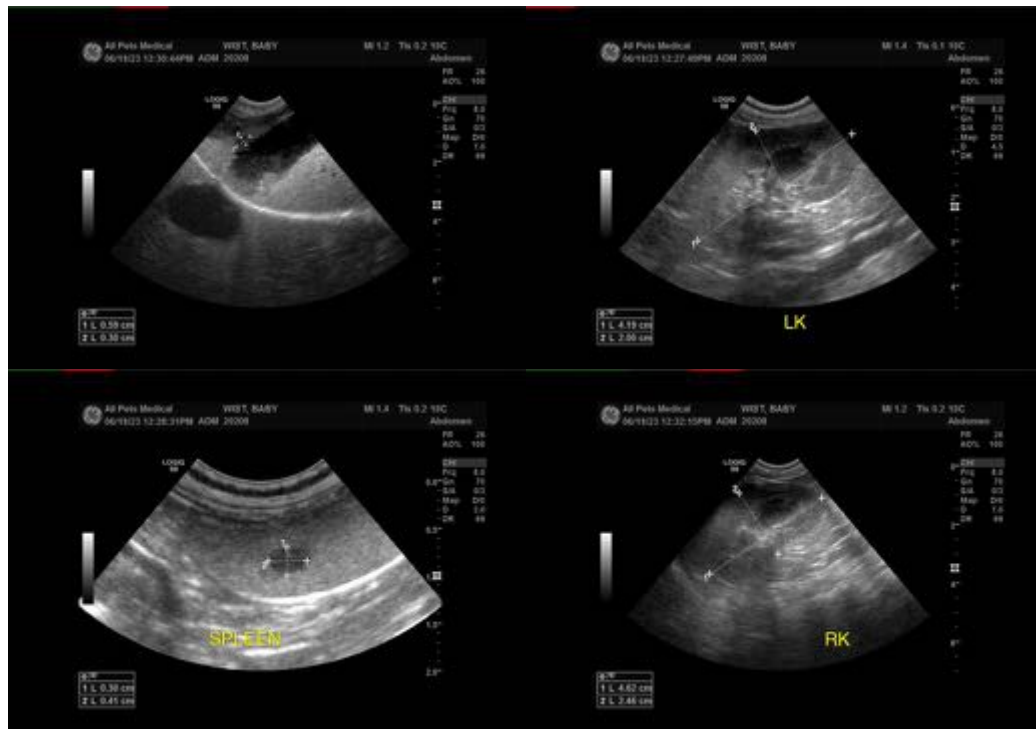
Agnes Rupley, DVM

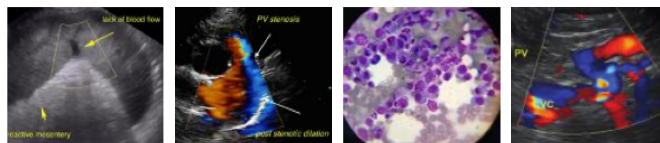
INVOICE

13417

DATE

6.19.23





PATIENT

Baby Wist

SPECIES

Canine

BREED

Chiweinie

SEX

Spayed Female

AGE

8 years

WEIGHT

12.86 lbs

INTERPRETED BY

Kathleen Sennello
DVM, MS, Diplomate
ACVIM (Small Animal
Internal Medicine)

**IMAGING
PERFORMED BY**

Agnes Rupley, DVM

HOSPITAL NAME

All Pets MC

REFERRING VET

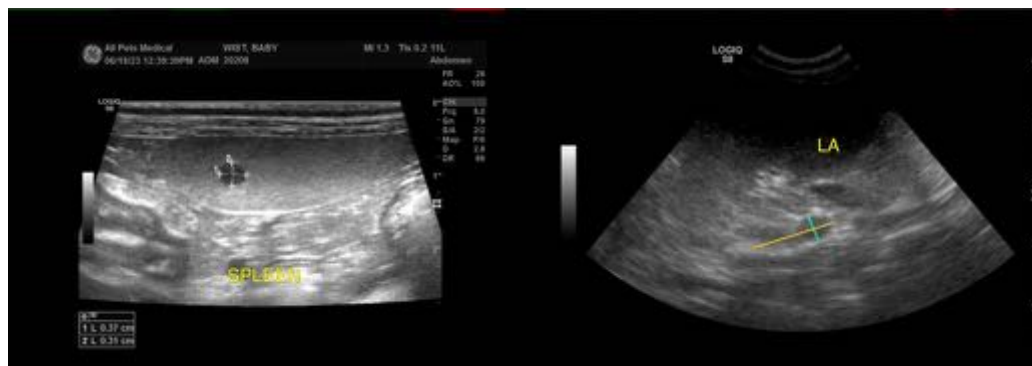Agnes Rupley, DVM

INVOICE

13417

DATE

6.19.23



The information and recommendations provided are based on the images presented by the referring veterinarian. No evaluation can be communicated regarding pathology that was not visible in the image/video clips provided.

Thank you for this referral. If the clinical or image interpretation does not parallel your findings or if I can be of any further assistance, please contact me.

Kathleen Sennello DVM, MS, Diplomate ACVIM (Small animal Internal Medicine)
info@SonoPath.com