

**PATIENT**

Lucy Jobling

**SPECIES**

Canine

**BREED**

Maltese x

**SEX**

Spayed Female

**AGE**

9 Years

**WEIGHT**

5.3 kg

**INTERPRETED BY**

Kathleen Sennello DVM,  
 MS, Diplomate ACVIM  
 (Small Animal Internal  
 Medicine)

**IMAGING PERFORMED BY**

Kelly Reschny

**HOSPITAL NAME**

BPH Stoney Creek

**REFERRING VET**

Dr. Salib

**INVOICE**

75971

**DATE**

6/17/26

**PRESENTING CLINICAL SIGNS**

A reducible, soft, non-painful umbilical hernia measuring approximately 2.5 cm in diameter is present. The contents feel consistent with fat. A small potential defect in the abdominal wall is palpable.

**ULTRASONOGRAPHIC EXAMINATION OF THE ABDOMEN**

**Urinary System**

The urinary bladder is moderately distended with anechoic urine. The Bladder wall, trigone, ureteral papillae and visible urethra (to a depth of 2cm) appear normal with no evidence of wall thickening, mucosal irregularities, masses or cystic calculi.

The left kidney has a normal shape and size (3.71 cm). Overall echogenicity is normal with adequate corticomedullary distinction and a typical 1:3 cortex:medulla ratio. There is no evidence of focal perinephric inflammation or effusion. There is no evidence of pyelectasia, nephroliths, infarcts or hydroureter. Renal vasculature is normal.

The right kidney has a normal shape and size (3.0 cm). Overall echogenicity is normal with adequate corticomedullary distinction and a typical 1:3 cortex:medulla ratio. There is no evidence of focal perinephric inflammation or effusion. There is no evidence of pyelectasia, nephroliths, infarcts or hydroureter. Renal vasculature is normal.

**Adrenal Glands**

The left adrenal gland is normal in size measuring 0.46 cm at the cranial pole and 0.36 cm at the caudal pole. It is observed in its normal position cranial to the left renal artery. It is normal in appearance (uniformly hypoechoic) and shape with no evidence of a mass effect.

The right adrenal gland is normal in size measuring 1.22 cm at the cranial pole and 0.68 cm at the caudal pole. It is observed in its normal position between the cranial aspect of the right kidney and the caudal vena cava. It is normal in appearance (uniformly hypoechoic) and shape with no evidence of a mass effect.

**Spleen**

The spleen is subjectively normal in size (1.32 cm), echotexture is homogenous, and the splenic capsule is smooth with no irregularities. The blood flow through the hilus and splenic parenchyma appears normal. No focal parenchymal abnormalities are visualized.

**Liver**

The liver is subjectively normal in size, and echogenicity with smooth peripheral margins. The parenchyma is homogenous echotexture. The visible portions of the vasculature and biliary tract appear normal. No focal nodules or cystic lesions are observed.

The gall bladder lumen is moderately distended. The wall of the gall bladder is not thickened and has a smooth mucosal surface. Luminal contents are mild and likely incidental at this time. The cystic and common bile ducts are normal/not visible.



**PATIENT**

Lucy Jobling

**SPECIES**

Canine

**BREED**

Maltese x

**SEX**

Spayed Female

**AGE**

9 Years

**WEIGHT**

5.3 kg

**INTERPRETED BY**

Kathleen Sennello DVM,  
 MS, Diplomate ACVIM  
 (Small Animal Internal  
 Medicine)

**IMAGING PERFORMED BY**

Kelly Reschny

**HOSPITAL NAME**

BPH Stoney Creek

**REFERRING VET**

Dr. Salib

**INVOICE**

75971

**DATE**

6/17/26

***Gastrointestinal***

The stomach contains a large amount of fluid and shadowing ingesta. It measures at a normal thickness of <0.7cm with some variability due to the presence of rugal folds. The distinction of the gastric wall layers is adequate and there is no impression of reduced peristaltic activity. Shadowing ingesta interferes with full evaluation of the stomach and some areas of the cranial abdomen.

The visualized areas of duodenum, jejunum and ileum have a relatively uniform diameter with minimal fluid distension. Wall thickness is normal. Bowel loops follow a curvilinear path with distinct wall layering maintaining the typical 1:3 muscularis:mucosa layer ratio. Jejunum wall measures 0.27 cm. Visualized peristalsis appears appropriate. There were no focal lesions consistent with obstruction or a mass effect observed.

Sections of colon are visualized with formed fecal material and gas shadowing distally. There is no observed focal or generalized colon wall thickening or loss of layering.

***Pancreas***

The area of the pancreas is normal and isoechoic to surrounding mesentery. There is no evidence of nodules or cystic lesions. There is no evidence of regional mesenteric inflammation or fluid.

***Free Abdomen***

Evaluation of the peritoneal cavity did not reveal any evidence of effusion, or subjective lymphadenomegaly. The Medial iliac nodes appear normal and there was no evidence of a caudal aortic thrombus at the bifurcation. The omentum is of normal uniform echogenicity.

***Other***

A small defect is visualized in the body wall in the mid abdominal region/cranial to the urinary bladder, measuring approximately 0.50 cm with hypoechoic unstructured material passing through, most consistent with mesentery at this time.

**ULTRASONOGRAPHIC FINDINGS**

- Large, fluid/ingested distended stomach – Findings are most consistent with a post-prandial patient. If the patient was adequately fasted, consider the possibility of delayed gastric emptying or a partial outflow tract obstruction.
- Small umbilical hernia – At this time there is no evidence of bowel or other structures within the herniation.

**INTERPRETATION OF THE FINDINGS & FURTHER RECOMMENDATIONS**

The majority of today's scan is normal. There is a small defect in the body wall most consistent with a sliding umbilical hernia. At this time there is no bowel visualized within the herniation, but this can change over time.



**PATIENT**

Lucy Jobling

**SPECIES**

Canine

**BREED**

Maltese x

**SEX**

Spayed Female

**AGE**

9 Years

**WEIGHT**

5.3 kg

**INTERPRETED BY**

Kathleen Sennello DVM,  
 MS, Diplomate ACVIM  
 (Small Animal Internal  
 Medicine)

**IMAGING  
 PERFORMED BY**

Kelly Reschny

**HOSPITAL NAME**

BPH Stoney Creek

**REFERRING VET**

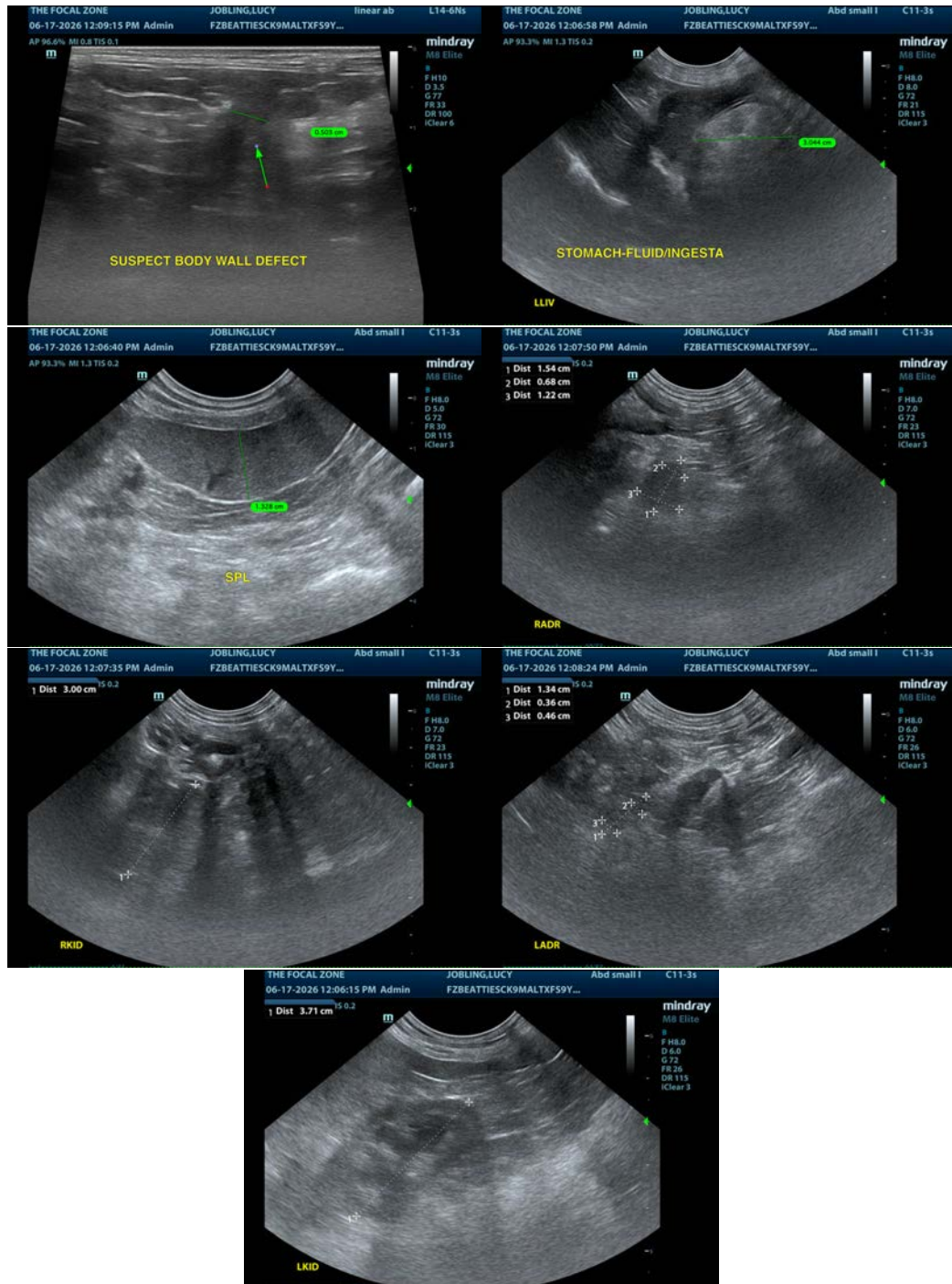
Dr. Salib

**INVOICE**

75971

**DATE**

6/17/26





**PATIENT**

Lucy Jobling

**SPECIES**

Canine

**BREED**

Maltese x

**SEX**

Spayed Female

**AGE**

9 Years

**WEIGHT**

5.3 kg

**INTERPRETED BY**

Kathleen Sennello DVM,  
MS, Diplomate ACVIM  
(Small Animal Internal  
Medicine)

**IMAGING  
PERFORMED BY**

Kelly Reschny

**HOSPITAL NAME**

BPH Stoney Creek

**REFERRING VET**

Dr. Salib

**INVOICE**

75971

**DATE**

6/17/26

**The information and recommendations provided are based on the images presented by the referring veterinarian/sonographer. No evaluation can be communicated regarding pathology that was not visible in the image/video clips provided.**

Thank you for this referral. If the clinical or image interpretation does not parallel your findings or if I can be of any further assistance please contact me.

Kathleen Sennello DVM,MS, Diplomate ACVIM (Small animal Internal Medicine)

[info@sonopath.com](mailto:info@sonopath.com)