

**DATE PRESENTING CLINICAL SIGNS**

6.15.2023

Patient was presented on 06/01/2023 for eating excessive amounts of grass and throwing up. Chem 10 was normal and he was started on Prilosec 20 mg SID, Sucralfate 1 gm PO BID and gabapentin 400 mg PO BID. Initially Kolby's vomiting improved but in the last 24-48 hours it has returned and he was vomited contents of his stomach 3x.

PATIENT

Kolby Lipinski

Current Medications: Prilosec 20 mg PO SID since 06/01, Gabapentin 400 mg BID since 06/01, Sucralfate 1 gm BID since 06/01

SPECIES

Canine

Date of Previous IntraPet Ultrasound: No previous.

Sedation: IV.

Stat Report: Not requested.

Imaging Performed By: Rachel Brillhart, RDMS.

BREED

Pitbull

ULTRASONOGRAPHIC EXAMINATION OF THE ABDOMEN**SEX**

Neutered Male

Urinary System

The urinary bladder is moderately distended with anechoic urine. The bladder wall, trigone, ureteral papillae and visible urethra (to a depth of 2cm) appear normal with no evidence of wall thickening, mucosal irregularities, masses or cystic calculi.

AGE

3/12/2012

The visualized areas of prostate and surrounding tissue appear normal. Unfortunately, the prostate is not fully visualized likely due to its intrapelvic location. Correlate with rectal exam findings.

WEIGHT

80lbs

The left kidney has a normal shape and size (6.84 cm). Overall echogenicity is normal with adequate corticomedullary distinction and a typical 1:3 cortex:medulla ratio. There is no evidence of perinephric inflammation or effusion. There is no evidence of pyelectasia, nephroliths, infarcts or hydroureter. Renal vasculature is normal.

INTERPRETED BY

Kathleen Sennello
DVM, MS, Diplomate
ACVIM (Small Animal
Internal Medicine)

The right kidney has a normal shape and size (7.23 cm). Overall echogenicity is normal with adequate corticomedullary distinction and a typical 1:3 cortex:medulla ratio. There is no evidence of perinephric inflammation or effusion. There is no evidence of pyelectasia, nephroliths, infarcts or hydroureter. Renal vasculature is normal.

HOSPITAL NAME

Madonna VC

Adrenal Glands

The left adrenal gland is normal in size (0.60 cm at the caudal pole). It is observed in its normal position cranial to the left renal artery. It is normal in appearance (uniformly hypoechoic) and shape with no evidence of a mass effect.

REFERRING VET

Dr. Smith

The right adrenal gland is normal in size (0.85 cm at the caudal pole). It is observed in its normal position between the cranial aspect of the right kidney and the caudal vena cava. It is normal in appearance (uniformly hypoechoic) and shape with no evidence of a mass effect.

INVOICE

13385

Spleen

The spleen is subjectively normal in size, echotexture is homogenous, and the splenic capsule is smooth with no irregularities. The blood flow through the hilus and splenic parenchyma appears normal. No focal parenchymal abnormalities are visualized.

Liver

The liver is subjectively normal in size, and echogenicity with smooth peripheral margins. The parenchyma is heterogenous in echotexture with subtle, indistinct focal mottling. The visible portions of the vasculature and biliary tract appear normal. No focal nodules or cystic lesions are observed.

Gastrointestinal

The stomach is moderately dilated with fluid and ingesta. It measures at a normal thickness of <0.7 cm with some variability due to the presence of rugal folds. The distinction of the gastric wall layers is adequate and there is no impression of reduced peristaltic activity. No masses or focal lesions were observed.

The visualized areas of duodenum, jejunum and ileum have a relatively uniform diameter with minimal to mild fluid distension. Wall thickness is normal. Bowel loops follow a curvilinear path with distinct wall layering maintaining the typical 1:3 muscularis:mucosa layer ratio. The duodenum measured as normal (between 0.3-0.5cm in wall thickness) and the jejunum measured as normal (0.33 cm) Visualized peristalsis appears appropriate. There are some sections of bowel which appear to have some moderate fluid-distention. No focal obstructive material is visualized.

The ileocecal junction was visualized and exhibited normal intact wall layering and is subjectively of normal thickness. Sections of colon are visualized with formed fecal material and gas shadowing distally. There is no observed focal or generalized colon wall thickening or loss of layering.

Pancreas

The pancreas is prominent and mottled compared to the surrounding isoechoic mesentery. There is no evidence of nodules or cystic lesions. There is no evidence of regional mesenteric inflammation or fluid.

Free Abdomen

Evaluation of the peritoneal cavity did not reveal any evidence of effusion, or subjective lymphadenomegaly. The Medial iliac nodes appear normal and there was no evidence of a caudal aortic thrombus at the bifurcation. The omentum is of normal uniform echogenicity.

ULTRASONOGRAPHIC FINDINGS

- Prominent mottle pancreas - The pancreatic changes are most consistent with mild pancreatitis or a recent episode of pancreatic inflammation.
- Heterogenous liver - The hepatic changes are consistent with age-related parenchymal remodeling and are not considered clinically significant at this time.
- Fluid-dilated stomach with some areas of mild small intestinal fluid dilation – no obvious shadowing foreign material is visualized and no mass lesions are observed. The primary differential at this time would be ileus and/or delayed gastric emptying, although serial monitoring is warranted.

INTERPRETATION OF THE FINDINGS & FURTHER RECOMMENDATIONS

No focal bowel lesions are visualized to explain the chronic intermittent vomiting reported. There is some fluid dilation of the stomach and small intestine. Correlate this with feeding history and abdominal radiographs. No focal obstructions are visualized, or masses, but it is difficult to definitively rule out ingested foreign material. At this time, I would most strongly suspect ileus due to severe gastroenteritis. But continued monitoring and serial imaging is warranted.

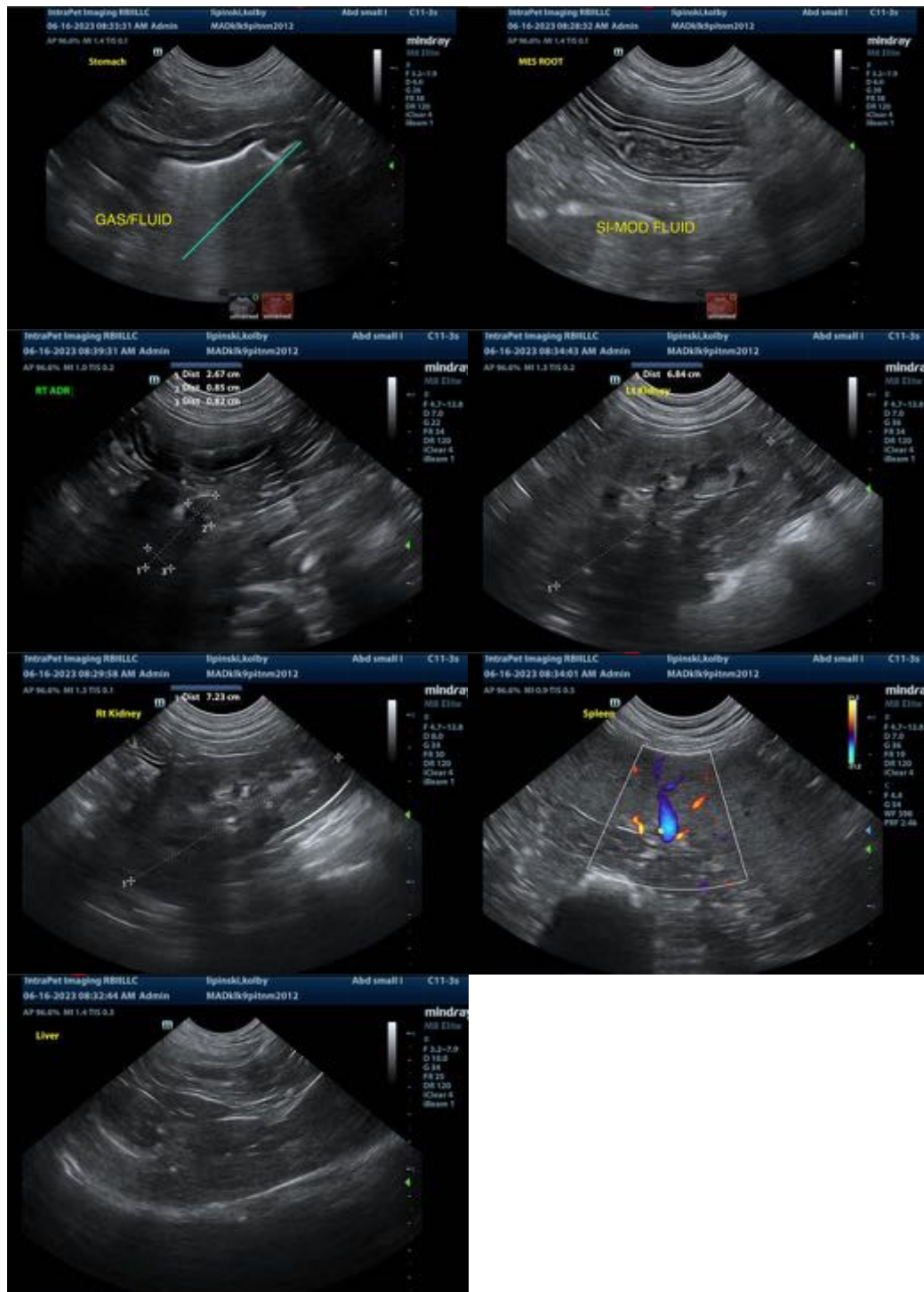
Consider such differentials as food allergy/dietary intolerance, GI parasitism, pancreatitis, dysbiosis, recurrent dietary indiscretion, IBD and less likely neoplasia, etc.

Consider a novel protein/hydrolyzed protein diet (exclusively at least 4-6 weeks)

Consider a GI panel to Texas A&M for evaluation of B12 levels, folate, PLI/TLI etc. to further evaluate for pancreatic/small intestinal disease.

Recommend chronic probiotic therapy.

Recommend empirical treatment for acute gastroenteritis/pancreatitis, with close, continued monitoring.



The information and recommendations provided are based on the images presented by the referring veterinarian. No evaluation can be communicated regarding pathology that was not visible in the image/video clips provided.

Thank you for this referral. If the clinical or image interpretation does not parallel your findings or if I can be of any further assistance, please contact me.

Kathleen Sennello DVM, MS, Diplomate ACVIM (Small animal Internal Medicine)
info@SonoPath.com