



PATIENT

Waldo Magnone

PRESENTING CLINICAL SIGNS

SPECIES

Canine

BREED

West Highland
Terrier

SEX

Neutered Male

AGE

8 Years 11 Months

WEIGHT

24.6 Pounds

INTERPRETED BY

Kathleen Sennello DVM,
MS, Diplomate ACVIM
(Small Animal Internal
Medicine)

IMAGING BY

Loetitia Saint-Jacques,
LVT

HOSPITAL NAME

MountainView AH

REFERRING VET

Dr. Sarah Kalivoda

INVOICE

38784

DATE

6/16/22

PAWS Request Form: Chief Concern / Provisional Diagnosis: ~origin of abdominal mass-vomitting chronic~ Relevant Medical History and Physical Exam findings: ~ ~ large mass in the cranial abdomen causing mass effect~~ Recent Diagnostics: Relevant Laboratory Results / Abnormalities: ~emailed bloodwork~ Current medications (include full name, dosage and frequency): ~pre/probiotics, Credelio Chewables, HG~
Abnormal PE/Chem/CBC/UA Results: sedated dexdormitor/butorphanol

ULTRASONOGRAPHIC EXAMINATION OF THE ABDOMEN

Urinary System

The urinary bladder is moderately distended with anechoic urine. The Bladder wall, trigone, ureteral papillae and visible urethra (to a depth of 2cm) appear normal with no evidence of wall thickening, mucosal irregularities, masses or cystic calculi.

The prostate is normal in size (0.95 cm) and shape for this neutered male dog. The parenchyma is homogenous and the external margins are smooth. The prostatic urethra appears normal with no evidence of irregularity, invasion, mass effect or calculi.

The left kidney has a normal shape and size (5.42 cm). Overall echogenicity is normal with adequate corticomedullary distinction and a typical 1:3 cortex:medulla ratio. There is no evidence of perinephric inflammation or effusion. There is no evidence of pyelectasia, nephroliths, infarcts or hydroureter. Renal vasculature is normal.

The right kidney has a normal shape and size (5.46 cm). Overall echogenicity is normal with adequate corticomedullary distinction and a typical 1:3 cortex:medulla ratio. There is no evidence of perinephric inflammation or effusion. There is no evidence of pyelectasia, nephroliths, infarcts or hydroureter. Renal vasculature is normal.

Adrenal Glands

The left adrenal gland is normal in size measuring 0.68 cm at the caudal pole. It is observed in its normal position cranial to the left renal artery. It is normal in appearance (uniformly hypoechoic) and shape with no evidence of a mass effect.

The right adrenal gland is normal in size measuring 0.42 cm at the caudal pole. It is observed in its normal position between the cranial aspect of the right kidney and the caudal vena cava. It is normal in appearance (uniformly hypoechoic) and shape with no evidence of a mass effect.

Spleen

The spleen is large in size and irregular. The spleen echotexture is heterogenous and mottled. The blood flow through the hilus and splenic parenchyma appears normal. There is a very large, mixed echogenic, partially cavitated mass effect in the cranial abdomen, and appears to be arising from the spleen. This lesion measures >9.86 cm x 11.37 cm.

Liver

The liver is subjectively normal in size, and echogenicity with smooth peripheral margins. The parenchyma is homogenous echotexture. The visible portions of the vasculature and biliary tract appear normal. No focal nodules or cystic lesions are observed.



Portable Animal Wellness Sonography, Inc.

IMAGING PERFORMED BY

pawsonography@gmail.com  530-786-8340

PATIENT

Waldo Magnone

The gall bladder lumen is moderately distended. The wall of the gall bladder is not thickened and has a smooth mucosal surface. There is a moderate amount of non-organized echogenic debris. The cystic and common bile ducts are normal/not visible.

SPECIES

Canine

Gastrointestinal

The stomach contains minimal luminal contents. It measures at a normal thickness of <0.7cm with some variability due to the presence of rugal folds. The distinction of the gastric wall layers is adequate and there is no impression of reduced peristaltic activity. No masses or focal lesions were observed.

BREED

West Highland
Terrier

The visualized areas of duodenum, jejunum and ileum have a relatively uniform diameter with minimal fluid distension. Wall thickness is normal. Bowel loops follow a curvilinear path with distinct wall layering maintaining the typical 1:3 muscularis:mucosa layer ratio. Duodenum wall measured 0.42 cm. Jejunum wall measured 0.37 cm. Visualized peristalsis appears appropriate. There were no focal lesions consistent with obstruction or a mass effect observed.

SEX

Neutered Male

The ileocecal junction was visualized and exhibited normal intact wall layering and is subjectively of normal thickness. Sections of colon are visualized with formed fecal material and gas shadowing distally. There is no observed focal or generalized colon wall thickening or loss of layering.

AGE

8 Years 11 Months

Pancreas

The pancreas is normal and isoechoic to surrounding mesentery. There is no evidence of nodules or cystic lesions. There is no evidence of regional mesenteric inflammation or fluid.

WEIGHT

24.6 Pounds

Free Abdomen

Evaluation of the peritoneal cavity did not reveal any evidence of effusion, or subjective lymphadenomegaly. The Medial iliac nodes appear normal and there was no evidence of a caudal aortic thrombus at the bifurcation. The omentum is of normal uniform echogenicity.

INTERPRETED BY

Kathleen Sennello DVM,
MS, Diplomate ACVIM
(Small Animal Internal
Medicine)

Other

A brief view of the heart was submitted. No significant pericardial effusion was seen.

ULTRASONOGRAPHIC FINDINGS

IMAGING BY

Loetitia Saint-Jacques,
LVT

- Large, mixed echogenic, mildly cavitated splenic mass – A large, heterogenous mass with cavitations is present within the splenic parenchyma. The mass distorts the splenic capsule. Differentials for the mass include neoplasia (e.g., hemangiosarcoma, hemangioma), hematoma, abscess, other. A neoplastic process is favored.

HOSPITAL NAME

MountainView AH

- Mild gallbladder debris – The significance of the aggregated gallbladder sludge is unclear. This could represent an early mucocele, cholestasis, or may be secondary to fasting.

REFERRING VET

Dr. Sarah Kalivoda

INTERPRETATION OF THE FINDINGS & FURTHER RECOMMENDATIONS

There is a large cranial abdominal mass that appears to be arising from a very irregular/abnormal spleen. Recommend splenectomy for both diagnostic and therapeutic purposes. No overt lesions are visualized in other areas on this scan. Recommend 3-view thoracic radiographs to look for evidence of concurrent intrathoracic disease or metastasis.

INVOICE

38784

DATE

6/16/22



PATIENT

Waldo Magnone

SPECIES

Canine

BREED

West Highland Terrier

SEX

Neutered Male

AGE

8 Years 11 Months

WEIGHT

24.6 Pounds

INTERPRETED BY

Kathleen Sennello DVM,
MS, Diplomate ACVIM
(Small Animal Internal
Medicine)

IMAGING BY

Loetitia Saint-Jacques,
LVT

HOSPITAL NAME

MountainView AH

REFERRING VET

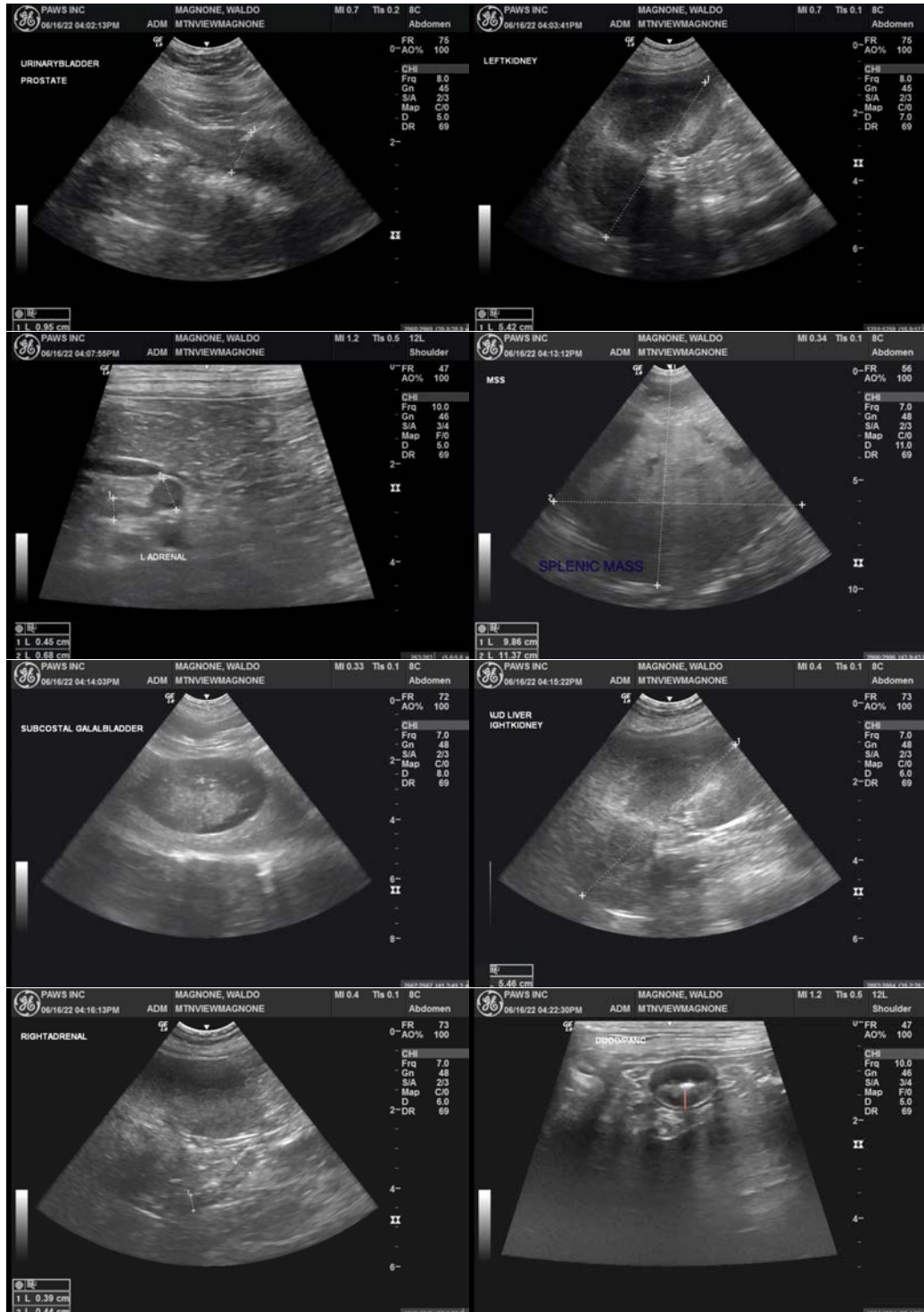
Dr. Sarah Kalivoda

INVOICE

38784

DATE

6/16/22





PATIENT

Waldo Magnone

SPECIES

Canine

BREED

West Highland
Terrier

SEX

Neutered Male

AGE

8 Years 11 Months

WEIGHT

24.6 Pounds

INTERPRETED BY

Kathleen Sennello DVM,
MS, Diplomate ACVIM
(Small Animal Internal
Medicine)

IMAGING BY

Loetitia Saint-Jacques,
LVT

HOSPITAL NAME

MountainView AH

REFERRING VET

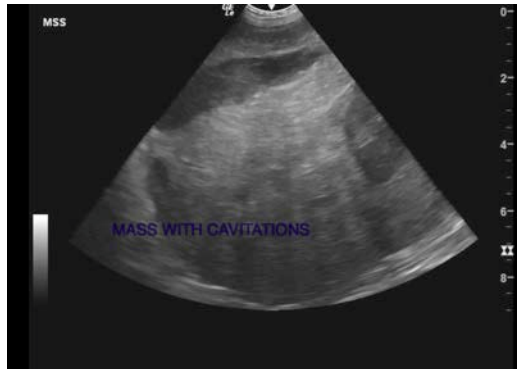
Dr. Sarah Kalivoda

INVOICE

38784

DATE

6/16/22



The information and recommendations provided are based on the images presented by the referring veterinarian/sonographer. No evaluation can be communicated regarding pathology that was not visible in the image/video clips provided.

Thank you for this referral. If the clinical or image interpretation does not parallel your findings or if I can be of any further assistance please contact me.

Kathleen Sennello DVM,MS, Diplomate ACVIM (Small animal Internal Medicine)
kathleen.sennello@sonopath.com