

**DATE PRESENTING CLINICAL SIGNS**

6/16/22

Recently urinating and defecating in house which historically pt has done when something has been wrong health wise. Hx of lupus, seizures, CUPS, intra-abdominal lipoma, and oral malignant melanoma (currently ~1.5 years out from dgx).

PATIENT

Rocky Kennedy

Current Medications: Clindamycin, Phenobarbital, Gabapentin.
Lab Results: Attached.

SPECIES

Canine

Date of Previous IntraPet Ultrasound: No previous.
Sedation: Not required to complete full diagnostic ultrasound.
Stat Report: Not requested.

BREED

Doberman

ULTRASONOGRAPHIC EXAMINATION OF THE ABDOMEN**Urinary System**

The urinary bladder is moderately distended with anechoic urine. The Bladder wall, trigone, ureteral papillae and visible urethra (to a depth of 2cm) appear normal with no evidence of wall thickening, mucosal irregularities, masses or cystic calculi.

SEX

Neutered Male

The prostate is normal in size (1.3 cm) and shape for this neutered male dog. The parenchyma is homogenous and the external margins are smooth. The prostatic urethra appears normal with no evidence of irregularity, invasion, mass effect or calculi.

AGE

1/24/11

The left kidney has a normal shape and size (6.3 cm) with pinpoint non-obstructive nephroliths. Overall echogenicity is normal with adequate corticomedullary distinction and a typical 1:3 cortex:medulla ratio. There is no evidence of perinephric inflammation or effusion. There is no evidence of pyelectasia, infarcts or hydroureter. Renal vasculature is normal.

WEIGHT

72 Pounds

INTERPRETED BY

Kathleen Sennello DVM,
MS, Diplomate ACVIM
(Small Animal Internal
Medicine)

The right kidney has a normal shape and size (7.0 cm) with pinpoint non-obstructive nephroliths.. Overall echogenicity is normal with adequate corticomedullary distinction and a typical 1:3 cortex:medulla ratio. There is no evidence of perinephric inflammation or effusion. There is no evidence of pyelectasia, infarcts or hydroureter. Renal vasculature is normal.

IMAGING PERFORMED BY

Andi Parkinson RDMS

Adrenal Glands

The left adrenal gland is normal in size measuring 0.72 cm at the caudal pole. It is observed in its normal position cranial to the left renal artery. It is normal in appearance (uniformly hypoechoic) and shape with no evidence of a mass effect.

HOSPITAL NAME

Bayside AMC

The right adrenal gland is normal in size measuring 0.70 cm at the caudal pole. It is observed in its normal position between the cranial aspect of the right kidney and the caudal vena cava. It is normal in appearance (uniformly hypoechoic) and shape with no evidence of a mass effect.

REFERRING VET

Dr. Buchanan

Spleen

The spleen is subjectively normal in size, echotexture is homogenous, and the splenic capsule is smooth with no irregularities. The blood flow through the hilus and splenic parenchyma appears normal. No focal parenchymal abnormalities are visualized.

INVOICE

38787

Liver

The liver is subjectively normal in size, and echogenicity with smooth peripheral margins. The parenchyma is homogenous echotexture. The visible portions of the vasculature and biliary tract appear normal. No focal nodules or cystic lesions are observed.

The gallbladder lumen is moderately distended. The wall of the gall bladder is not thickened and has a smooth mucosal surface. Luminal contents are primarily anechoic. The cystic and common bile ducts are normal/not visible.

Gastrointestinal

The stomach is moderately to severely dilated with irregular shadowing material. It measures at a normal thickness of <0.7cm with some variability due to the presence of rugal folds. The distinction of the gastric wall layers is adequate and there is no impression of reduced peristaltic activity. There is a focal hard shadowing object visualized, measuring approximately 3.0 cm in diameter, most consistent with ingested foreign material or solid ingesta.

The visualized areas of duodenum, jejunum and ileum have a relatively uniform diameter with minimal fluid distension. Wall thickness is normal. Bowel loops follow a curvilinear path with distinct wall layering maintaining the typical 1:3 muscularis:mucosa layer ratio. Jejunum wall measured 0.38 cm. Visualized peristalsis appears appropriate. There were no focal lesions consistent with obstruction or a mass effect observed.

The ileocecal junction was visualized and exhibited normal intact wall layering and is subjectively of normal thickness. Sections of colon are visualized with formed fecal material and gas shadowing distally. There is no observed focal or generalized colon wall thickening or loss of layering.

Pancreas

The pancreas is normal and isoechoic to surrounding mesentery. There is no evidence of nodules or cystic lesions. There is no evidence of regional mesenteric inflammation or fluid.

Free Abdomen

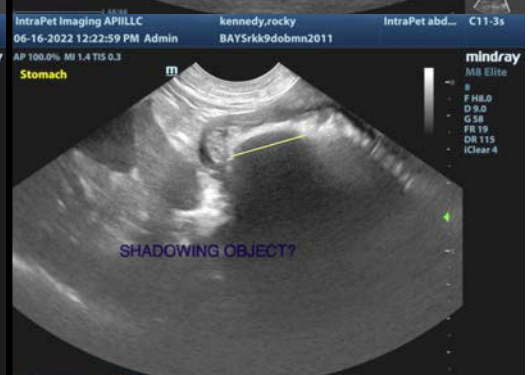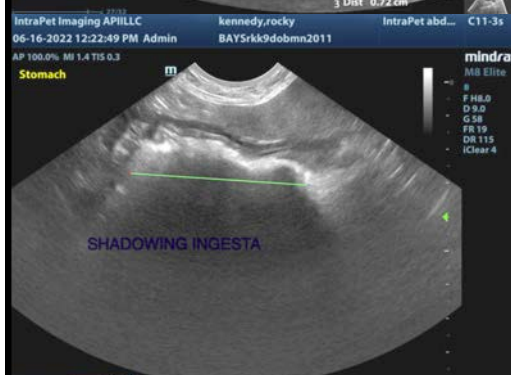
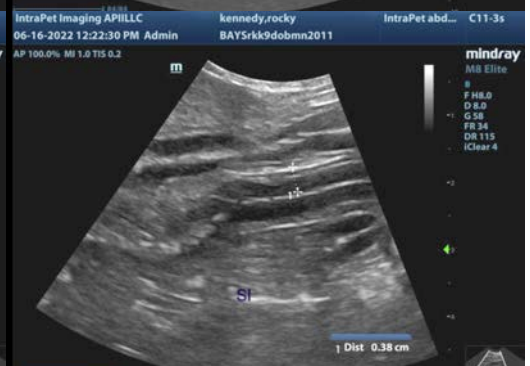
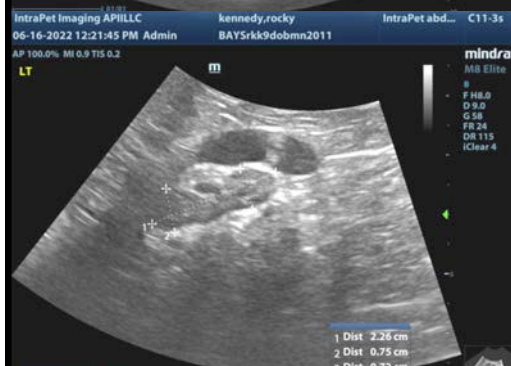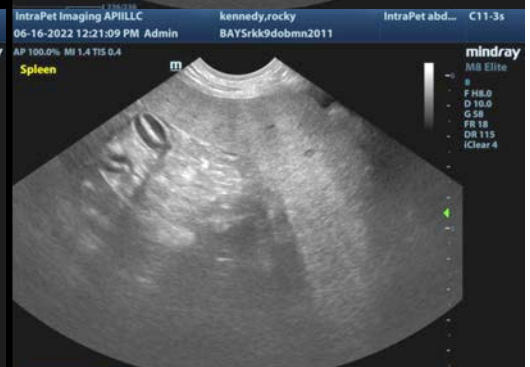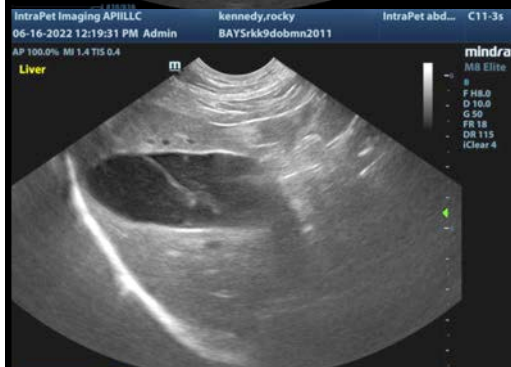
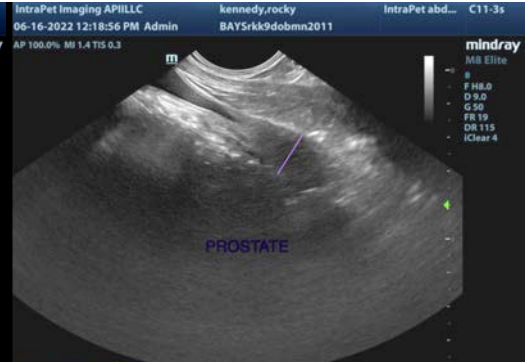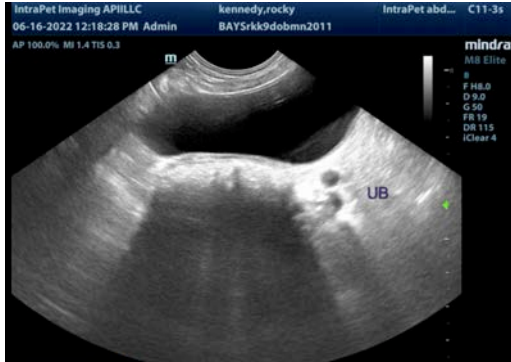Evaluation of the peritoneal cavity did not reveal any evidence of effusion, or subjective lymphadenomegaly. The Medial iliac nodes appear normal and there was no evidence of a caudal aortic thrombus at the bifurcation. The omentum is of normal uniform echogenicity.

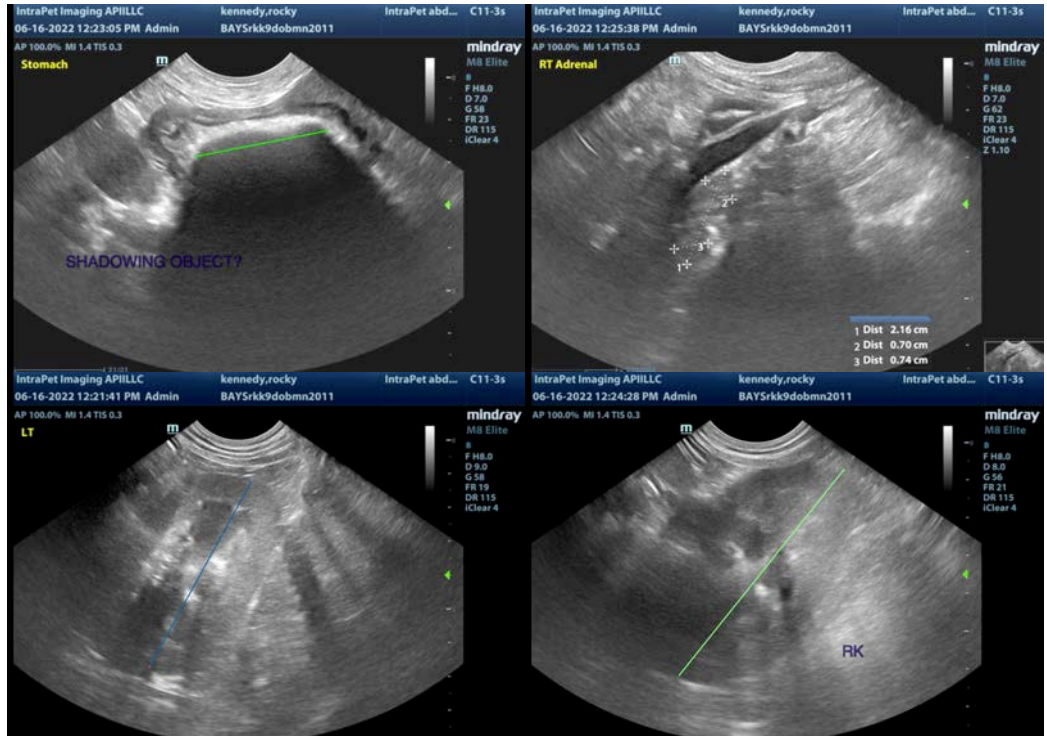
ULTRASONOGRAPHIC FINDINGS

- Shadowing material visualized within the gastric lumen – correlate with feeding history and abdominal radiographs. This could represent a solid, unchewed chunk of food, a toy, etc.
- Pinpoint non-obstructive nephroliths in both kidneys – The hyperechoic mineralized foci observed at the corticomedullary junction of the left/right kidney are consistent with small, non-obstructive nephroliths.

INTERPRETATION OF THE FINDINGS & FURTHER RECOMMENDATIONS

Today's ultrasound appears largely normal. There is a hard shadowing objective visualized within the gastric lumen. Correlate with feeding history, abdominal radiographs, etc. This could be a piece of unchewed, firm food, or foreign material. Follow with serial radiographs to determine if the stomach empties. If this persists, you could consider upper GI endoscopy to further investigate. If symptoms persist, consider full bloodwork (with an albumin, calcium, etc.), and 3-view thoracic radiographs.





The information and recommendations provided are based on the images presented by the referring veterinarian/sonographer. No evaluation can be communicated regarding pathology that was not visible in the image/video clips provided.

Thank you for this referral. If the clinical or image interpretation does not parallel your findings or if I can be of any further assistance please contact me.

Kathleen Sennello DVM,MS, Diplomate ACVIM (Small animal Internal Medicine)
kathleen.sennello@sonopath.com