



PATIENT

Maisie Plotkin

SPECIES

Canine

BREED

Standard Poodle

SEX

Spayed Female

AGE

7 Years

WEIGHT

59 Pounds

INTERPRETED BY

Kathleen Sennello DVM,
MS, Diplomate ACVIM
(Small Animal Internal
Medicine)

**IMAGING
PERFORMED BY**

Dr. Tam Mengine

HOSPITAL NAME

Stoney Creek VH

REFERRING VET

Dr. Tam Mengine

INVOICE

38769

DATE

6/16/22

PRESENTING CLINICAL SIGNS

1-2 history year of intermittent vomiting and large bowel diarrhea - diarrhea much more common than vomiting. Responsive to metronidazole, but then returns. CBC / Chem, resting cortisol, ultrasound and GI profile performed 8/21, all unremarkable. Fecals in 8/21 and 5/22 negative (O&P + antigen) No response to i/d low fat nor z/d diet trial. Weight stable.

ULTRASONOGRAPHIC EXAMINATION OF THE ABDOMEN

Urinary System

The urinary bladder is moderately distended with anechoic urine. The Bladder wall, trigone, ureteral papillae and visible urethra (to a depth of 2cm) appear normal with no evidence of wall thickening, mucosal irregularities, masses or cystic calculi.

The left kidney has a normal shape and size (6.14 cm). Overall echogenicity is normal with adequate corticomedullary distinction and a typical 1:3 cortex:medulla ratio. There is no evidence of perinephric inflammation or effusion. There is no evidence of pyelectasia, nephroliths, infarcts or hydroureter. Renal vasculature is normal.

The right kidney has a normal shape and size (6.65 cm). Overall echogenicity is normal with adequate corticomedullary distinction and a typical 1:3 cortex:medulla ratio. There is no evidence of perinephric inflammation or effusion. There is no evidence of pyelectasia, nephroliths, infarcts or hydroureter. Renal vasculature is normal.

Adrenal Glands

The left adrenal gland is normal in size measuring 0.52 cm at the caudal pole. It is observed in its normal position cranial to the left renal artery. It is normal in appearance (uniformly hypoechoic) and shape with no evidence of a mass effect.

The right adrenal gland is normal in size measuring 0.45 cm at the caudal pole. It is observed in its normal position between the cranial aspect of the right kidney and the caudal vena cava. It is normal in appearance (uniformly hypoechoic) and shape with no evidence of a mass effect.

Spleen

The spleen is subjectively normal in size, echotexture is homogenous, and the splenic capsule is smooth with no irregularities. The blood flow through the hilus and splenic parenchyma appears normal. No focal parenchymal abnormalities are visualized.

Liver

The liver is subjectively normal in size, and echogenicity with smooth peripheral margins. The parenchyma is homogenous echotexture. The visible portions of the vasculature and biliary tract appear normal. No focal nodules or cystic lesions are observed.

The gallbladder lumen is moderately distended. The wall of the gall bladder is not thickened and has a smooth mucosal surface. Luminal contents are primarily anechoic. The cystic and common bile ducts are normal/not visible.

Gastrointestinal

The stomach contains minimal luminal contents. It measures at a normal thickness of <0.7cm with some variability due to the presence of rugal folds. The distinction of the gastric wall layers is adequate and there is no impression of reduced peristaltic activity. No masses or focal lesions were observed.



PATIENT

Maisie Plotkin

The visualized areas of duodenum, jejunum and ileum have a relatively uniform diameter with minimal fluid distension. Wall thickness is normal. Bowel loops follow a curvilinear path with distinct wall layering maintaining the typical 1:3 muscularis:mucosa layer ratio. Duodenum wall measured 0.48 cm. Jejunum wall measured 0.36, 0.25 cm. Visualized peristalsis appears appropriate. There were no focal lesions consistent with obstruction or a mass effect observed.

SPECIES

Canine

The ileocecal junction was visualized and exhibited normal intact wall layering and is subjectively of normal thickness (0.16 cm). Sections of colon are visualized with formed fecal material and gas shadowing distally. There is no observed focal or generalized colon wall thickening or loss of layering.

BREED

Standard Poodle

Pancreas

The pancreas is normal and isoechoic to surrounding mesentery. There is no evidence of nodules or cystic lesions. There is no evidence of regional mesenteric inflammation or fluid.

SEX

Spayed Female

Free Abdomen

Evaluation of the peritoneal cavity did not reveal any evidence of effusion, or subjective lymphadenomegaly. The Medial iliac nodes appear normal and there was no evidence of a caudal aortic thrombus at the bifurcation. The omentum is of normal uniform echogenicity.

AGE

7 Years

ULTRASONOGRAPHIC FINDINGS

- No significant lesions observed on today's exam

WEIGHT

59 Pounds

INTERPRETATION OF THE FINDINGS & FURTHER RECOMMENDATIONS

Today's scan appears relatively normal. No focal lesions were visualized associated with the gastrointestinal tract. Unfortunately, there are many causes for episodic vomiting and diarrhea, which cannot be diagnosed by ultrasound alone. This patient has been extensively evaluated for the most common causes of these issues. Furthermore, dogs with intermittent symptoms are frustrating and difficult to assess due to the episodic nature of their symptoms.

- Consider additional diet trials, as sometimes you can hit on a diet that causes a significant improvement in an individual.
- Recommend chronic probiotic therapy. If this has already been initiated with no effect, consider a different brand.
- Consider upper and lower GI endoscopy.
- In some easily stressed dogs, try to identify any triggers, particularly stress triggers that can be managed environmentally or medically.

INTERPRETED BY

Kathleen Sennello DVM,
MS, Diplomate ACVIM
(Small Animal Internal
Medicine)

IMAGING PERFORMED BY

Dr. Tam Mengine

HOSPITAL NAME

Stoney Creek VH

REFERRING VET

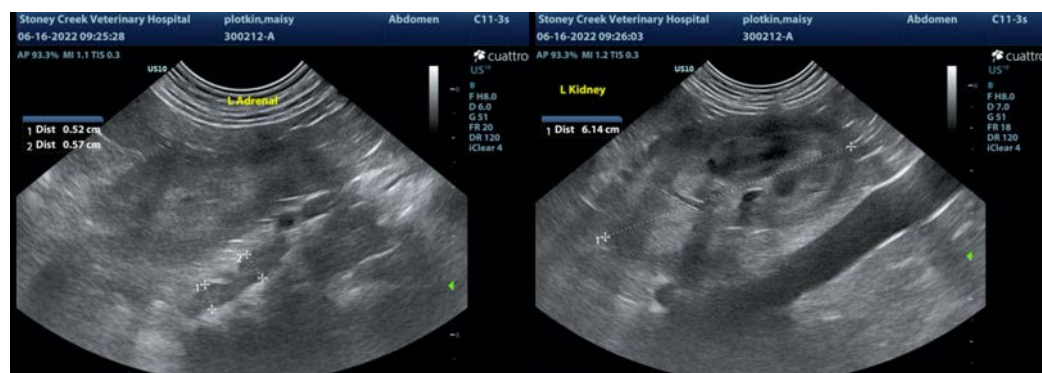
Dr. Tam Mengine

INVOICE

38769

DATE

6/16/22





PATIENT

Maisie Plotkin

SPECIES

Canine

BREED

Standard Poodle

SEX

Spayed Female

AGE

7 Years

WEIGHT

59 Pounds

INTERPRETED BY

Kathleen Sennello DVM,
MS, Diplomate ACVIM
(Small Animal Internal
Medicine)

**IMAGING
PERFORMED BY**

Dr. Tam Mengine

HOSPITAL NAME

Stoney Creek VH

REFERRING VET

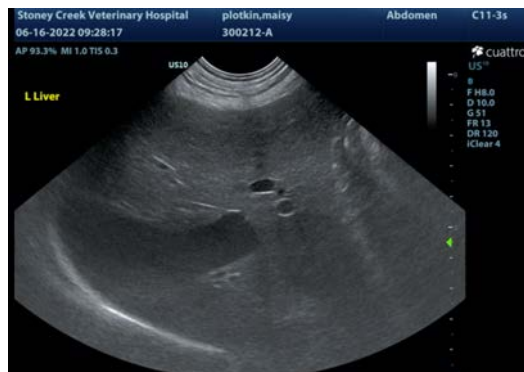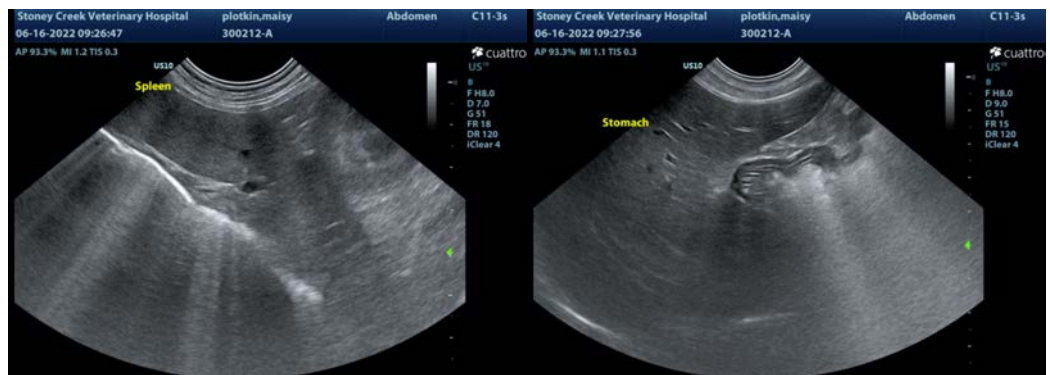
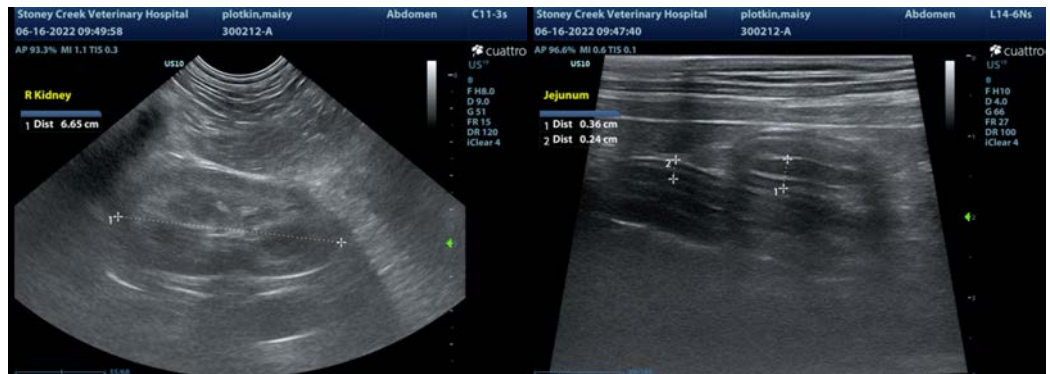
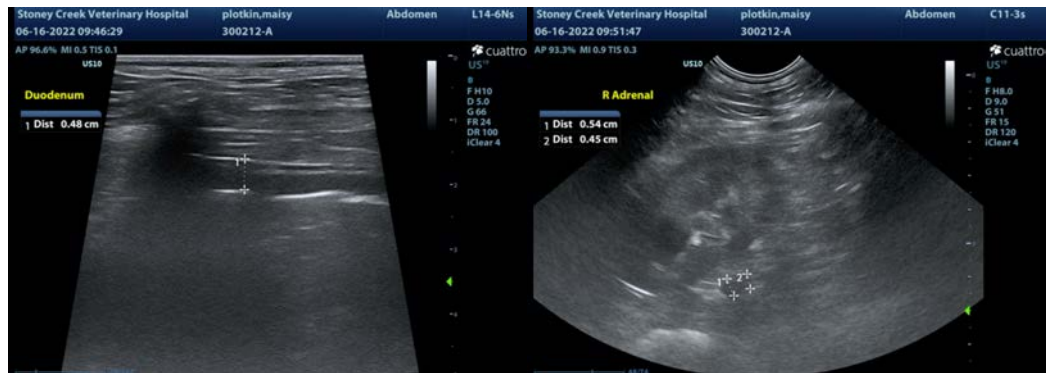
Dr. Tam Mengine

INVOICE

38769

DATE

6/16/22





PATIENT

Maisie Plotkin

The information and recommendations provided are based on the images presented by the referring veterinarian/sonographer. No evaluation can be communicated regarding pathology that was not visible in the image/video clips provided.

SPECIES

Canine

Thank you for this referral. If the clinical or image interpretation does not parallel your findings or if I can be of any further assistance please contact me.

Kathleen Sennello DVM,MS, Diplomate ACVIM (Small animal Internal Medicine)

BREED

Standard Poodle

kathleen.sennello@sonopath.com

SEX

Spayed Female

AGE

7 Years

WEIGHT

59 Pounds

INTERPRETED BY

Kathleen Sennello DVM,
MS, Diplomate ACVIM
(Small Animal Internal
Medicine)

**IMAGING
PERFORMED BY**

Dr. Tam Mengine

HOSPITAL NAME

Stoney Creek VH

REFERRING VET

Dr. Tam Mengine

INVOICE

38769

DATE

6/16/22