

PATIENT PRESENTING CLINICAL SIGNS

Chester Hoang Elevated liver values ALT 204; ALP 223.

SPECIES ULTRASONOGRAPHIC EXAMINATION OF THE ABDOMEN

Canine

Urinary System

BREED

Yorkshire Terrier

The urinary bladder is moderately distended with anechoic urine. The Bladder wall, trigone, ureteral papillae and visible urethra (to a depth of 2cm) appear normal with no evidence of wall thickening, mucosal irregularities, or masses. There is a very small shadowing, hyperechoic foci in the dependent portion of the urinary bladder, most consistent with a small stone measuring 0.20 cm.

SEX

Neutered Male

The prostate is normal in size (0.43 cm) and shape for this neutered male dog. The parenchyma is homogenous and the external margins are smooth. The prostatic urethra appears normal with no evidence of irregularity, invasion, mass effect or calculi.

AGE

11 Years

The left kidney has a normal shape and size (4.78 cm) with small, non-obstructive nephroliths, a large cyst off the cranial pole measuring 2.53 cm x 2.41 cm, and mild pyelectasia at 0.13 cm. Overall echogenicity is slightly hyperechoic with poor corticomedullary distinction and a typical 1:3 cortex:medulla ratio. There is no evidence of perinephric inflammation or effusion. There is no evidence of infarcts or hydroureter. Renal vasculature is normal.

WEIGHT

7.5 kg

The right kidney has a normal shape and size (4.58 cm) with non-obstructive nephroliths and mild pyelectasia at 0.12 cm. Overall echogenicity is slightly hyperechoic with poor corticomedullary distinction and a typical 1:3 cortex:medulla ratio. There is no evidence of perinephric inflammation or effusion. There is no evidence of infarcts or hydroureter. Renal vasculature is normal.

INTERPRETED BY

Kathleen Sennello DVM,
MS, Diplomate ACVIM
(Small Animal Internal
Medicine)

Adrenal Glands

The left adrenal gland is normal in size measuring 0.40 cm at the caudal pole. It is observed in its normal position cranial to the left renal artery. It is normal in appearance (uniformly hypoechoic) and shape with no evidence of a mass effect.

The right adrenal gland is normal in size measuring 0.45 cm at the caudal pole. It is observed in its normal position between the cranial aspect of the right kidney and the caudal vena cava. It is normal in appearance (uniformly hypoechoic) and shape with no evidence of a mass effect.

IMAGING PERFORMED BY

Pamela Harrigan, RDMS

Spleen

The spleen is subjectively normal in size, echotexture is homogenous, and the splenic capsule is smooth with no irregularities. The blood flow through the hilus and splenic parenchyma appears normal. No focal parenchymal abnormalities are visualized.

HOSPITAL NAME

Wignall AH

Liver

REFERRING VET

Dr. Victoria Harvey

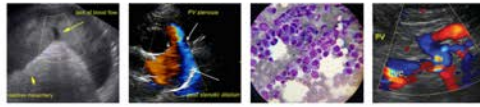
The liver is subjectively normal in size, and echogenicity with smooth peripheral margins. The parenchyma is heterogenous in echotexture with subtle, indistinct focal mottling. The visible portions of the vasculature and biliary tract appear normal. There is a large, ill-defined, isoechoic mass effect/rounded lesion associated with the liver, measuring 2.84 cm x 4.14 cm. Additionally, there are numerous ill-defined, hyperechoic nodules measuring 0.40 cm and 0.44 cm.

INVOICE

38772

DATE

6/16/22



PATIENT

Chester Hoang

The gallbladder lumen is moderately distended. The wall of the gall bladder is not thickened and has a smooth mucosal surface. Luminal contents are primarily anechoic. The cystic and common bile ducts are normal/not visible.

SPECIES

Canine

Gastrointestinal

The stomach contains minimal luminal contents. It measures at a normal thickness of <0.7cm with some variability due to the presence of rugal folds. The distinction of the gastric wall layers is adequate and there is no impression of reduced peristaltic activity. No masses or focal lesions were observed.

BREED

Yorkshire Terrier

The visualized areas of duodenum, jejunum and ileum have a relatively uniform diameter with minimal fluid distension. Wall thickness is normal. Bowel loops follow a curvilinear path with distinct wall layering maintaining the typical 1:3 muscularis:mucosa layer ratio. Duodenum wall measured 0.29 cm. Jejunum wall measured 0.31 cm. Visualized peristalsis appears appropriate. There were no focal lesions consistent with obstruction or a mass effect observed.

SEX

Neutered Male

The ileocecal junction was visualized and exhibited normal intact wall layering and is subjectively of normal thickness. Sections of colon are visualized with formed fecal material and gas shadowing distally. There is no observed focal or generalized colon wall thickening or loss of layering.

AGE

11 Years

Pancreas

The pancreas is normal and isoechoic to surrounding mesentery. There is no evidence of nodules or cystic lesions. There is no evidence of regional mesenteric inflammation or fluid.

WEIGHT

7.5 kg

Free Abdomen

Evaluation of the peritoneal cavity did not reveal any evidence of effusion, or subjective lymphadenomegaly. The Medial iliac nodes appear normal and there was no evidence of a caudal aortic thrombus at the bifurcation. The omentum is of normal uniform echogenicity.

INTERPRETED BY

Kathleen Sennello DVM,
 MS, Diplomate ACVIM
 (Small Animal Internal
 Medicine)

ULTRASONOGRAPHIC FINDINGS

- Decreased corticomedullary distinction in both kidneys with non-obstructive nephroliths and mild bilateral pyelectasia (left-sided renal cyst) – Mild loss of corticomedullary distinction in both kidneys could be consistent with chronic degenerative disease or interstitial nephrosis. The hyperechoic mineralized foci observed at the corticomedullary junction of the left/right kidney are consistent with small, non-obstructive nephroliths. Pyelectasia of the left/right kidney could be consistent with pyelonephritis, chronic renal disease, secondary to PU/PD or fluid therapy (if applicable), other.
- Heterogeneous liver with poorly defined, isoechoic solid mass effect and numerous ill-defined hyperechoic nodules – The diffuse hepatic changes are non-specific and could be consistent with vacuolar hepatopathy, nodular hyperplasia, inflammatory/immune-mediated disease, fibrosis, extramedullary hematopoiesis, toxic hepatopathy (e.g., copper), infiltrative neoplasia (less likely) or other hepatopathy. The hyperechoic nodules trend towards a benign lesion. The ill-defined hepatic mass could represent a primary adenoma, carcinoma, an atypical liver lobe, etc.
- Small stone visualized in the dependent portion of the urinary bladder – Recommend urinalysis and culture. Consider continued monitoring +/- correlation with abdominal radiographs.

IMAGING PERFORMED BY

Pamela Harrigan, RDCS

HOSPITAL NAME

Wignall AH

REFERRING VET

Dr. Victoria Harvey

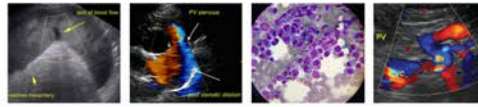
INVOICE

38772

INTERPRETATION OF THE FINDINGS & FURTHER RECOMMENDATIONS

DATE

6/16/22



PATIENT

Chester Hoang

The liver is heterogeneous, and there is an ill-defined mass effect visualized. This could represent a benign adenoma, an atypical liver lobe, or a carcinoma (other differentials exist). Options moving forward include a fine needle aspirate of this region of the liver +/- a contrast CT scan to further evaluate the extent of the lesion for possible surgical removal.

SPECIES

Canine

Consider three view thoracic radiographs to rule out concurrent thoracic disease/involvement.

BREED

Yorkshire Terrier

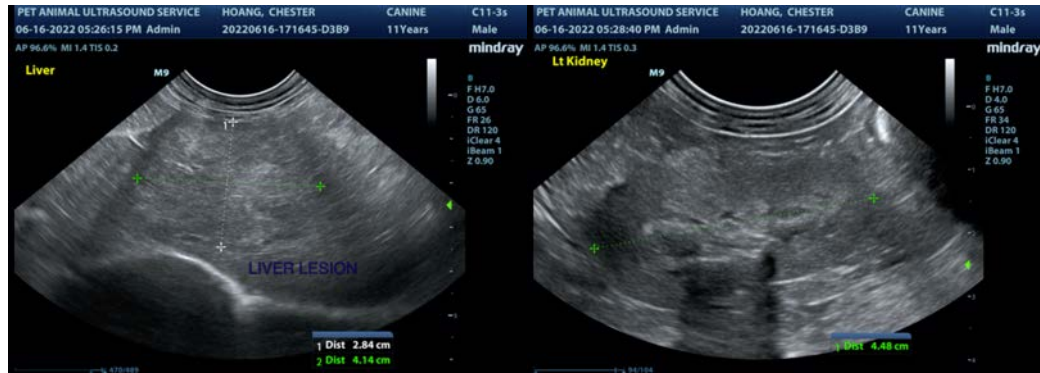
The changes observed in the kidneys are most consistent with chronic renal disease. Recommend blood pressure evaluation, urinalysis and culture, and continued monitoring of renal values.

SEX

Neutered Male

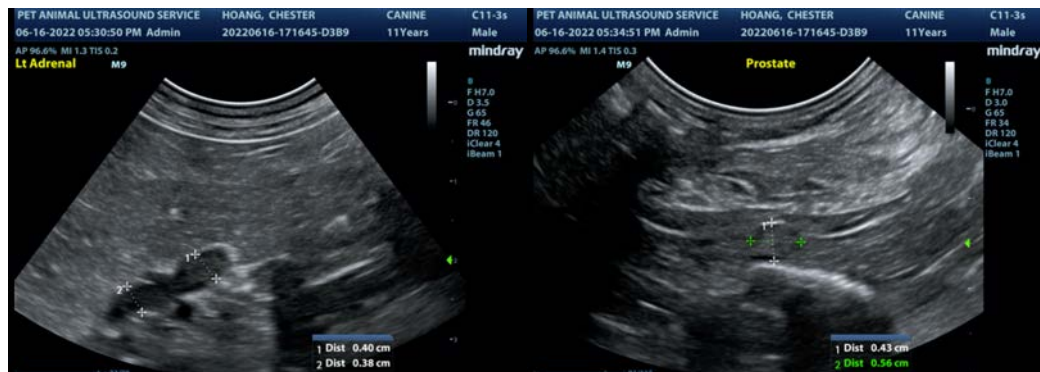
AGE

11 Years



WEIGHT

7.5 kg

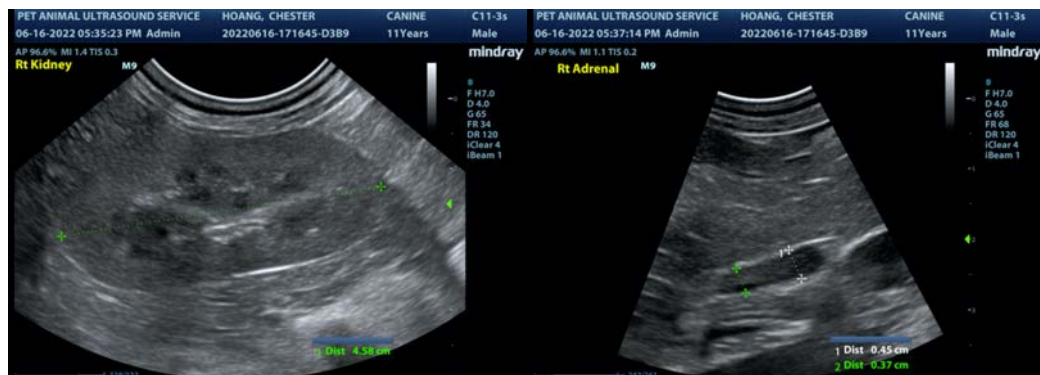

INTERPRETED BY

Kathleen Sennello DVM,
 MS, Diplomate ACVIM
 (Small Animal Internal
 Medicine)

IMAGING PERFORMED BY

Pamela Harrigan, RDCS



HOSPITAL NAME

Wignall AH

REFERRING VET

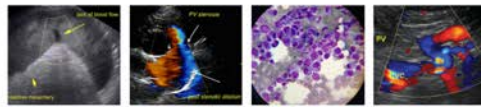
Dr. Victoria Harvey

INVOICE

38772

DATE

6/16/22



PATIENT

Chester Hoang

SPECIES

Canine

BREED

Yorkshire Terrier

SEX

Neutered Male

AGE

11 Years

WEIGHT

7.5 kg

INTERPRETED BY

Kathleen Sennello DVM,
 MS, Diplomate ACVIM
 (Small Animal Internal
 Medicine)

IMAGING PERFORMED BY

Pamela Harrigan, RDCS

HOSPITAL NAME

Wignall AH

REFERRING VET

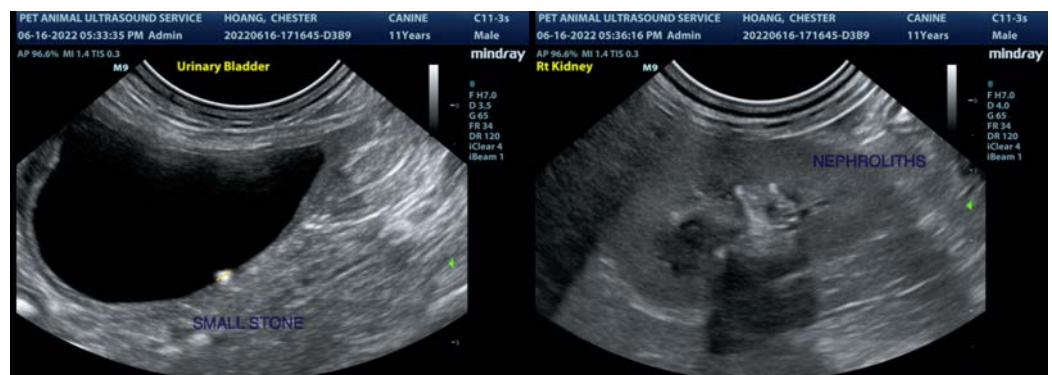
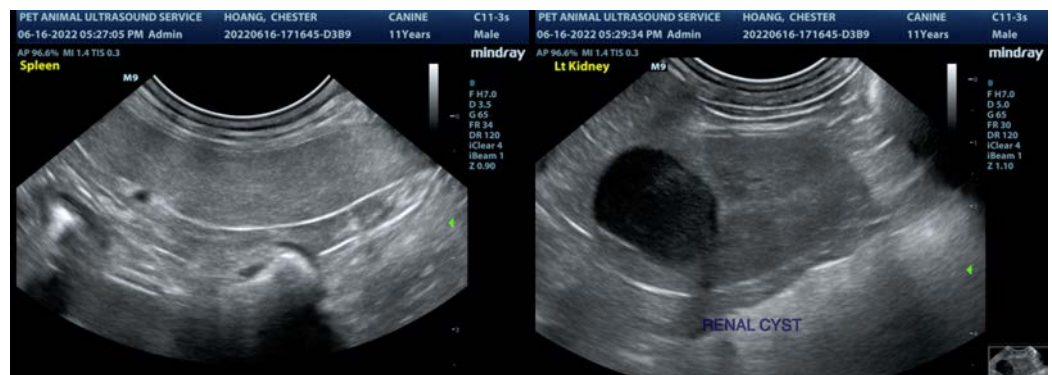
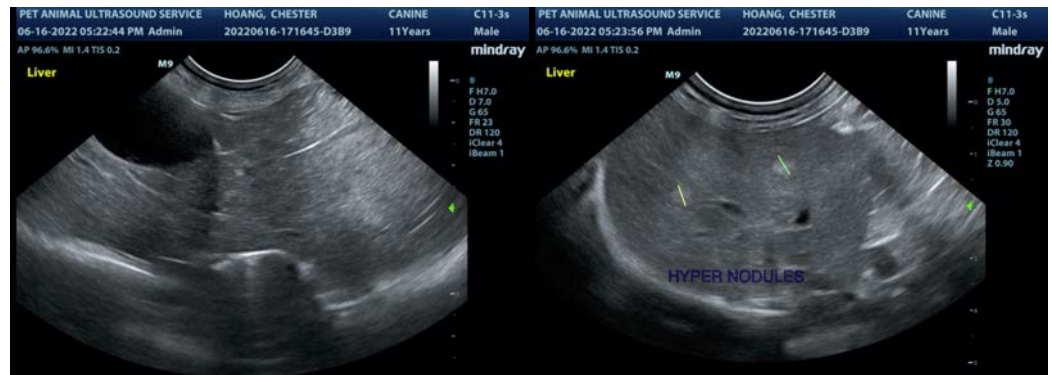
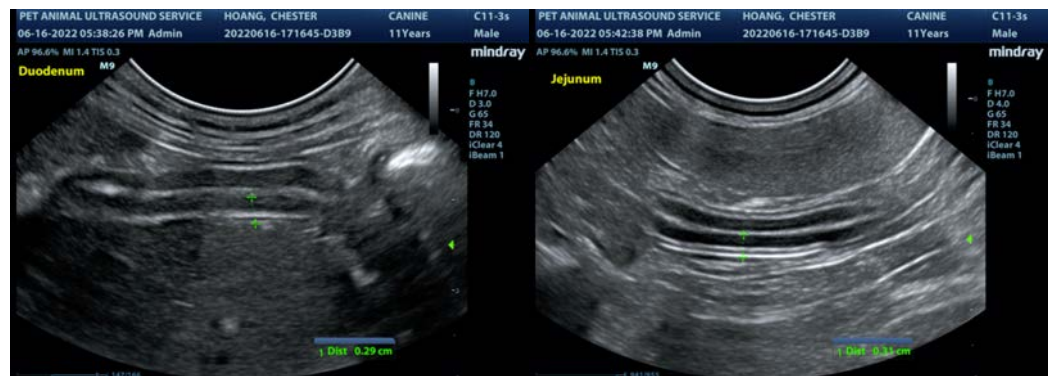
Dr. Victoria Harvey

INVOICE

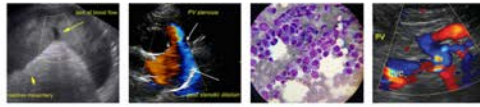
38772

DATE

6/16/22



The information and recommendations provided are based on the images presented by the referring veterinarian/sonographer. No evaluation can be communicated regarding pathology



PATIENT

that was not visible in the image/video clips provided.

Chester Hoang

Thank you for this referral. If the clinical or image interpretation does not parallel your findings or if I can be of any further assistance please contact me.

SPECIES

Kathleen Sennello DVM,MS, Diplomate ACVIM (Small animal Internal Medicine)

Canine

kathleen.sennello@sonopath.com

BREED

Yorkshire Terrier

SEX

Neutered Male

AGE

11 Years

WEIGHT

7.5 kg

INTERPRETED BY

Kathleen Sennello DVM,
MS, Diplomate ACVIM
(Small Animal Internal
Medicine)

**IMAGING
PERFORMED BY**

Pamela Harrigan, RDCS

HOSPITAL NAME

Wignall AH

REFERRING VET

Dr. Victoria Harvey

INVOICE

38772

DATE

6/16/22