

**DATE PRESENTING CLINICAL SIGNS**

6/15/22 Presented for inappetence, lethargy on 6/1/22. BW showed elevated ALP and hypothyroidism. Started EN prescription food and thyroxine. Owner concerned p still not doing well.

**PATIENT**

Penny Eck

Current Medications: L-thyroxine 0.1 BID, Metronidazole 375mg BID.

Lab Results: Attached.

Date of Previous IntraPet Ultrasound: No previous.

Sedation: Not required to complete full diagnostic ultrasound.

Stat Report: Approved.

**SPECIES**

Canine

**ULTRASONOGRAPHIC EXAMINATION OF THE ABDOMEN****BREED**

Beagle X

**Urinary System**

The urinary bladder is moderately distended with anechoic urine. The Bladder wall, trigone, ureteral papillae and visible urethra (to a depth of 2cm) appear normal with no evidence of wall thickening, mucosal irregularities, masses or cystic calculi.

**SEX**

Spayed Female

The left kidney has a normal shape and size (6.07 cm). Overall echogenicity is normal with adequate corticomedullary distinction and a typical 1:3 cortex:medulla ratio. There is no evidence of perinephric inflammation or effusion. There is no evidence of pyelectasia, nephroliths, infarcts or hydroureter. Renal vasculature is normal.

**AGE**

8/11/12

The right kidney has a normal shape and size (6.93 cm). Overall echogenicity is normal with adequate corticomedullary distinction and a typical 1:3 cortex:medulla ratio. There is no evidence of perinephric inflammation or effusion. There is no evidence of pyelectasia, nephroliths, infarcts or hydroureter. Renal vasculature is normal.

**WEIGHT**

40.9 Pounds

**INTERPRETED BY**

Kathleen Sennello DVM,  
MS, Diplomate ACVIM  
(Small Animal Internal  
Medicine)

**Adrenal Glands**

The left adrenal gland is normal in size measuring 0.64 cm at the caudal pole. It is observed in its normal position cranial to the left renal artery. It is normal in appearance (uniformly hypoechoic) and shape with no evidence of a mass effect.

The region of the right adrenal (between right cranial kidney and vena cava) is unremarkable, but the adrenal is not distinctly visualized. No evidence of a mass effect.

**IMAGING PERFORMED BY**

Stephanie Pearce  
RDMS, RVT

**Spleen**

The spleen is large in size and irregular. The blood flow through the hilus and splenic parenchyma appears normal. There is a large, irregular, expansile, slightly cystic mass effect visualized towards the caudal aspect of the spleen measuring 5.22 cm x 6.48 cm.

**HOSPITAL NAME**

Northwind AH

**Liver**

The liver is large in size and irregular. The parenchyma is heterogenous in echotexture with subtle, indistinct focal mottling. The visible portions of the vasculature and biliary tract appear normal. The hepatic parenchyma is diffusely nodular with discrete cystic masses and nodules visualized. One discrete nodule measures 5.22 cm x 6.48 cm. The largest cystic lesion is 8.7 cm x 5.9 cm. There is a large, irregular, solid mass effect towards the right side of the liver measuring 8.39 cm x 7.3 cm. There are no areas of normal hepatic tissue visualized.

**REFERRING VET**

Dr. Jones

**INVOICE**

38678

The gall bladder lumen is moderately distended. The wall of the gall bladder is not thickened and has a smooth mucosal surface. There is a moderate amount of non-organized echogenic debris. The cystic and common bile ducts are normal/not visible.

### ***Gastrointestinal***

The stomach contains minimal luminal contents. It measures at a normal thickness of <0.7cm with some variability due to the presence of rugal folds. The distinction of the gastric wall layers is adequate and there is no impression of reduced peristaltic activity. No masses or focal lesions were observed.

The visualized areas of duodenum, jejunum and ileum have a relatively uniform diameter with minimal fluid distension. Wall thickness is normal. Bowel loops follow a curvilinear path with distinct wall layering maintaining the typical 1:3 muscularis:mucosa layer ratio. The duodenum measured as normal (between 0.3-0.5cm in wall thickness) and the jejunum measured as normal (between 0.2-0.47cm.) Visualized peristalsis appears appropriate. There were no focal lesions consistent with obstruction or a mass effect observed.

The ileocecal junction was visualized and exhibited normal intact wall layering and is subjectively of normal thickness. Sections of colon are visualized with formed fecal material and gas shadowing distally. There is no observed focal or generalized colon wall thickening or loss of layering.

### ***Pancreas***

The pancreas is normal and isoechoic to surrounding mesentery. There is no evidence of nodules or cystic lesions. There is no evidence of regional mesenteric inflammation or fluid.

### ***Free Abdomen***

There is a small amount of free, mildly echogenic fluid. No lymphadenopathy is present. The omentum is of increased echogenicity.

### ***Other***

A brief view of the heart was submitted. No significant pericardial effusion was seen.

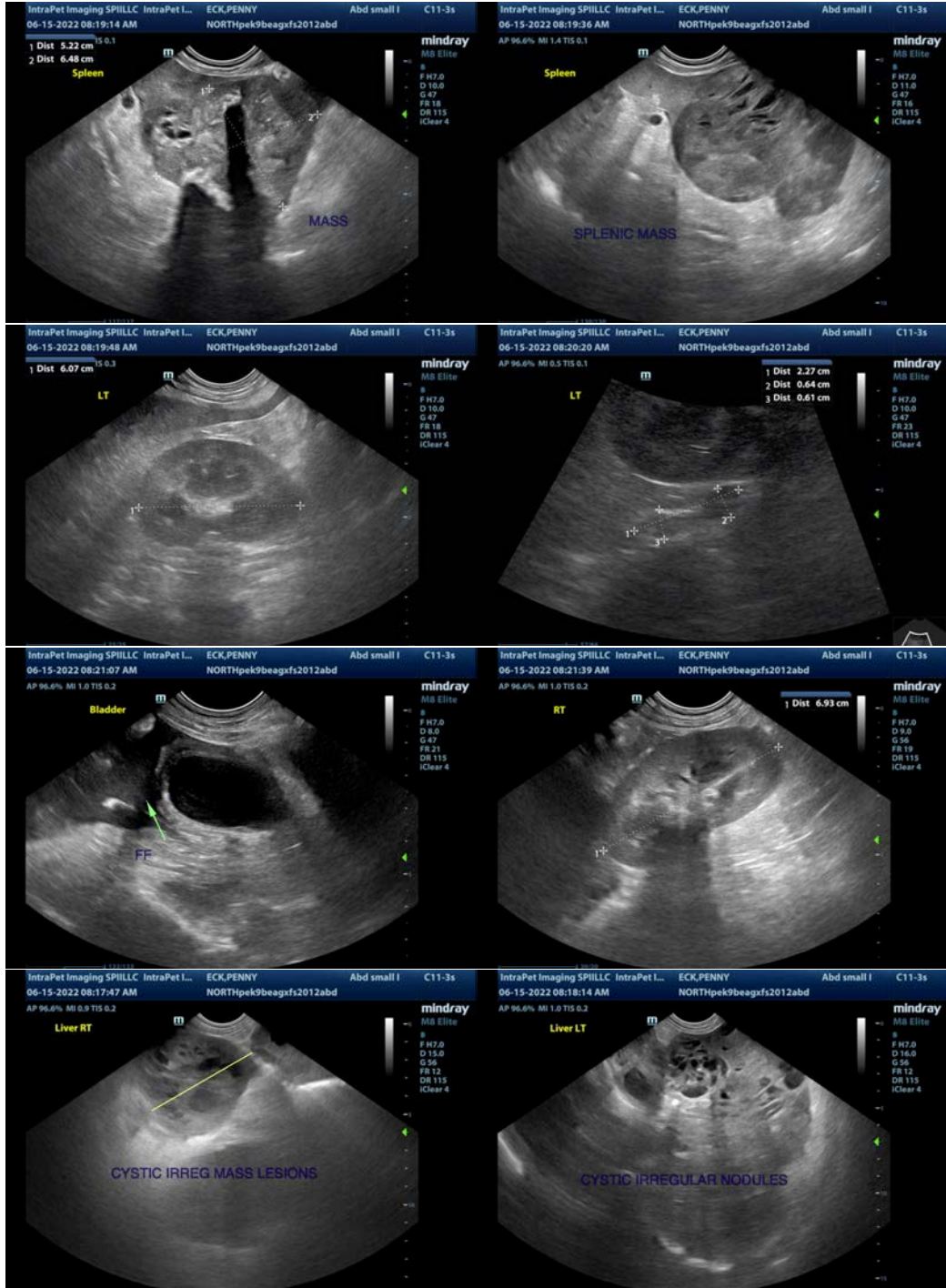
## **ULTRASONOGRAPHIC FINDINGS**

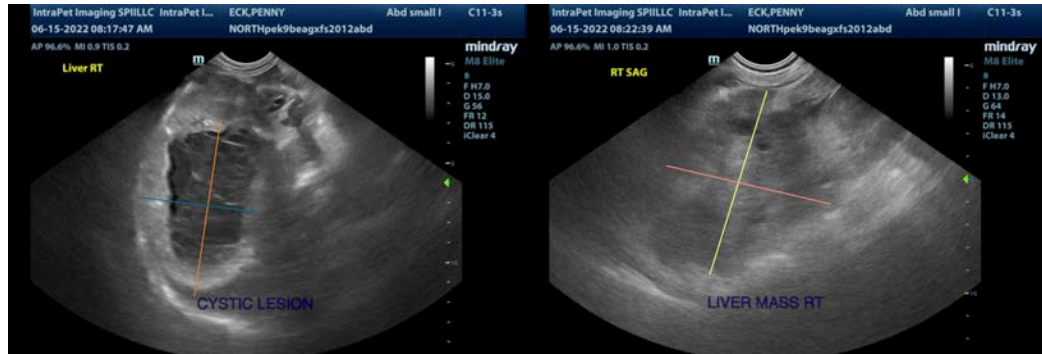
- Large, expansile, mixed echogenic, slightly cystic splenic mass – A large, solid, mixed echogenic mass is present within the splenic parenchyma. This mass distorts the splenic capsule. Differentials include benign lesions such as lymphoid hyperplasia, hemangioma, etc., or neoplastic lesions such as hemangiosarcoma, lymphoma, histiocytic sarcoma, etc.
- Diffusely nodular/cystic liver – These findings could be consistent with metastatic neoplasia, but benign processes are possible.
- Free abdominal fluid – Recommend fluid analysis and cytology.

## **INTERPRETATION OF THE FINDINGS & FURTHER RECOMMENDATIONS**

There is a large, irregular, partially cystic splenic mass lesion. This is surrounded by hyperechoic mesentery. Ideally, splenectomy would be performed for both diagnostic and therapeutic purposes.

Additionally, there is a severely nodular/cystic liver. These changes could represent metastatic disease or even benign cystic nodules. Consider a fine needle aspirate of a more solid area of the liver (right mass effect imaged?), and 3-view thoracic radiographs. Additionally, consider collecting a fluid sample for fluid analysis and cytology, as this could represent blood or general free fluid. If cytology does not indicate a metastatic process, you could consider splenectomy with liver biopsy with the knowledge that this still could be metastatic neoplasia.





**The information and recommendations provided are based on the images presented by the referring veterinarian/sonographer. No evaluation can be communicated regarding pathology that was not visible in the image/video clips provided.**

Thank you for this referral. If the clinical or image interpretation does not parallel your findings or if I can be of any further assistance please contact me.

Kathleen Sennello DVM,MS, Diplomate ACVIM (Small animal Internal Medicine)  
kathleen.sennello@sonopath.com