



**PATIENT PRESENTING CLINICAL SIGNS**

Koko Bowers Patient presents for chronic vomiting.

**SPECIES ULTRASONOGRAPHIC EXAMINATION OF THE ABDOMEN**

**Feline Urinary System**

**BREED**

DSH

**SEX**

Spayed Female

**AGE**

2 Years

**WEIGHT**

The urinary bladder is moderately distended with anechoic urine. The Bladder wall, trigone, ureteral papillae and visible urethra (to a depth of 2cm) appear normal with no evidence of wall thickening, mucosal irregularities, or masses. On one view of the urinary bladder, there is a hyperechoic, non-shadowing structure visualized along with a small hyperechoic, round focal object measuring 0.20 cm. This could be a mineralized structure, but with minimal shadowing. It could also represent hyperechoic intraluminal debris. The pinpoint rounded structure is more concerning for a possible small calculus. Correlate with abdominal radiographs, urinalysis and culture results.

The left kidney has a normal shape and size (3.11 cm). Overall echogenicity is normal with adequate corticomedullary distinction and a typical 1:3 cortex:medulla ratio. There is no evidence of perinephric inflammation or effusion. There is no evidence of pyelectasia, nephroliths, infarcts or hydroureter. Renal vasculature is normal.

The right kidney has a normal shape and size (3.22 cm). Overall echogenicity is normal with adequate corticomedullary distinction and a typical 1:3 cortex:medulla ratio. There is no evidence of perinephric inflammation or effusion. There is no evidence of pyelectasia, nephroliths, infarcts or hydroureter. Renal vasculature is normal.

**Adrenal Glands**

The region of left adrenal (Cranial to left renal artery) is unremarkable but the adrenal is not distinctly visualized. No evidence of a mass effect.

The region of the right adrenal (between right cranial kidney and vena cava) is unremarkable, but the adrenal is not distinctly visualized. No evidence of a mass effect.

**Spleen**

The spleen is subjectively normal in size (0.62 cm at the level of the hilus), echotexture is homogenous, and the splenic capsule is smooth with no irregularities. The blood flow through the hilus and splenic parenchyma appears normal. No focal parenchymal abnormalities are visualized.

**Liver**

The liver is subjectively normal in size, and echogenicity with smooth peripheral margins. The parenchyma is homogenous echotexture. The visible portions of the vasculature and biliary tract appear normal. No focal nodules or cystic lesions are observed.

The gallbladder lumen is moderately distended. The wall of the gall bladder is not thickened and has a smooth mucosal surface. Luminal contents are primarily anechoic. The bile duct appears somewhat tortuous and dilated, measuring at 0.25 cm.

**Gastrointestinal**

The stomach contains minimal luminal contents. It measures at a normal thickness of <0.36cm with some variability due to the presence of rugal folds. The distinction of the gastric wall layers is adequate and there is no impression of reduced peristaltic activity. No masses or focal lesions were observed.

**INTERPRETED BY**

Kathleen Sennello DVM,  
MS, Diplomate ACVIM  
(Small Animal Internal  
Medicine)

**IMAGING PERFORMED BY**

Kelly Vazquez

**HOSPITAL NAME**

New Bridge VP

**REFERRING VET**

Dr. Abina Glennon

**INVOICE**

38753

**DATE**

6/15/22



**PATIENT**

Koko Bowers

The visualized areas of duodenum, jejunum and ileum have a relatively uniform diameter with minimal fluid distension. Wall thickness is normal. Bowel loops follow a curvilinear path with distinct wall layering maintaining the typical 1:3 muscularis:mucosa layer ratio. Jejunum wall measured 0.21 cm. Visualized peristalsis appears appropriate. There were no focal lesions consistent with obstruction or a mass effect observed.

**SPECIES**

Feline

The ileocecal junction was visualized and exhibited normal intact wall layering and is subjectively of normal thickness. Sections of colon are visualized with formed fecal material and gas shadowing distally. There is no observed focal or generalized colon wall thickening or loss of layering.

**BREED**

DSH

***Pancreas***

The pancreas is normal and isoechoic to surrounding mesentery. There is no evidence of nodules or cystic lesions. There is no evidence of regional mesenteric inflammation or fluid.

**SEX**

Spayed Female

***Free Abdomen***

Evaluation of the peritoneal cavity did not reveal any evidence of effusion, or subjective lymphadenomegaly. The Medial iliac nodes appear normal and there was no evidence of a caudal aortic thrombus at the bifurcation. The omentum is of normal uniform echogenicity.

**AGE**

2 Years

**ULTRASONOGRAPHIC FINDINGS**

**WEIGHT**

- Hyperechoic material visualized within the urinary bladder – The significance of this material is uncertain, as it does not appear to have a significant shadow, indicating mineralization. Correlate with abdominal radiographs, urinalysis and culture results.
- Mildly dilated/tortuous common bile duct – These changes are mild, and there is no obvious evidence of an obstruction. Correlate with bloodwork findings.

**INTERPRETED BY**

Kathleen Sennello DVM,  
MS, Diplomate ACVIM  
(Small Animal Internal  
Medicine)

**INTERPRETATION OF THE FINDINGS & FURTHER RECOMMENDATIONS**

Today's scan appears relatively normal. No obvious lesions are visualized associated with the gastrointestinal tract to explain the chronic vomiting reported. Correlate these findings with abdominal radiographs, looking for an obstructive pattern, and to further evaluate the hyperechoic material visualized within the urinary bladder. If this cannot be seen on radiographs, and urinalysis appears normal, then consider reevaluation with ultrasound in 1-2 months.

**IMAGING PERFORMED BY**

Kelly Vazquez

There are many causes for vomiting that cannot be diagnosed by ultrasound alone. If bloodwork results do not indicate a likely metabolic problem, then consider primary gastrointestinal causes such as food allergy/dietary intolerance, GI parasitism, pancreatitis, dysbiosis, IBD (less likely in this young of a cat), and less likely GI neoplasia.

**HOSPITAL NAME**

New Bridge VP

- Consider a novel protein/hydrolyzed protein prescription diet.
- Consider a GI panel to Texas A&M for a qualitative fPLI, TLI, cobalamin and folate to further evaluate the pancreas and small intestine.

**REFERRING VET**

Dr. Abina Glennon

- Recommend screening for GI parasites and empirical treatment (if not already done).

**INVOICE**

38753

- Consider chronic probiotic therapy.

- If symptoms persist despite these measures, consider obtaining GI biopsies.

**DATE**

6/15/22



**PATIENT**

Koko Bowers

**SPECIES**

Feline

**BREED**

DSH

**SEX**

Spayed Female

**AGE**

2 Years

**WEIGHT**

**INTERPRETED BY**

Kathleen Sennello DVM,  
MS, Diplomate ACVIM  
(Small Animal Internal  
Medicine)

**IMAGING  
PERFORMED BY**

Kelly Vazquez

**HOSPITAL NAME**

New Bridge VP

**REFERRING VET**

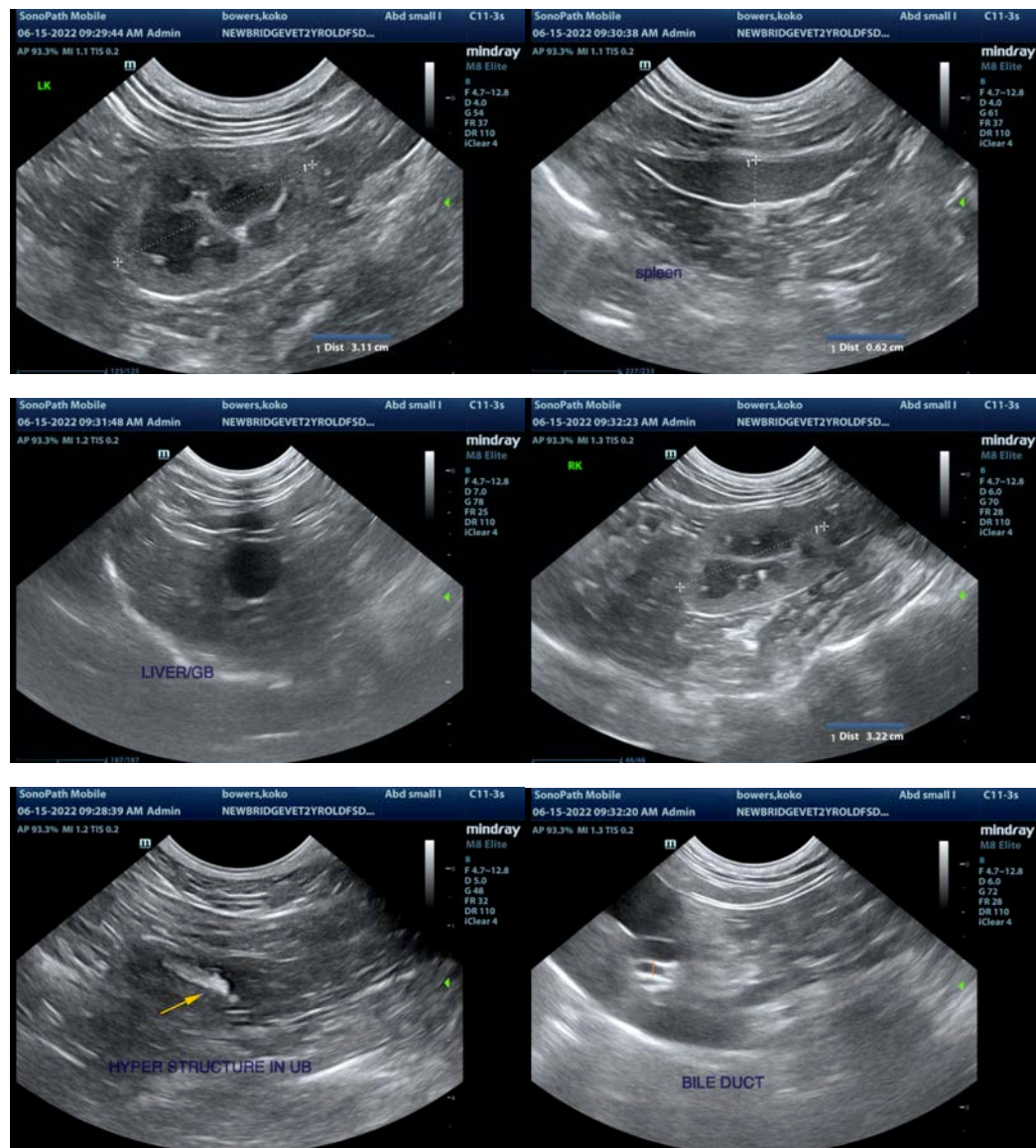
Dr. Abina Glennon

**INVOICE**

38753

**DATE**

6/15/22



The information and recommendations provided are based on the images presented by the referring veterinarian/sonographer. No evaluation can be communicated regarding pathology that was not visible in the image/video clips provided.

Thank you for this referral. If the clinical or image interpretation does not parallel your findings or if I can be of any further assistance please contact me.

Kathleen Sennello DVM,MS, Diplomate ACVIM (Small animal Internal Medicine)

kathleen.sennello@sonopath.com