

**DATE PRESENTING CLINICAL SIGNS**

6/14/23

Presented for increased panting and labored breathing at the end of May. Today presented for continued increased respiratory rate, lethargy, and inappetance. BP 150, no murmur ausculted, normal lung sounds, tachycardic 160bpm, tachypneic 60-80breaths/min, painful on abdominal palpation. Radiographs revealed a mass effect in the caudal abdomen, large kidneys, elevated renal values.

PATIENT

Chino Doci

SPECIES

Canine

BREED

Labrador Retriever X

SEX

Intact Male

AGE

5/31/11

WEIGHT

80 Pounds

INTERPRETED BY

Kathleen Sennello DVM,
MS, Diplomate ACVIM
(Small Animal Internal
Medicine)

HOSPITAL NAME

Perry Hall AH

REFERRING VET

Dr. Breidenbaugh

INVOICE

43103

Current Medications: On IV fluids at twice maintenance, Fentanyl 0.003mg/kg every 1-2hrs (while in hospital), Cerenia 1mg/kg IV, Entyce 3mg/kg PO, Unasyn 22mg/kg IV
Lab Results: CBC: reticulocytosis (114.6), with low retic Hgb (21.9), leukocytosis (22.26k) with neutrophilia (16.03k), thrombocytopenia (7, some clumping seen), with increased MPV (18.9), and low plateletcrit (0.01); CHEM: azotemia: sdma 34, creatinine 4.3, BUN 97, phosphorus 11.7, IRIS stage 4, elevated ALP (404), SNAP cPL: normal
Radiographs: Equivocally improved, diffuse mixed bronchial and unstructured interstitial pulmonary pattern. Caudal abdominal mass effect. Mild bilateral renomegaly.
Date of Previous IntraPet Ultrasound: No previous.
Sedation: Not required to complete full diagnostic ultrasound.
Stat Report: Requested by DVM.
Imaging Performed By: Andi Parkinson, RDMS.

ULTRASONOGRAPHIC EXAMINATION OF THE ABDOMEN**Urinary System**

The urinary bladder is minimally distended with urine. No focal abnormalities are visualized but evaluation of the urinary bladder is greatly hindered by lack of urine distention. No calculi are observed. The ureters are prominent/dilated and visualized entering the urinary bladder.

The prostate is large in size (7.19 cm x 5.04 cm), irregular and cystic. The parenchyma is heterogenous, but no discrete focal lesions are present. There are large, irregular anechoic cysts visualized, examples of which measure 2.0 cm x 3.0 cm and 0.69 cm x 1.8 cm. The prostatic urethra appears normal with no evidence of irregularity, invasion, mass effect or calculi.

The left kidney is borderline large at 7.97 cm with decreased corticomedullary distinction, and early hydronephrosis with the renal pelvis measuring 1.7 cm. A hydroureter was visualized extending all the way to the urinary bladder. The ureter measures 0.75 cm in the mid abdomen. No evidence of calculi or focal obstruction visualized.

The right kidney is borderline large at 8.58 cm with decreased corticomedullary distinction and significant pyelectasia at 0.80 cm, as well as hydroureter. The proximal ureter measures 0.95 cm and measures 0.76 cm more distally. The ureter is dilated all the way to the urinary bladder.

Adrenal Glands

The region of left adrenal (Cranial to left renal artery) is unremarkable but the adrenal is not distinctly visualized. No evidence of a mass effect is visualized.

The right adrenal gland is normal in size measuring 0.98 cm at the caudal pole. It is observed in its normal position between the cranial aspect of the right kidney and the caudal vena cava. It is normal in appearance (uniformly hypoechoic) and shape with no evidence of a mass effect.

Spleen

The spleen is subjectively normal in size, echotexture is homogenous, and the splenic capsule is smooth with no irregularities. The blood flow through the hilus and splenic parenchyma appears normal. No focal parenchymal abnormalities are visualized.

Liver

The liver is subjectively normal in size, and echogenicity with smooth peripheral margins. The parenchyma is homogenous echotexture. The visible portions of the vasculature and biliary tract appear normal. No focal nodules or cystic lesions are observed.

The gallbladder lumen is moderately distended. The wall of the gall bladder is not thickened and has a smooth mucosal surface. Luminal contents are mild and primarily anechoic. The cystic and common bile ducts are normal/not visible.

Gastrointestinal

The stomach contains minimal luminal contents. It measures at a normal thickness of <0.7cm with some variability due to the presence of rugal folds. The distinction of the gastric wall layers is adequate and there is no impression of reduced peristaltic activity. No masses or focal lesions were observed.

The visualized areas of duodenum, jejunum and ileum have a relatively uniform diameter with minimal fluid distension. Wall thickness is normal. Bowel loops follow a curvilinear path with distinct wall layering maintaining the typical 1:3 muscularis:mucosa layer ratio. The duodenum measured as normal (between 0.3-0.5cm in wall thickness) and the jejunum measured as normal (between 0.2-0.47cm.) Visualized peristalsis appears appropriate. There were no focal lesions consistent with obstruction or a mass effect observed.

The ileocecal junction was visualized and exhibited normal intact wall layering and is subjectively of normal thickness. Sections of colon are visualized with formed fecal material and gas shadowing distally. There is no observed focal or generalized colon wall thickening or loss of layering.

Pancreas

The area of the pancreas is normal and isoechoic to surrounding mesentery. There is no evidence of nodules or cystic lesions. There is no evidence of regional mesenteric inflammation or fluid.

Free Abdomen

Evaluation of the peritoneal cavity did not reveal any evidence of effusion. The sublumbar lymph nodes are moderately enlarged and hypoechoic, measuring 1.35 cm x 3.04 cm and 1.62 cm x 3.17 cm. The omentum is hyperechoic in the region of the kidneys and urinary bladder.

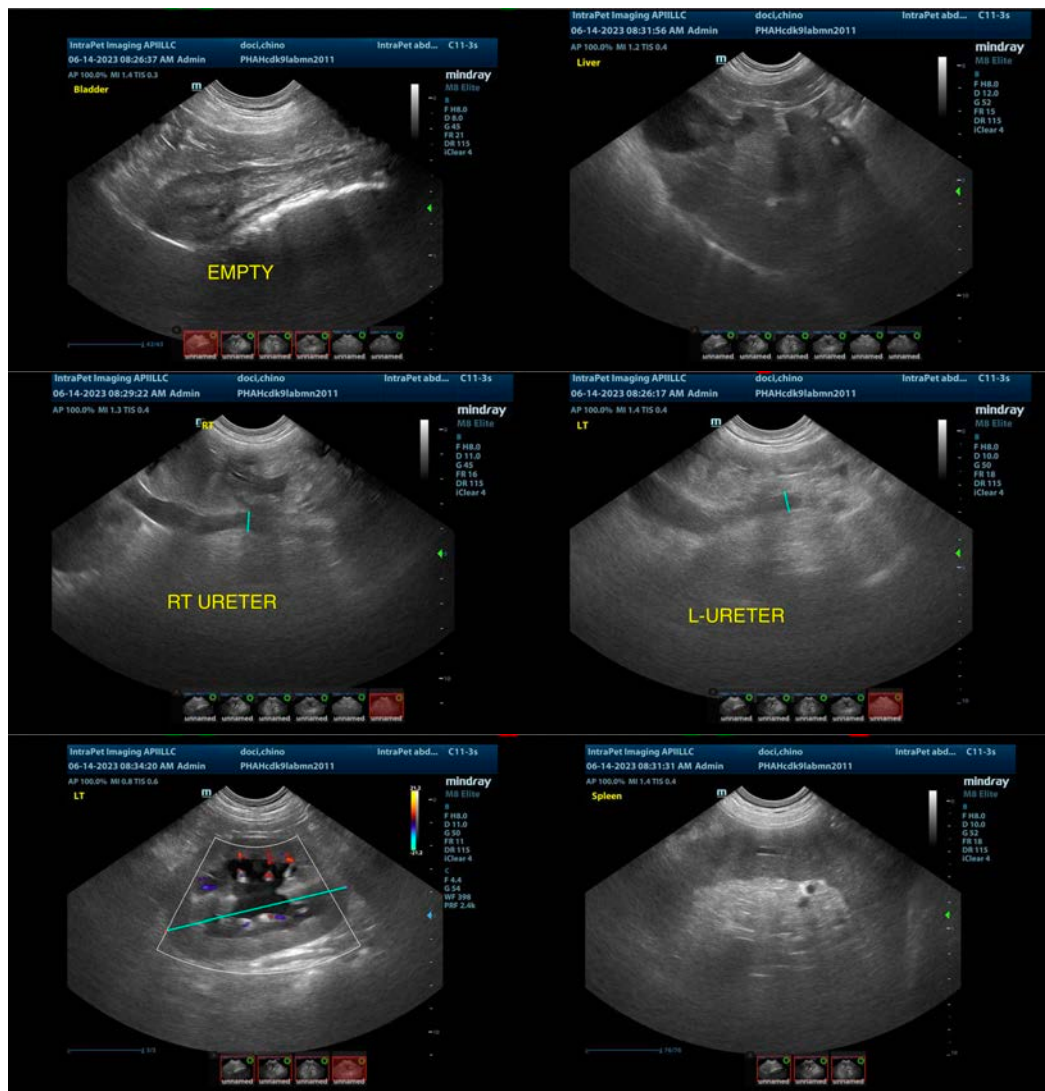
ULTRASONOGRAPHIC FINDINGS

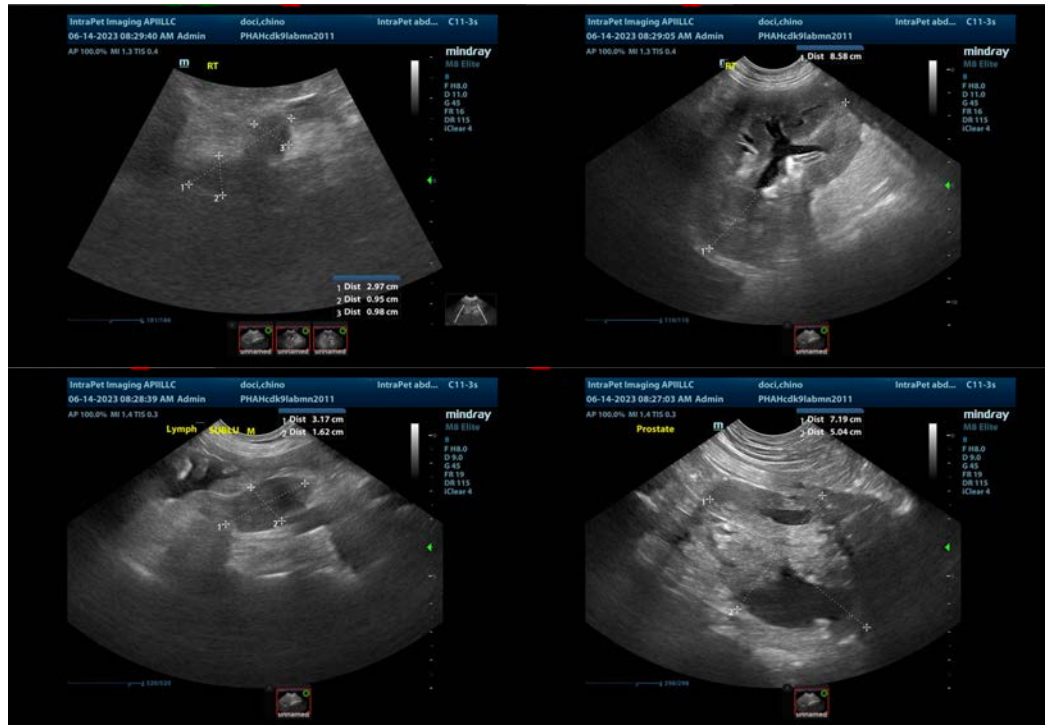
- Decreased corticomedullary distinction in both kidneys with hydronephrosis/severe pyelectasia and bilateral hydroureter. No evidence of an obstructive process is clearly visualized. Differentials would include severe pyelonephritis or an obstructive process at the level of the urinary bladder/trigone.
- Large, hyperechoic, heterogeneous, irregular prostate with numerous large anechoic cysts – Findings are most consistent with benign prostatic hypertrophy +/- prostatitis and prostatic cysts – Recommend a urinalysis and culture.
- Mildly/moderately enlarged sublumbar lymph nodes – The appearance is most consistent with reactive lymph nodes, but an early neoplastic change cannot be ruled out.

INTERPRETATION OF THE FINDINGS & FURTHER RECOMMENDATIONS

There is significant dilation of both renal pelvises and ureters, suggestive of a possible obstructive process, although a clear obstruction is not visualized. Evaluation of the urinary bladder and urethra would be greatly enhanced by more urine distention. The most likely differential would be severe pyelonephritis and/or obstruction due to abnormal tissue at the level of the ureteral papilla. It would be unusual to have a ureteral

obstruction due to benign prostatic hypertrophy alone. Recommend urinalysis and culture. You could consider percutaneous drainage of some of the large cystic regions of the prostate for possible culture/cytologic evaluation. Additionally consider evaluation of the urinary bladder and urethra with more urine distention, looking for evidence of a subtle mass effect in the region or invasion into the urethra. In this situation I might consider a fine needle aspirate of the prostate, although neoplasia is typically an unlikely differential in an intact male dog. With subsequent issues, this could be a consideration. Additionally consider catheterization and diuresis as well as broad-spectrum IV antibiotics to see if the renal values improve. This will help to determine how much of the azotemia is secondary to an obstructive process versus acute renal failure. I suspect there may be a component of both present. Additionally, you could consider screening for Leptospirosis if exposure is thought likely.





The information and recommendations provided are based on the images presented by the referring veterinarian/sonographer. No evaluation can be communicated regarding pathology that was not visible in the image/video clips provided.

Thank you for this referral. If the clinical or image interpretation does not parallel your findings or if I can be of any further assistance please contact me.

Kathleen Sennello DVM,MS, Diplomate ACVIM (Small animal Internal Medicine)
info@sonopath.com