

**PATIENT**

River Newell

**SPECIES**

Feline

**BREED**

DSH

**SEX**

Neutered Male

**AGE**

1 Year

**WEIGHT**

6.5 Pounds

**INTERPRETED BY**Kathleen Sennello DVM,  
MS, Diplomate ACVIM  
(Small Animal Internal  
Medicine)**IMAGING  
PERFORMED BY**

Amy Mayhew, LVT

**HOSPITAL NAME**

SVS Imaging MI

**REFERRING VET**

Pinecrest AH

**INVOICE**

38671

**DATE**

6/14/22

**PRESENTING CLINICAL SIGNS**

Lethargic, seen at ER 6/12/22. Not vomiting. Painful in cranial abdomen.  
 Abnormal PE/Chem/CBC/UA Results: Painful in cranial abdomen. Full BW pending.

**ULTRASONOGRAPHIC EXAMINATION OF THE ABDOMEN****Urinary System**

The urinary bladder is moderately distended with anechoic urine. The Bladder wall, trigone, ureteral papillae and visible urethra (to a depth of 2cm) appear normal with no evidence of wall thickening, mucosal irregularities, masses or cystic calculi.

The left kidney has a normal shape and size (3.68 cm). Overall echogenicity is normal with adequate corticomedullary distinction and a typical 1:3 cortex:medulla ratio. There is no evidence of perinephric inflammation or effusion. There is no evidence of pyelectasia, nephroliths, infarcts or hydroureter. Renal vasculature is normal.

The right kidney has a normal shape and size (3.84 cm). Overall echogenicity is normal with adequate corticomedullary distinction and a typical 1:3 cortex:medulla ratio. There is no evidence of perinephric inflammation or effusion. There is no evidence of pyelectasia, nephroliths, infarcts or hydroureter. Renal vasculature is normal.

**Adrenal Glands**

The left adrenal gland is normal in size measuring 0.27 cm at the caudal pole. It is observed in its normal position cranial to the left renal artery. It is normal in appearance (uniformly hypoechoic) and shape with no evidence of a mass effect.

The right adrenal gland is normal in size measuring 0.30 cm at the caudal pole. It is observed in its normal position between the cranial aspect of the right kidney and the caudal vena cava. It is normal in appearance (uniformly hypoechoic) and shape with no evidence of a mass effect.

**Spleen**

The spleen is subjectively normal in size, echotexture is homogenous, and the splenic capsule is smooth with no irregularities. The blood flow through the hilus and splenic parenchyma appears normal. No focal parenchymal abnormalities are visualized.

**Liver**

The liver is subjectively normal in size, and echogenicity with smooth peripheral margins. The parenchyma is homogenous echotexture. The visible portions of the vasculature and biliary tract appear normal. No focal nodules or cystic lesions are observed.

The gallbladder lumen is moderately distended. The wall of the gall bladder is not thickened and has a smooth mucosal surface. Luminal contents are primarily anechoic. The proximal cystic duct appears prominent and somewhat dilated at 0.38 cm. It does not appear significantly dilated more distally.

**Gastrointestinal**

The stomach contains minimal luminal contents. It measures at a normal thickness of <0.36cm with some variability due to the presence of rugal folds. The distinction of the gastric wall layers is adequate and there is no impression of reduced peristaltic activity. No masses or focal lesions were observed.

The visualized areas of duodenum, jejunum and ileum have a relatively uniform diameter with minimal fluid distension. Wall thickness is normal. Bowel loops follow a curvilinear path with distinct wall

**IMAGING PERFORMED BY**SVS Mobile Imaging MI 734-637-7711  
svsimagingmi@gmail.comEDUCATIONAL TELECONSULTATION SERVICES™  
1-800-838-4268 info@sonopath.com SonoPath.com**PATIENT**

River Newell

layering maintaining the typical 1:3 muscularis:mucosa layer ratio. Duodenum wall measured 0.19 cm. Jejunum wall measured 0.16 cm. Visualized peristalsis appears appropriate. There were no focal lesions consistent with obstruction or a mass effect observed.

**SPECIES**

Feline

The ileocecal junction was visualized and exhibited normal intact wall layering and is subjectively of normal thickness. Sections of colon are visualized with formed fecal material and gas shadowing distally. There is no observed focal or generalized colon wall thickening or loss of layering.

**Pancreas****BREED**

DSH

The pancreas is large and hypoechoic to surrounding mesentery, particularly the left limb. There is no evidence of nodules or cystic lesions. There is evidence of regional mesenteric inflammation. Consistent with mild to moderate pancreatitis.

**SEX**

Neutered Male

**Free Abdomen**

Evaluation of the peritoneal cavity did not reveal any evidence of effusion, or subjective lymphadenomegaly. The Medial iliac nodes appear normal and there was no evidence of a caudal aortic thrombus at the bifurcation. The omentum is of normal uniform echogenicity.

**AGE**

1 Year

**PRIMARY FINDINGS**

- Hypoechoic, prominent left limb of the pancreas with surrounding hyperechoic mesentery – The pancreatic changes are most consistent with mild to moderate pancreatitis/pancreatic inflammation. Recommend fPLI testing and continued monitoring for improvement or possible development of a pancreatic abscess. Consider fine needle aspirate if not improving.

**WEIGHT**

6.5 Pounds

**SECONDARY FINDINGS**

- Prominent/mildly dilated proximal cystic duct – The significance of this is unclear, as more distal dilation is not observed. Correlate with bloodwork findings.

**INTERPRETED BY**Kathleen Sennello DVM,  
MS, Diplomate ACVIM  
(Small Animal Internal  
Medicine)**INTERPRETATION OF THE FINDINGS & FURTHER RECOMMENDATIONS**

The left limb of the pancreas, particularly caudal to the stomach appears hypoechoic with surrounding hyperechoic mesentery. These changes are most consistent with mild to moderate pancreatic inflammation/pancreatitis. There is no evidence of a diffuse obstructive pattern visualized. There is very mild fluid dilation of the duodenum, and no obvious foreign material or mass lesions observed, although unfortunately sometimes foreign material can be difficult to visualize with ultrasound alone. Correlate these findings with abdominal radiographs. If symptoms persist despite treatment for pancreatitis, serial imaging or further evaluation for gastrointestinal foreign material would need to be considered.

**IMAGING PERFORMED BY**

Amy Mayhew, LVT

**HOSPITAL NAME**

SVS Imaging MI

**REFERRING VET**

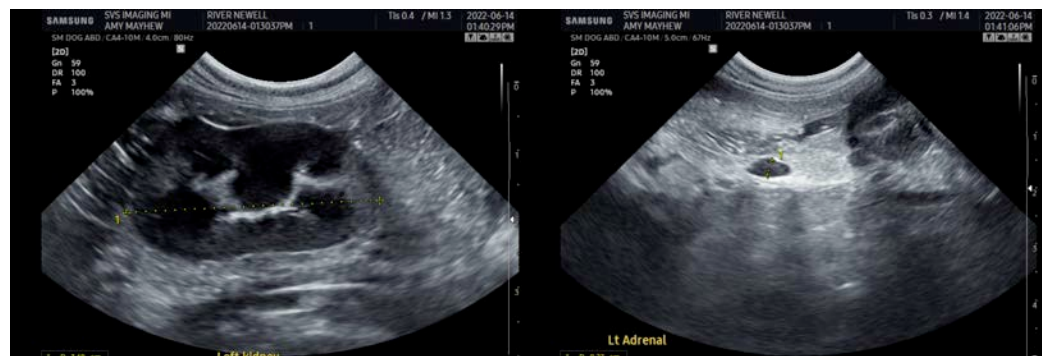
Pinecrest AH

**INVOICE**

38671

**DATE**

6/14/22



**IMAGING PERFORMED BY**

SVS Mobile Imaging MI 734-637-7711  
svsimagingmi@gmail.com



**PATIENT**

River Newell

**SPECIES**

Feline

**BREED**

DSH

**SEX**

Neutered Male

**AGE**

1 Year

**WEIGHT**

6.5 Pounds

**INTERPRETED BY**

Kathleen Sennello DVM,  
MS, Diplomate ACVIM  
(Small Animal Internal  
Medicine)

**IMAGING  
PERFORMED BY**

Amy Mayhew, LVT

**HOSPITAL NAME**

SVS Imaging MI

**REFERRING VET**

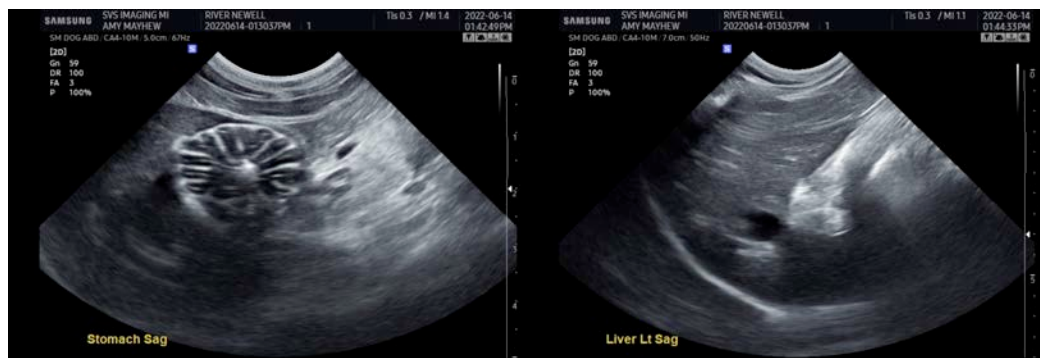
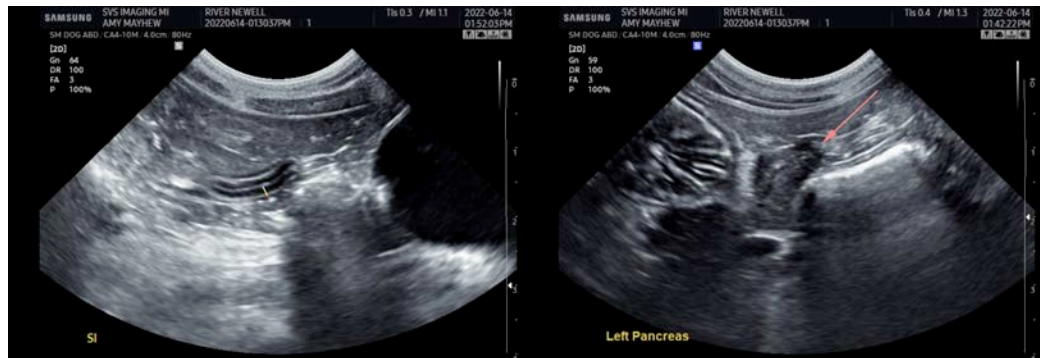
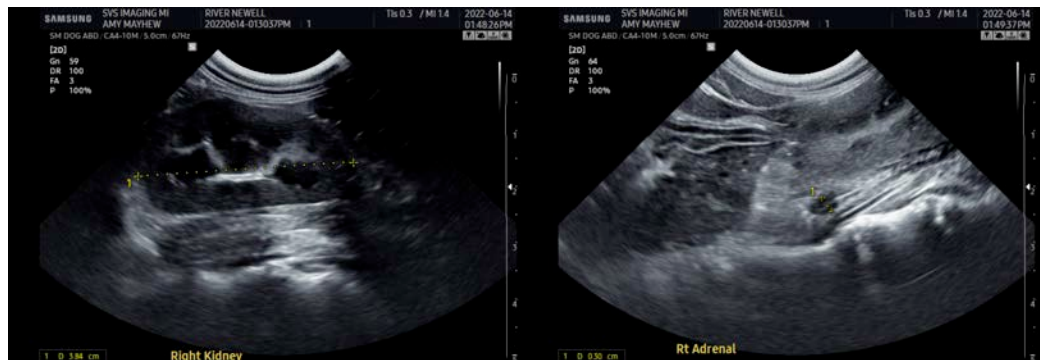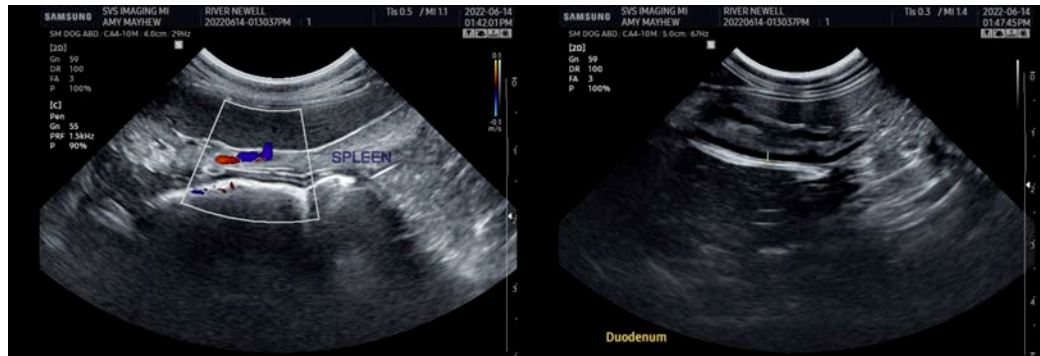Pinecrest AH

**INVOICE**

38671

**DATE**

6/14/22



**IMAGING PERFORMED BY**

SVS Mobile Imaging MI 734 - 637 - 7711  
svsimagingmi@gmail.com



EDUCATIONAL TELECONSULTATION SERVICES™  
1-800-838-4268 info@sonopath.com SonoPath.com

**PATIENT**

River Newell

**SPECIES**

Feline

**BREED**

DSH

**SEX**

Neutered Male

**AGE**

1 Year

**WEIGHT**

6.5 Pounds

**INTERPRETED BY**

Kathleen Sennello DVM,  
MS, Diplomate ACVIM  
(Small Animal Internal  
Medicine)

**IMAGING  
PERFORMED BY**

Amy Mayhew, LVT

**HOSPITAL NAME**

SVS Imaging MI

**REFERRING VET**

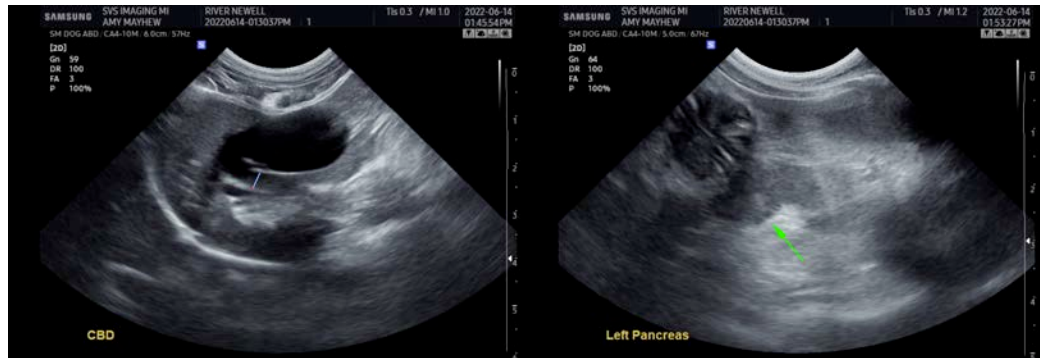
Pinecrest AH

**INVOICE**

38671

**DATE**

6/14/22



The information and recommendations provided are based on the images presented by the referring veterinarian/sonographer. No evaluation can be communicated regarding pathology that was not visible in the image/video clips provided.

Thank you for this referral. If the clinical or image interpretation does not parallel your findings or if I can be of any further assistance please contact me.

Kathleen Sennello DVM,MS, Diplomate ACVIM (Small animal Internal Medicine)  
kathleen.sennello@sonopath.com