

IMAGING PERFORMED BY

IntraPet.com



SonoPath

Clinical Sonography & Telecytology

EDUCATIONAL TELECONSULTATION SERVICES™

1-800-838-4268 info@sonopath.com SonoPath.com

DATE PRESENTING CLINICAL SIGNS

6/14/22 Urinary issues.

PATIENT Current Medications: None listed.

Lunny Cairn Rescue

Date of Previous IntraPet Ultrasound: No previous.

Sedation: Not required to complete full diagnostic ultrasound.

Stat Report: Not requested.

SPECIES ULTRASONOGRAPHIC EXAMINATION OF THE ABDOMEN

Canine

Urinary System

BREED

Cairn Terrier

The urinary bladder is mildly distended with anechoic urine. The Bladder wall is diffusely severely thickened and irregular, measuring approximately 0.66 cm in thickness. In the area of the trigone, ureteral papillae and proximal urethra, there appears to be a focal mass effect of irregular tissue measuring approximately 2.59 cm x 2.02 cm. Lack of urine distention makes it difficult to discern if this is thickened irregular tissue or a true mass effect.

SEX

Spayed Female

The left kidney has a normal shape and size (4.25 cm) with non-obstructive nephroliths. Overall echogenicity is slightly hyperechoic with poor corticomedullary distinction and a typical 1:3 cortex:medulla ratio. There is no evidence of perinephric inflammation or effusion. There is no evidence of pyelectasia, infarcts or hydroureter. Renal vasculature is normal.

AGE

1/1/15

WEIGHT

18 Pounds

The right kidney has a normal shape and size (4.69 cm) with non-obstructive nephroliths. Overall echogenicity is slightly hyperechoic with poor corticomedullary distinction and a typical 1:3 cortex:medulla ratio. There is no evidence of perinephric inflammation or effusion. There is no evidence of pyelectasia, infarcts or hydroureter. Renal vasculature is normal.

INTERPRETED BY

Kathleen Sennello DVM,
MS, Diplomate ACVIM
(Small Animal Internal
Medicine)

Adrenal Glands

The left adrenal gland is normal in size measuring 0.46 cm at the caudal pole. It is observed in its normal position cranial to the left renal artery. It is normal in appearance (uniformly hypoechoic) and shape with no evidence of a mass effect.

IMAGING PERFORMED BY

Rachel Brilhart RDMS

The right adrenal gland is normal in size measuring 0.35 cm at the caudal pole. It is observed in its normal position between the cranial aspect of the right kidney and the caudal vena cava. It is normal in appearance (uniformly hypoechoic) and shape with no evidence of a mass effect.

HOSPITAL NAME

Homeward Bound VS

Spleen

The spleen is subjectively normal in size, echotexture is homogenous, and the splenic capsule is smooth with no irregularities. The blood flow through the hilus and splenic parenchyma appears normal. No focal parenchymal abnormalities are visualized.

REFERRING VET

Dr. Vance

Liver

The liver is subjectively normal in size, and echogenicity with smooth peripheral margins. The parenchyma is heterogenous in echotexture with subtle, indistinct focal mottling. The visible portions of the vasculature and biliary tract appear normal. No focal nodules or cystic lesions are observed.

INVOICE

38684

The gall bladder lumen is moderately distended. The wall of the gall bladder is not thickened and has a smooth mucosal surface. There is a moderate amount of non-organized echogenic debris. The cystic and common bile ducts are normal/not visible.

Gastrointestinal

The stomach contains minimal luminal contents. It measures at a normal thickness of <0.7cm with some variability due to the presence of rugal folds. The distinction of the gastric wall layers is adequate and there is no impression of reduced peristaltic activity. No masses or focal lesions were observed.

The visualized areas of duodenum, jejunum and ileum have a uniform diameter with minimal fluid distension. Wall appears subjectively, mildly increased. Bowel loops follow a typical curvilinear path with distinct wall layering. Jejunum wall measured 0.32 cm. Visualized peristalsis appears appropriate. There were no focal lesions consistent with obstruction or a mass effect observed.

The ileocecal junction was visualized and exhibited normal intact wall layering and is subjectively of normal thickness. Sections of colon are visualized with formed fecal material and gas shadowing distally. There is no observed focal or generalized colon wall thickening or loss of layering.

Pancreas

The pancreas is normal and isoechoic to surrounding mesentery. There is no evidence of nodules or cystic lesions. There is no evidence of regional mesenteric inflammation or fluid.

Free Abdomen

Evaluation of the peritoneal cavity did not reveal any evidence of effusion, or subjective lymphadenomegaly. The Medial iliac nodes appear normal and there was no evidence of a caudal aortic thrombus at the bifurcation. The omentum is of normal uniform echogenicity.

PRIMARY FINDINGS

- Severely thickened and irregular urinary bladder wall with focal thickening/mass effect in the area of the trigone. Lack of urine distention makes this area difficult to assess, but there is concern for a possible mass effect.
- Decreased corticomedullary distinction in both kidneys with non-obstructive nephroliths – Mild loss of corticomedullary distinction in both kidneys could be consistent with chronic degenerative disease or interstitial nephrosis. The hyperechoic mineralized foci observed at the corticomedullary junction of the left/right kidney are consistent with small, non-obstructive nephroliths.
- Subjectively thickened small intestine – The mild small intestinal wall changes may be a normal variant in this patient or could be consistent with an inflammatory process (e.g., inflammatory bowel disease).

SECONDARY FINDINGS

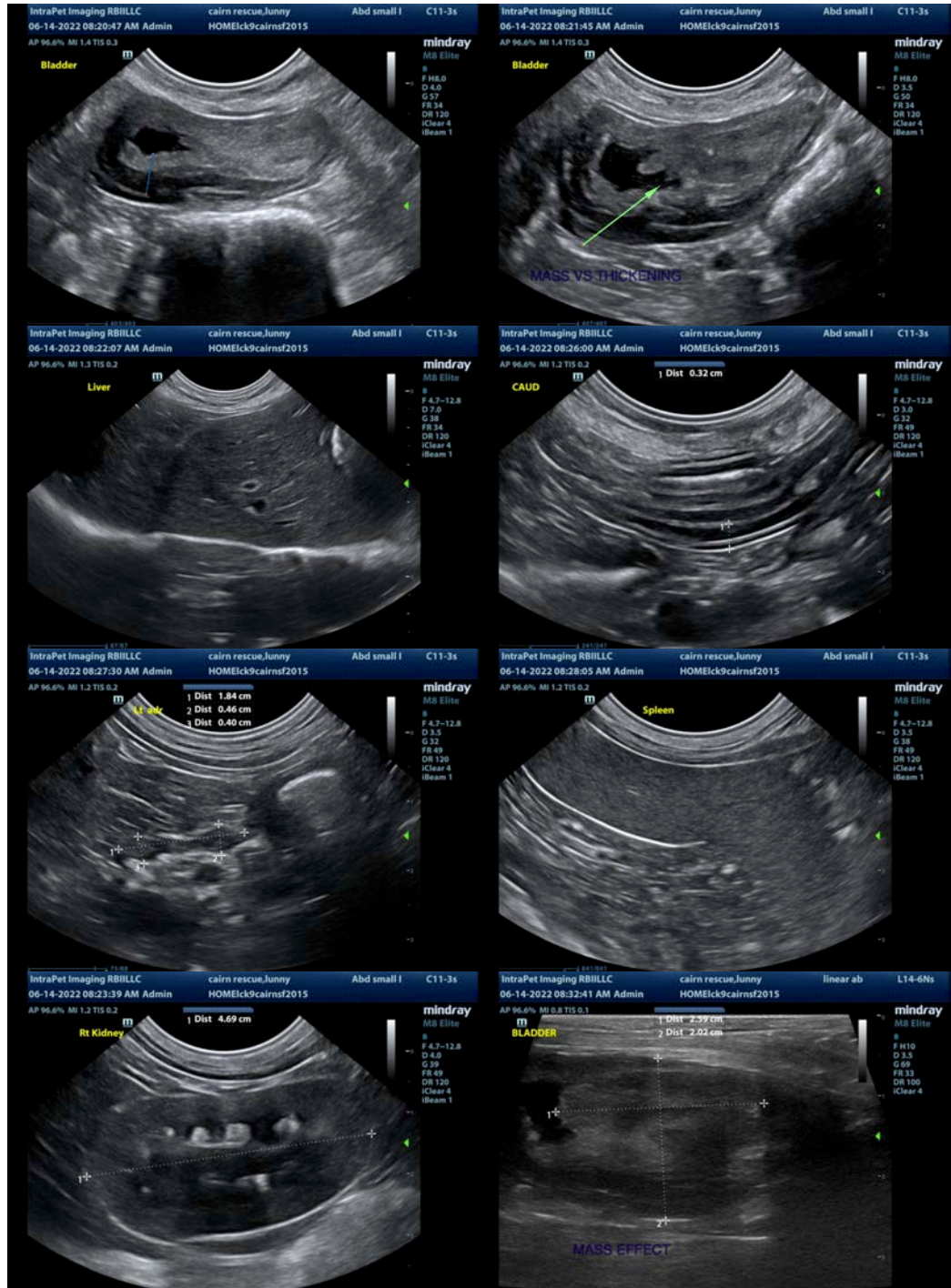
- Heterogeneous liver – The hepatic changes are consistent with age-related parenchymal remodeling and are not considered clinically significant at this time.

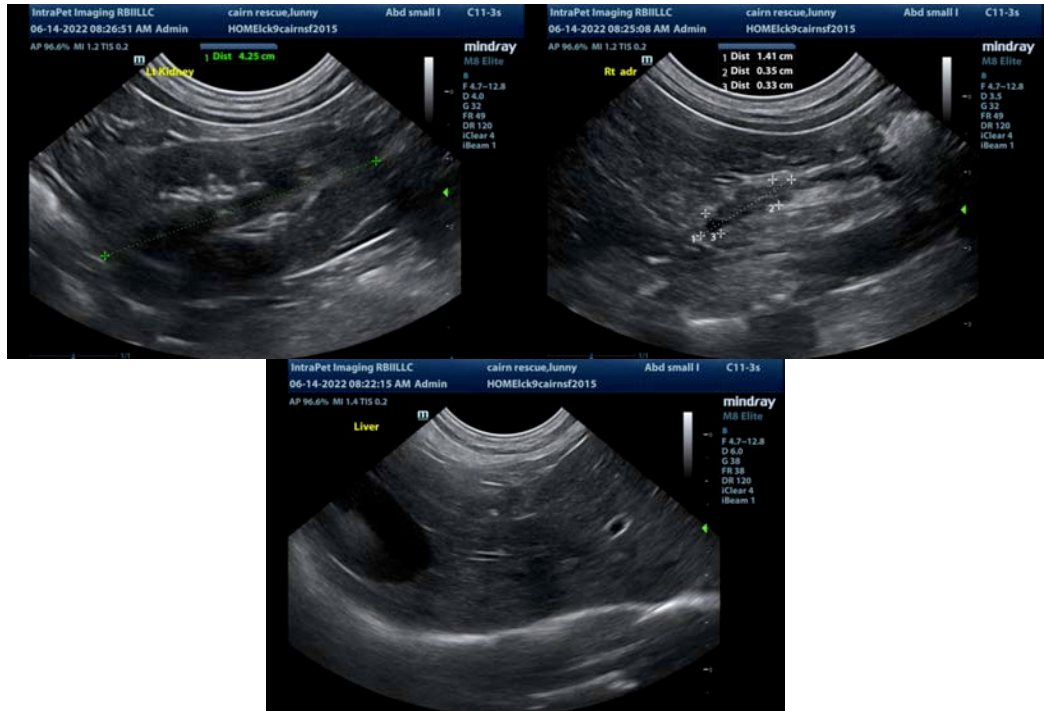
INTERPRETATION OF THE FINDINGS & FURTHER RECOMMENDATIONS

The bladder wall is severely thickened and irregular. There is concern for a possible mass effect in the area of the trigone, but this area is difficult to fully assess due to lack of urine distention. Recommend a urinalysis and culture, treatment for bacterial cystitis, and consider symptomatic treatment for possible bladder neoplasm (NSAID such as Piroxicam and Misoprostol if renal values are ok), and reevaluation of the urinary bladder in 7-10 days with efforts to try and keep the patient from voiding. Additionally, a urine BRAF test could be considered. If this test is positive, it would increase the likelihood that a transitional cell carcinoma is present. A negative test result is inconclusive. Alternately, you could consider cytology on a free catch urine sample, as often there are adequate cells present to make a diagnosis.

Both kidneys appear somewhat irregular with decreased corticomedullary distinction and nephroliths. Recommend a blood pressure evaluation, urinalysis and culture.

The small intestine appears subjectively thickened. If there are no significant GI signs present, then recommend continued monitoring.





The information and recommendations provided are based on the images presented by the referring veterinarian/sonographer. No evaluation can be communicated regarding pathology that was not visible in the image/video clips provided.

Thank you for this referral. If the clinical or image interpretation does not parallel your findings or if I can be of any further assistance please contact me.

Kathleen Sennello DVM,MS, Diplomate ACVIM (Small animal Internal Medicine)
kathleen.sennello@sonopath.com