

**PATIENT**

Lucee Woodruff

SPECIES

Canine

BREED

Old English Bulldog

SEX

Spayed Female

AGE

9.5 Years

WEIGHT

86 Pounds

INTERPRETED BYKathleen Sennello DVM,
MS, Diplomate ACVIM
(Small Animal Internal
Medicine)**IMAGING PERFORMED BY**

Amy Mayhew, LVT

HOSPITAL NAME

SVS Imaging MI

REFERRING VET

Family Pet Practice

INVOICE

38673

DATE

6/14/22

PRESENTING CLINICAL SIGNS

Presented 6/14/22 for ACTH Stim, AUS, prior to mass removals 5/24/22- liver bloodwork ALP >993, ALT 178 1/19/22- wellness bloodwork ALP1169, ALT 186 Recommend mass removals- Rec. AUS, thoracic rads, bloodwork prior to procedure for anesthetic risk assessment and met check. O considering having surgery done by ASC since Lucee had her TPLO there #1 rt chest - growing recently, irritated as P lays on that side and it is now ulcerated. rec Tshirt #2 Anterior rt shldr - has been tested before #3 left ventral flank skin fold has been there for 3 months

Abnormal PE/Chem/CBC/UA Results: Last exam Jan 2022- abnormalities: 5. Mild tartar and worn crowns 8. Left caudal elbow small black pigmented dermal mass 0.4mm x 0.5mm- Rec fna, O elected to wait at this time, recommend removal with other masses noted Right cranial shoulder black pigmented dermal mass 1cm x 2.5cm- previously aspirated with few spindle cells in sample Left lateral tarsus 3x4mm black pigmented dermal mass- discussed FNA, o elects to hold on testing at this time. Consider removal with other masses noted right lateral thorax 1cm x 3cm black pigmented dermal mass with dried dessicate tissue on surface- **Please see attached BW, ACTH stim pending.

ULTRASONOGRAPHIC EXAMINATION OF THE ABDOMEN**Urinary System**

The urinary bladder is moderately distended with anechoic urine. The Bladder wall, trigone, ureteral papillae and visible urethra (to a depth of 2cm) appear normal with no evidence of wall thickening, mucosal irregularities, masses or cystic calculi.

The left kidney has a normal shape and size (7.59 cm). Overall echogenicity is normal with adequate corticomedullary distinction and a typical 1:3 cortex:medulla ratio. There is no evidence of perinephric inflammation or effusion. There is no evidence of pyelectasia, nephroliths, infarcts or hydroureter. Renal vasculature is normal.

The right kidney has a normal shape and size (7.93 cm). Overall echogenicity is normal with adequate corticomedullary distinction and a typical 1:3 cortex:medulla ratio. There is no evidence of perinephric inflammation or effusion. There is no evidence of pyelectasia, nephroliths, infarcts or hydroureter. Renal vasculature is normal.

Adrenal Glands

The left adrenal gland is normal/borderline large in size measuring 0.85 cm at the caudal pole. It is observed in its normal position cranial to the left renal artery. It is normal in appearance (uniformly hypoechoic) and shape with no evidence of a mass effect.

The right adrenal gland is normal/borderline large in size measuring 1.17 cm at the caudal pole. It is observed in its normal position between the cranial aspect of the right kidney and the caudal vena cava. It is normal in appearance (uniformly hypoechoic) and shape with no evidence of a mass effect.

Spleen

The spleen is subjectively normal in size. The spleen echotexture is heterogenous and mottled, the splenic capsule is smooth with no irregularities. The blood flow through the hilus and splenic parenchyma appears normal. There are numerous, very ill-defined, hypoechoic lesions within the splenic parenchyma, measuring 0.67, 0.45, 0.56 cm, which do not deviate the splenic capsule.

Liver

The liver is subjectively normal in size, and echogenicity with smooth peripheral margins. The parenchyma is mildly heterogenous in echotexture with subtle, indistinct focal mottling. The visible portions of the vasculature and biliary tract appear normal. There is an iso- to hypoechoic mass effect visualized in the caudal liver, from the right side measuring approximately 4.08 cm x 4.78 cm.

**PATIENT**

Lucee Woodruff

The gallbladder lumen is moderately distended. The wall of the gall bladder is not thickened and has a smooth mucosal surface. Luminal contents are primarily anechoic. The cystic and common bile ducts are normal/not visible.

SPECIES

Canine

Gastrointestinal

The stomach contains minimal luminal contents. It measures at a normal thickness of <0.7cm with some variability due to the presence of rugal folds. The distinction of the gastric wall layers is adequate and there is no impression of reduced peristaltic activity. No masses or focal lesions were observed.

BREED

Old English Bulldog

The visualized areas of duodenum, jejunum and ileum have a relatively uniform diameter with minimal fluid distension. Wall thickness is normal. Bowel loops follow a curvilinear path with distinct wall layering maintaining the typical 1:3 muscularis:mucosa layer ratio. The duodenum measured as normal (between 0.3-0.5cm in wall thickness) and the jejunum measured as normal (between 0.2-0.47cm.)

SEX

Spayed Female

Visualized peristalsis appears appropriate. There were no focal lesions consistent with obstruction or a mass effect observed.

AGE

9.5 Years

The ileocecal junction was visualized and exhibited normal intact wall layering and is subjectively of normal thickness. Sections of colon are visualized with formed fecal material and gas shadowing distally. There is no observed focal or generalized colon wall thickening or loss of layering.

Pancreas**WEIGHT**

86 Pounds

The pancreas is prominent and mottled compared to the surrounding isoechoic mesentery. There is no evidence of nodules or cystic lesions. There is no evidence of regional mesenteric inflammation or fluid.

Free Abdomen**INTERPRETED BY**

Kathleen Sennello DVM,
MS, Diplomate ACVIM
(Small Animal Internal
Medicine)

Evaluation of the peritoneal cavity did not reveal any evidence of effusion, or subjective lymphadenomegaly. The Medial iliac nodes appear normal and there was no evidence of a caudal aortic thrombus at the bifurcation. The omentum is of normal uniform echogenicity.

PRIMARY FINDINGS

- Bilateral adrenomegaly – The bilateral adrenomegaly could be consistent with bilateral hyperplasia (e.g., secondary to pituitary-dependent hyperadrenocorticism), bilateral infiltrative neoplasia, inflammatory adrenal disease, other. Correlation with clinical findings is recommended.
- Mottled spleen – The diffuse splenic changes are non-specific and could be consistent with lymphoid hyperplasia, extramedullary hematopoiesis, infiltrative neoplasia, inflammation, other. Cytology or histopathology would be necessary to get a definitive diagnosis.
- Heterogeneous liver with iso- to hypoechoic mass effect – The diffuse hepatic changes are non-specific and could be consistent with vacuolar hepatopathy, nodular hyperplasia, inflammatory/immune-mediated disease, fibrosis, extramedullary hematopoiesis, toxic hepatopathy (e.g., copper), infiltrative neoplasia (less likely) or other hepatopathy. The mass lesion observed appears to be arising from the liver, and could represent a benign or neoplastic process.

IMAGING PERFORMED BY

Amy Mayhew, LVT

HOSPITAL NAME

SVS Imaging MI

REFERRING VET

Family Pet Practice

SECONDARY FINDINGS

- Prominent, mottled pancreas – The pancreatic changes are most consistent with age-related parenchymal remodeling, potentially secondary to a prior inflammatory episode, early fibrosis or chronic pancreatitis.

INVOICE

38673

DATE

6/14/22

IMAGING PERFORMED BY

SVS Mobile Imaging MI 734-637-7711
svsimagingmi@gmail.com



PATIENT

Lucee Woodruff

SPECIES

Canine

BREED

Old English Bulldog

SEX

Spayed Female

AGE

9.5 Years

WEIGHT

86 Pounds

INTERPRETED BY

Kathleen Sennello DVM,
MS, Diplomate ACVIM
(Small Animal Internal
Medicine)

IMAGING PERFORMED BY

Amy Mayhew, LVT

HOSPITAL NAME

SVS Imaging MI

REFERRING VET

Family Pet Practice

INVOICE

38673

DATE

6/14/22

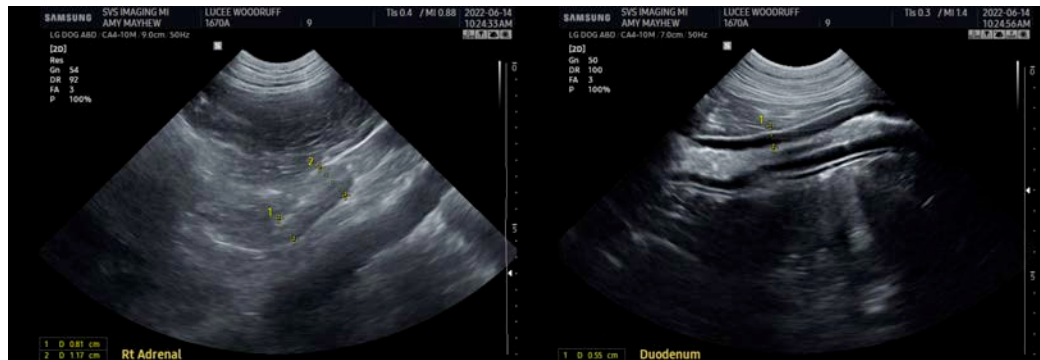
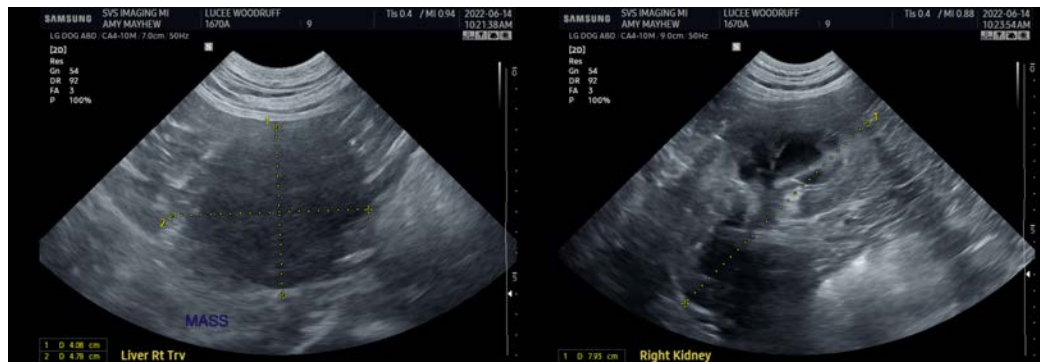
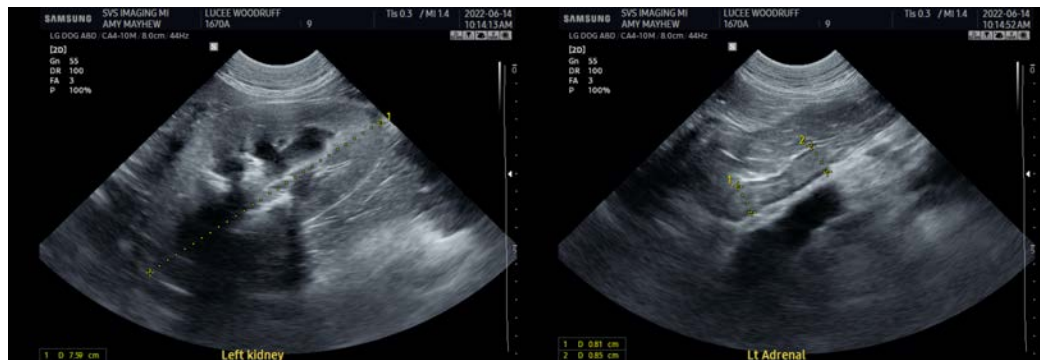
INTERPRETATION OF THE FINDINGS & FURTHER RECOMMENDATIONS

Both adrenal glands appear prominent and plump. If symptoms of Cushing's disease are present, adrenal function testing could be considered.

The liver appears somewhat heterogeneous and large. This could be consistent with a vacuolar/steroid hepatopathy, but there is also a mass effect in the region of the caudal liver. This is most consistent with a primary hepatic lesion, but an alternative mass lesion could be considered. If surgical removal would be considered, then a contrast CT scan could be utilized for pre-operative planning. Additionally, a fine needle aspirate could be considered to rule out round cell neoplasia, etc.

Consider three view thoracic radiographs to rule out concurrent thoracic disease/involvement.

The spleen appears mildly mottled. A fine needle aspirate could be considered.



IMAGING PERFORMED BY

SVS Mobile Imaging MI 734-637-7711
svsimagingmi@gmail.com



EDUCATIONAL TELECONSULTATION SERVICES™
1-800-838-4268 info@sonopath.com SonoPath.com

PATIENT

Lucee Woodruff

SPECIES

Canine

BREED

Old English Bulldog

SEX

Spayed Female

AGE

9.5 Years

WEIGHT

86 Pounds

INTERPRETED BY

Kathleen Sennello DVM,
MS, Diplomate ACVIM
(Small Animal Internal
Medicine)

IMAGING PERFORMED BY

Amy Mayhew, LVT

HOSPITAL NAME

SVS Imaging MI

REFERRING VET

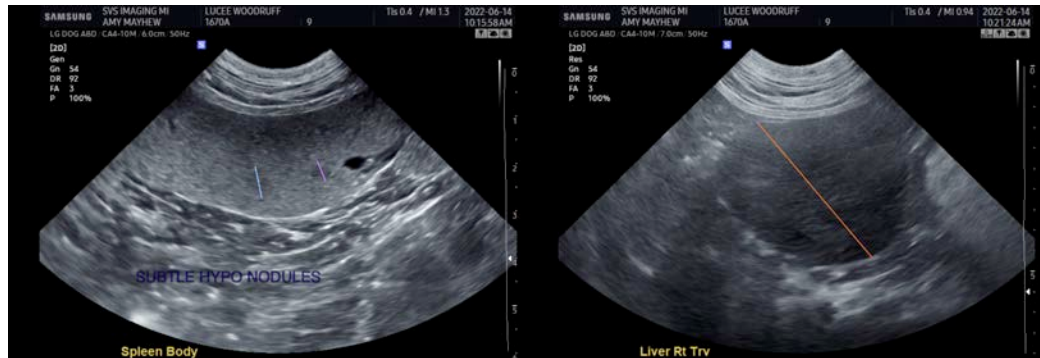
Family Pet Practice

INVOICE

38673

DATE

6/14/22



The information and recommendations provided are based on the images presented by the referring veterinarian/sonographer. No evaluation can be communicated regarding pathology that was not visible in the image/video clips provided.

Thank you for this referral. If the clinical or image interpretation does not parallel your findings or if I can be of any further assistance please contact me.

Kathleen Sennello DVM,MS, Diplomate ACVIM (Small animal Internal Medicine)

kathleen.sennello@sonopath.com