

**DATE PRESENTING CLINICAL SIGNS**

6/13/23

Vomiting 4 days, fever, hematuria/dripping blood from penis, intact male, enlarged prostate with blood and increase WBC in urine. Suspect prostatitis. Round, slightly large spleen on rad.

PATIENT

Zeus Griffin

Current Medications: Cerenia 160mg SID, Enrofloxacin 476mg SID x 8 days. Omeprazole 40 mg SID
Lab Results: CBC/Chem/Lyte - all WNL, 4dx negative - UA - hematuria and slight increase in WBC otherwise NSF.

SPECIES

Canine

Radiographs: round/oval spleen shadow, radiodensities near apex of bladder (poss. in GIT), enlarged prostate.

Date of Previous IntraPet Ultrasound: No previous.

Sedation: Dexdomitor/Torbugesic IV.

Stat Report: Not requested.

BREED

German Shepherd

Imaging Performed By: Stephanie Warga RDCS, RVT.

ULTRASONOGRAPHIC EXAMINATION OF THE ABDOMEN**SEX**

Intact Male

Urinary System

The urinary bladder is moderately distended with anechoic urine. The Bladder wall, trigone, ureteral papillae and visible urethra (to a depth of 2cm) appear normal with no evidence of wall thickening, mucosal irregularities, masses or cystic calculi.

AGE

6/28/13

The prostate is large in size (4.84 cm x 5.36 cm in cross section) but has a regular shape with smooth external margins. The parenchyma is hyperechoic and heterogenous but no discrete focal lesions are present. The prostatic urethra appears normal with no evidence of irregularity, invasion, mass effect or calculi.

WEIGHT

98.1 Pounds

The left kidney has a normal shape and size (9.06 cm). Overall echogenicity is normal with adequate corticomedullary distinction and a typical 1:3 cortex:medulla ratio. There is no evidence of focal perinephric inflammation or effusion. There is no evidence of pyelectasia, nephroliths, infarcts or hydroureter. Renal vasculature is normal.

INTERPRETED BY

Kathleen Sennello DVM,
MS, Diplomate ACVIM
(Small Animal Internal
Medicine)

The right kidney has a normal shape and size (7.77 cm). Overall echogenicity is normal with adequate corticomedullary distinction and a typical 1:3 cortex:medulla ratio. There is no evidence of focal perinephric inflammation or effusion. There is no evidence of pyelectasia, nephroliths, infarcts or hydroureter. Renal vasculature is normal.

HOSPITAL NAME

Hickory Vet Hospital

Adrenal Glands

The left adrenal gland is normal in size measuring 0.49 cm at the caudal pole. It is observed in its normal position cranial to the left renal artery. It is normal in appearance (uniformly hypoechoic) and shape with no evidence of a mass effect.

REFERRING VET

Dr. Snyder

The right adrenal gland is normal in size measuring 0.76 cm at the caudal pole. It is observed in its normal position between the cranial aspect of the right kidney and the caudal vena cava. It is normal in appearance (uniformly hypoechoic) and shape with no evidence of a mass effect.

INVOICE

43092

Spleen

The spleen is subjectively normal in size, echotexture is homogenous, and the splenic capsule is smooth with no irregularities. The blood flow through the hilus and splenic parenchyma appears normal. The spleen is somewhat folded upon itself in position, likely giving a "mass effect" on radiographs.

Liver

The liver is subjectively normal in size, and echogenicity with smooth peripheral margins. The parenchyma is homogenous echotexture. The visible portions of the vasculature and biliary tract appear normal. No focal nodules or cystic lesions are observed.

The gallbladder lumen is moderately distended. The wall of the gall bladder appears smooth with no significant mucosal irregularities. In the dependent portion of the gallbladder, there is hyperechoic shadowing debris, most consistent with mineralized debris and possibly two focal choleliths measuring approximately 2.62 cm x 2.42 cm.

Gastrointestinal

The stomach contains moderate shadowing ingesta. It measures at a normal thickness of <0.7cm with some variability due to the presence of rugal folds. The distinction of the gastric wall layers is adequate and there is no impression of reduced peristaltic activity. No masses or focal lesions were observed.

The visualized areas of duodenum, jejunum and ileum have a relatively uniform diameter with minimal fluid distension. Wall thickness is normal. Bowel loops follow a curvilinear path with distinct wall layering maintaining the typical 1:3 muscularis:mucosa layer ratio. Jejunum wall measures 0.33 cm. Visualized peristalsis appears appropriate. There were no focal lesions consistent with obstruction or a mass effect observed.

The ileocecal junction was visualized and exhibited normal intact wall layering and is subjectively of normal thickness. Sections of colon are visualized with formed fecal material and gas shadowing distally. There is no observed focal or generalized colon wall thickening or loss of layering.

Pancreas

The pancreas is normal and isoechoic to surrounding mesentery. There is no evidence of nodules or cystic lesions. There is no evidence of regional mesenteric inflammation or fluid.

Free Abdomen

Evaluation of the peritoneal cavity did not reveal any evidence of effusion, or subjective lymphadenomegaly. The Medial iliac nodes appear normal and there was no evidence of a caudal aortic thrombus at the bifurcation. The omentum is of normal uniform echogenicity.

Other

The left and right testicle are visualized and appear within normal limits. The left testicle measures 4.58 cm in length. The right testicle measures 4.65 cm in length.

ULTRASONOGRAPHIC FINDINGS

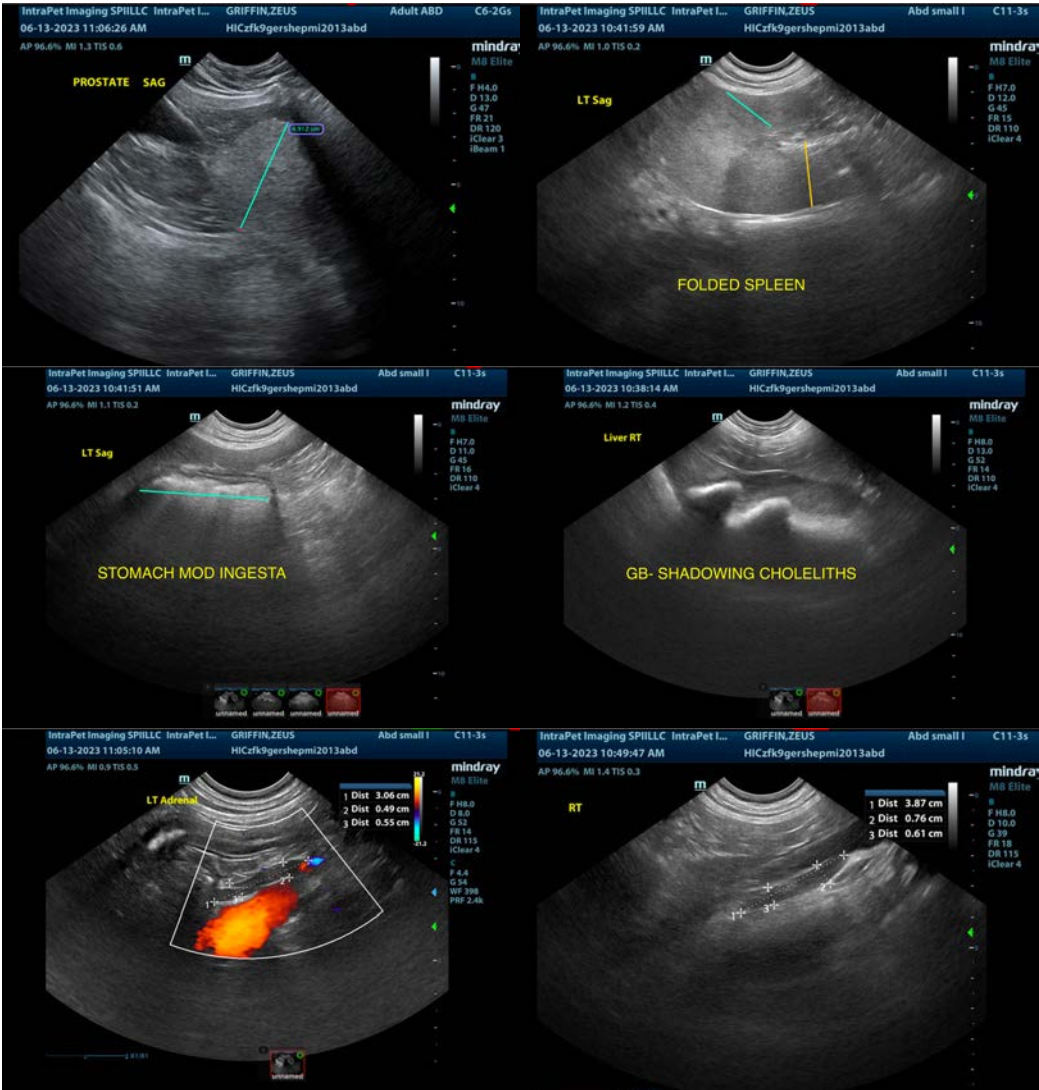
- Large, hyperechoic, heterogeneous prostate – Findings are most consistent with benign prostatic hypertrophy +/- prostatitis.
- Mineralized debris and likely choleliths visualized within the gallbladder – Consider starting Ursodiol therapy and correlate with liver enzymes. No evidence of an obstruction is visualized.
- Moderate shadowing ingesta within the gastric lumen – Correlate with the feeding history and abdominal radiographs. If the patient was adequately fasted consider such differentials as delayed gastric emptying, a partial outflow tract obstruction (none seen) or ingested foreign material.

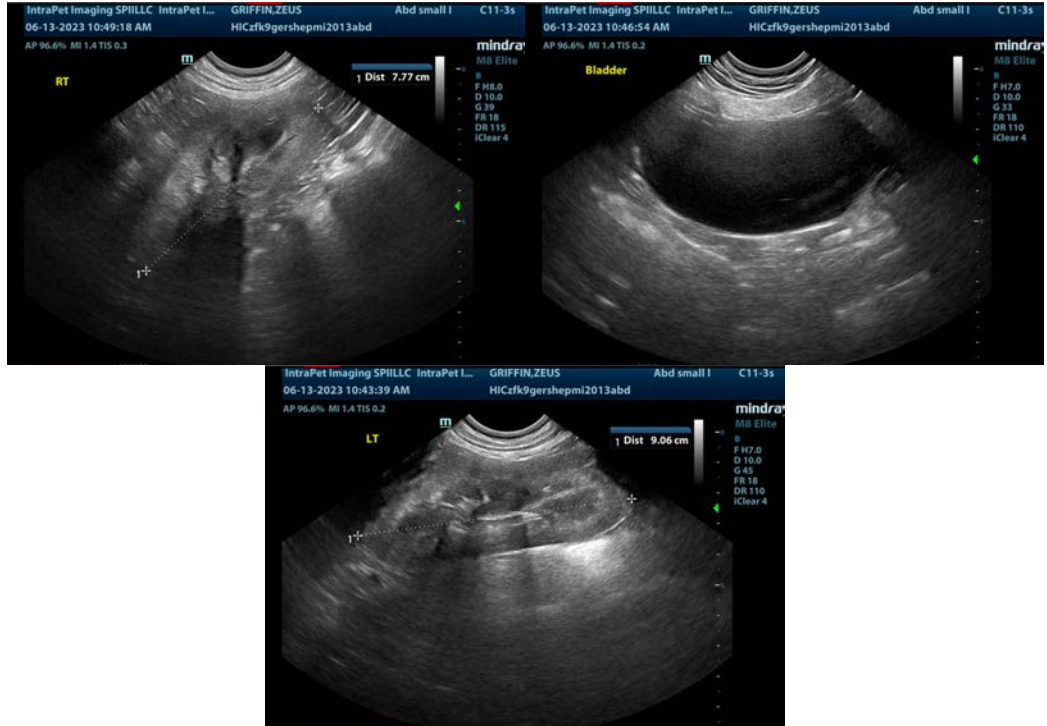INTERPRETATION OF THE FINDINGS & FURTHER RECOMMENDATIONS

The prostate is large and hyperechoic. These changes are most consistent with benign prostatic hypertrophy and possibly prostatitis, given the fever reported. Recommend urinalysis and treatment for prostatitis while awaiting culture and sensitivity results. It is unlikely that prostatitis will fully clear without the interruption of testosterone. Ideally, neutering would be curative in this situation (for BPH). If neutering is not possible, a testosterone blocker could be considered. If the prostate does not improve taking these measures,

recommend reevaluation and/or a fine needle aspirate, as the likelihood of underlying neoplasia is very low, but not impossible.

There is a moderate amount of mineralized debris and choleliths visualized in the gallbladder. The gallbladder wall appears relatively normal and there is no evidence of an obstruction at this time. Correlate these findings with liver values, and consider Ursodiol therapy and continued monitoring, as occasionally this can reduce the size or dissolve the stones.





The information and recommendations provided are based on the images presented by the referring veterinarian/sonographer. No evaluation can be communicated regarding pathology that was not visible in the image/video clips provided.

Thank you for this referral. If the clinical or image interpretation does not parallel your findings or if I can be of any further assistance please contact me.

Kathleen Sennello DVM,MS, Diplomate ACVIM (Small animal Internal Medicine)
info@sonopath.com