



PATIENT PRESENTING CLINICAL SIGNS

Tyson Leal
Patient has been dribbling urine when walking at times for at least the past 1.5 weeks. Patient seems to be posturing to urinate at times and no urine production is noted. No longer lifting hind limb to urinate. Overall seems weak in the hind end. Vomited multiple times last week and has been having decreased appetite and dark diarrhea. Owner has not noticed polydipsia. Patient has lost 13# since last seen in August 2022 for cutaneous hemangiosarcoma and subcutaneous grade 2 mast cell tumor surgical excision. At that time, patient had a history of anemia. Today HCT is 54%, however, patient is moderately dehydrated and cachexic. Mentation is quieter than last reported. Exam was performed after initial radiographs were obtained. Large mass (bladder) palpable mid-abdomen. Patient was catheterized and 520mL of urine was obtained after initially starting with manual expression of the bladder. Enlarged prostate palpable upon rectal exam. Patient exhibits overall weakness and lethargy with significantly delayed (almost absent) CPs upon exam, however, sluggishly ambulates with no overt hind limb paw scuffing. CBC revealed neutrophilia and leukocytosis.

SPECIES

Canine

BREED

Pit Bull

SEX

Neutered Male

AGE

10 Years

WEIGHT

61 Pounds

Abnormal PE/Chem/CBC/UA Results: RAD report Conclusions: Age related lung changes. There are no signs of pulmonary metastasis. Prostatomegaly with suspect mineralization- given the patient is neutered, malignant neoplasia such as adenocarcinoma is considered most likely. If the patient was neutered recently, prostatitis, benign prostatic hyperplasia or prostatic abscess are also considered.

ULTRASONOGRAPHIC EXAMINATION OF THE ABDOMEN

Urinary System

The urinary bladder is significantly distended with anechoic urine. In the region of the trigone, the bladder wall is severely thickened and irregular with an area of what appears to be focal mineralization. This thickening creates a mass effect measuring approximately 3.51 cm x 2.1 cm, which appears to be causing a bilateral ureteral obstruction. The proximal urethra appears thickened and dilated, measuring at 0.84 cm with intraluminal soft tissue, consistent with extension of a mass effect into the proximal urethra.

The prostate is large and slightly irregular in shape measuring 3.11 cm x 4.52 cm. The parenchyma is heterogeneous and somewhat hypochoic with too numerous to count mineralized foci. The appearance is concerning for a prostatic mass lesion.

The left kidney has a normal shape and size (7.32 cm) with severe pyelectasia at 2.42 cm. The ureter is dilated measuring 0.70 cm proximally. Overall echogenicity is normal with adequate corticomedullary distinction and a typical 1:3 cortex:medulla ratio. There is no evidence of focal perinephric inflammation or effusion. There is no evidence of nephroliths or infarcts. Renal vasculature is normal.

The right kidney has a normal shape and size (8.64 cm) with pyelectasia at 0.72 cm with dilated proximal ureter measuring at 0.57 cm. Overall echogenicity is normal with adequate corticomedullary distinction and a typical 1:3 cortex:medulla ratio. There is no evidence of focal perinephric inflammation or effusion. There is no evidence of nephroliths or infarcts. Renal vasculature is normal.

Adrenal Glands

The left adrenal gland is normal in size measuring 0.70 cm at the caudal pole. It is observed in its normal position cranial to the left renal artery. It is normal in appearance (uniformly hypochoic) and shape with no evidence of a mass effect.

INTERPRETED BY

Kathleen Sennello DVM,
MS, Diplomate ACVIM
(Small Animal Internal
Medicine)

IMAGING PERFORMED BY

Loetitia Saint-Jacques,
LVT

HOSPITAL NAME

LuxPetVet

REFERRING VET

Dr. Kristin Lee

INVOICE

43109

DATE

6/13/23



PATIENT

Tyson Leal

The right adrenal gland is normal in size measuring 0.90 cm at the caudal pole. It is observed in its normal position between the cranial aspect of the right kidney and the caudal vena cava. It is normal in appearance (uniformly hypoechoic) and shape with no evidence of a mass effect.

SPECIES

Spleen

Canine

The spleen is subjectively normal in size, echotexture is homogenous, and the splenic capsule is smooth with no irregularities. The blood flow through the hilus and splenic parenchyma appears normal. No focal parenchymal abnormalities are visualized.

BREED

Pit Bull

Liver

SEX

Neutered Male

The liver is subjectively normal in size, and echogenicity with smooth peripheral margins. The parenchyma is homogenous echotexture. The visible portions of the vasculature and biliary tract appear normal. No focal nodules or cystic lesions are observed.

AGE

10 Years

The gallbladder lumen is moderately distended. The wall of the gall bladder is not thickened and has a smooth mucosal surface. Luminal contents are mild and primarily anechoic. The cystic and common bile ducts are normal/not visible.

WEIGHT

61 Pounds

Gastrointestinal

The stomach contains minimal luminal contents. It measures at a normal thickness of <0.7cm with some variability due to the presence of rugal folds. The distinction of the gastric wall layers is adequate and there is no impression of reduced peristaltic activity. No masses or focal lesions were observed.

INTERPRETED BY

Kathleen Sennello DVM,
MS, Diplomate ACVIM
(Small Animal Internal
Medicine)

The visualized areas of duodenum, jejunum and ileum have a relatively uniform diameter with minimal fluid distension. Wall thickness is normal. Bowel loops follow a curvilinear path with distinct wall layering maintaining the typical 1:3 muscularis:mucosa layer ratio. The duodenum measured as normal (between 0.3-0.5cm in wall thickness) and the jejunum measured as normal (between 0.2-0.47cm.) Visualized peristalsis appears appropriate. There were no focal lesions consistent with obstruction or a mass effect observed.

IMAGING PERFORMED BY

Loetitia Saint-Jacques,
LVT

The ileocecal junction was visualized and exhibited normal intact wall layering and is subjectively of normal thickness. Sections of colon are visualized with formed fecal material and gas shadowing distally. There is no observed focal or generalized colon wall thickening or loss of layering.

HOSPITAL NAME

LuxPetVet

Pancreas

The area of the pancreas is normal and isoechoic to surrounding mesentery. There is no evidence of nodules or cystic lesions. There is no evidence of regional mesenteric inflammation or fluid.

REFERRING VET

Dr. Kristin Lee

Free Abdomen

Evaluation of the peritoneal cavity did not reveal any evidence of effusion, or subjective lymphadenomegaly. The Medial iliac nodes appear normal and there was no evidence of a caudal aortic thrombus at the bifurcation. The omentum is of normal uniform echogenicity.

INVOICE

43109

ULTRASONOGRAPHIC FINDINGS

DATE

6/13/23

- Large, irregular mineralized mass effect visualized in the trigone region of the urinary bladder – Findings are concerning for possible transitional cell carcinoma/extension of the prostatic mass into the urinary bladder.



PATIENT

Tyson Leal

SPECIES

Canine

BREED

Pit Bull

SEX

Neutered Male

AGE

10 Years

WEIGHT

61 Pounds

INTERPRETED BY

Kathleen Sennello DVM,
MS, Diplomate ACVIM
(Small Animal Internal
Medicine)

IMAGING PERFORMED BY

Loetitia Saint-Jacques,
LVT

HOSPITAL NAME

LuxPetVet

REFERRING VET

Dr. Kristin Lee

INVOICE

43109

DATE

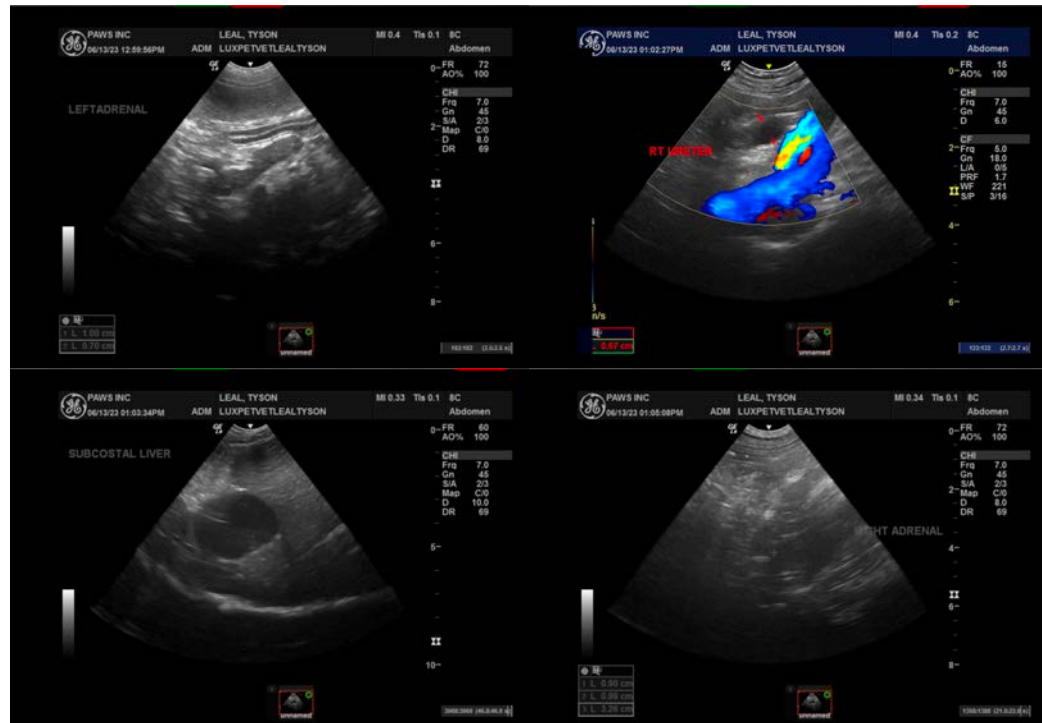
6/13/23

- Large, irregular, mineralized prostate – These changes are concerning for prostatic neoplasia in this neutered male dog with extension into the prostatic and pre-prostatic urethra.
- Bilateral renal pyelectasia and ureteral dilation – Findings are consistent with ureteral obstruction at the level of the trigone due to the urinary bladder mass described.

INTERPRETATION OF THE FINDINGS & FURTHER RECOMMENDATIONS

The prostate is large, mineralized and irregular with extension of this abnormal tissue into the prostatic urethra and pre-prostatic urethra. Additionally, there is a mass effect in the trigone of the urinary bladder. I suspect this represents extension of the suspected prostatic neoplastic process into the urinary bladder. Primary differential is transitional cell carcinoma, although other differentials are possible. This mass effect appears to be causing a urethral obstruction (history reports difficulty with urination) as well as a ureteral obstruction, resulting in hydroureter and pyelectasia of both kidneys. A urinary catheter is visualized within the prostate and trigone of the urinary bladder. A traumatic catheterization at this level with cytologic evaluation is likely to obtain a diagnosis.

Once a cytologic diagnosis is obtained, recommend consultation with a veterinary oncologist regarding treatment options and prognosis. If appropriate clinically, Piroxicam and Misoprostol could be initiated while awaiting test results.





PATIENT

Tyson Leal

SPECIES

Canine

BREED

Pit Bull

SEX

Neutered Male

AGE

10 Years

WEIGHT

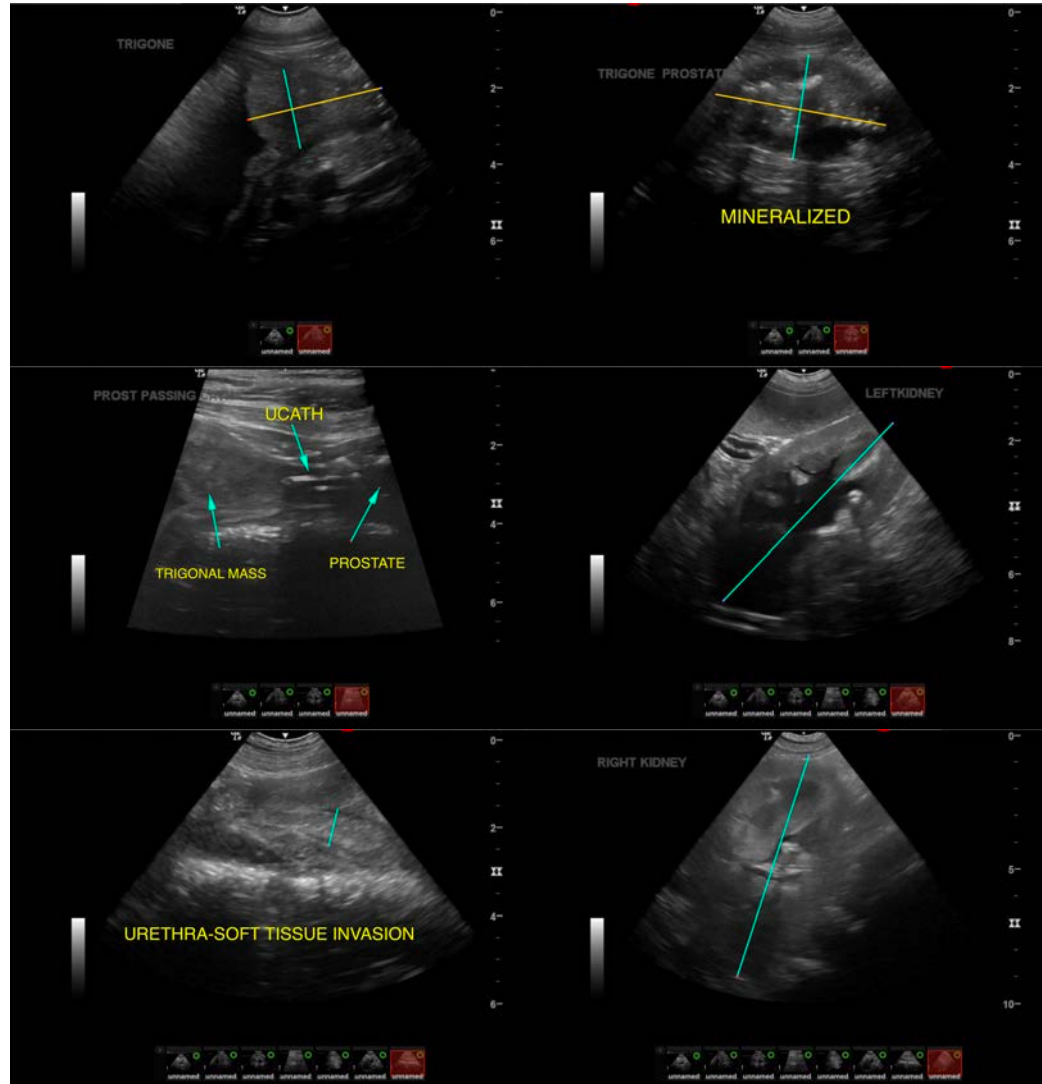
61 Pounds

INTERPRETED BY

Kathleen Sennello DVM,
MS, Diplomate ACVIM
(Small Animal Internal
Medicine)

**IMAGING
PERFORMED BY**

Loetitia Saint-Jacques,
LVT



HOSPITAL NAME

LuxPetVet

REFERRING VET

Dr. Kristin Lee

INVOICE

43109

DATE

6/13/23

The information and recommendations provided are based on the images presented by the referring veterinarian/sonographer. No evaluation can be communicated regarding pathology that was not visible in the image/video clips provided.

Thank you for this referral. If the clinical or image interpretation does not parallel your findings or if I can be of any further assistance please contact me.

Kathleen Sennello DVM,MS, Diplomate ACVIM (Small animal Internal Medicine)

info@sonopath.com