



PATIENT PRESENTING CLINICAL SIGNS

Puff Burd Anemia, pre-anesthetic screening for dentistry. Mild leukopenia. Current meds: Convenia; DT sedation for u/s

SPECIES Abnormal PE/Chem/CBC/UA Results: HCT 25; WBC 3.4; CHEM WNL; Cysto pending

Feline

BREED

DMH

SEX

Spayed Female

AGE

12 Years

WEIGHT

Not Provided

INTERPRETED BY

Kathleen Sennello DVM,
MS, Diplomate ACVIM
(Small Animal Internal
Medicine)

IMAGING PERFORMED BY

Shari Reffi, CVT

HOSPITAL NAME

VCA Blirstown AH

REFERRING VET

Dr. Lovell

INVOICE

43105

DATE

7/13/23

ULTRASONOGRAPHIC EXAMINATION OF THE ABDOMEN

Urinary System

The urinary bladder is moderately distended with mild primarily suspended echogenic debris present. The Bladder wall, trigone, ureteral papillae and visible urethra (to a depth of 2cm) appear normal with no evidence of wall thickening, mucosal irregularities, or masses. Suspended echogenic debris of this type can be associated with small crystals, cellular debris and proteinaceous debris. The dependent echogenic debris could represent sandy debris/small stones.

The left kidney has a normal shape and size (3.62 cm). Overall echogenicity is slightly hyperechoic with mildly reduced corticomedullary distinction and a typical 1:3 cortex:medulla ratio. There is no evidence of focal perinephric inflammation or effusion. There is no evidence of pyelectasia, nephroliths, infarcts or hydroureter. Renal vasculature is normal.

The right kidney has a normal shape and size (3.45 cm). Overall echogenicity is slightly hyperechoic with mildly reduced corticomedullary distinction and a typical 1:3 cortex:medulla ratio. There is no evidence of focal perinephric inflammation or effusion. There is no evidence of pyelectasia, nephroliths, infarcts or hydroureter. Renal vasculature is normal.

Adrenal Glands

The left adrenal gland is normal in size measuring 0.31 cm at the caudal pole. It is observed in its normal position cranial to the left renal artery. It is normal in appearance (uniformly hypoechoic) and shape with no evidence of a mass effect.

The right adrenal gland is normal in size measuring 0.34 cm at the caudal pole. It is observed in its normal position between the cranial aspect of the right kidney and the caudal vena cava. It is normal in appearance (uniformly hypoechoic) and shape with no evidence of a mass effect.

Spleen

The spleen is prominent in size. The spleen echotexture is heterogenous and mottled, the splenic capsule is smooth with no irregularities. The blood flow through the hilus and splenic parenchyma appears normal. No focal parenchymal abnormalities are visualized.

Liver

The liver is subjectively normal in size, and echogenicity with smooth peripheral margins. The parenchyma is homogenous echotexture. The visible portions of the vasculature and biliary tract appear normal. No focal nodules or cystic lesions are observed.

The gallbladder lumen is moderately distended. The wall of the gall bladder is not thickened and has a smooth mucosal surface. Luminal contents are mild and primarily anechoic. The cystic and common bile ducts are normal/not visible.



PATIENT *Gastrointestinal*

Puff Burd The stomach contains minimal luminal contents. It measures at a normal thickness of <0.36cm with some variability due to the presence of rugal folds. The distinction of the gastric wall layers is adequate and there is no impression of reduced peristaltic activity. No masses or focal lesions were observed.

SPECIES

Feline The visualized areas of duodenum, jejunum and ileum have a relatively uniform diameter with minimal fluid distension. Wall thickness is normal. Bowel loops follow a curvilinear path with distinct wall layering maintaining the typical 1:3 muscularis:mucosa layer ratio. Jejunum wall measures 0.22 cm. **BREED** Visualized peristalsis appears appropriate. There were no focal lesions consistent with obstruction or a mass effect observed.

DMH

SEX

Spayed Female The ileocecal junction was visualized and exhibited normal intact wall layering and is subjectively of normal thickness. Sections of colon are visualized with formed fecal material and gas shadowing distally. There is no observed focal or generalized colon wall thickening or loss of layering.

AGE

12 Years

Pancreas

The pancreas is normal and isoechoic to surrounding mesentery. There is no evidence of nodules or cystic lesions. There is no evidence of regional mesenteric inflammation or fluid.

WEIGHT

Not Provided

Free Abdomen

Evaluation of the peritoneal cavity did not reveal any evidence of effusion, or subjective lymphadenomegaly. The Medial iliac nodes appear normal and there was no evidence of a caudal aortic thrombus at the bifurcation. The omentum is of normal uniform echogenicity.

INTERPRETED BY

Kathleen Sennello DVM,
MS, Diplomate ACVIM
(Small Animal Internal
Medicine)

ULTRASONOGRAPHIC FINDINGS

- Suspended echogenic debris and dependent hyperechoic debris visualized in the urinary bladder – Correlate with radiographs, a urinalysis and culture.
- Decreased corticomedullary distinction in both kidneys – The bilateral renal findings are consistent with age-related change.
- Subjectively prominent/mildly mottled spleen – The diffuse splenic changes are non-specific and could be consistent with lymphoid hyperplasia, extramedullary hematopoiesis, infiltrative neoplasia, inflammation, other. Cytology or histopathology would be necessary to get a definitive diagnosis.

IMAGING PERFORMED BY

Shari Reffi, CVT

HOSPITAL NAME

VCA Blirstown AH

REFERRING VET

Dr. Lovell

INVOICE

43105

DATE

7/13/23

INTERPRETATION OF THE FINDINGS & FURTHER RECOMMENDATIONS

The changes observed on today's scan are mild and subjective. Depending on the size of this cat (weight not provided), the spleen could be slightly prominent/mildly mottled. A fine needle aspirate could be considered. Additionally there is a large amount of sandy debris/suspended echogenic debris in the urinary bladder. Correlate this with abdominal radiographs, a urinalysis and culture.

Consider pathologist review of the CBC, looking for any atypical cells, hemoparasites, etc., and a reticulocyte count to determine if this is regenerative anemia, and to better classify it in order to make a differential list/treatment plan.

Recommend three view thoracic radiographs to evaluate for possible concurrent thoracic disease/involvement.



PATIENT

Puff Burd

SPECIES

Feline

BREED

DMH

SEX

Spayed Female

AGE

12 Years

WEIGHT

Not Provided

INTERPRETED BY

Kathleen Sennello DVM,
MS, Diplomate ACVIM
(Small Animal Internal
Medicine)

**IMAGING
PERFORMED BY**

Shari Reffi, CVT

HOSPITAL NAME

VCA Blirstown AH

REFERRING VET

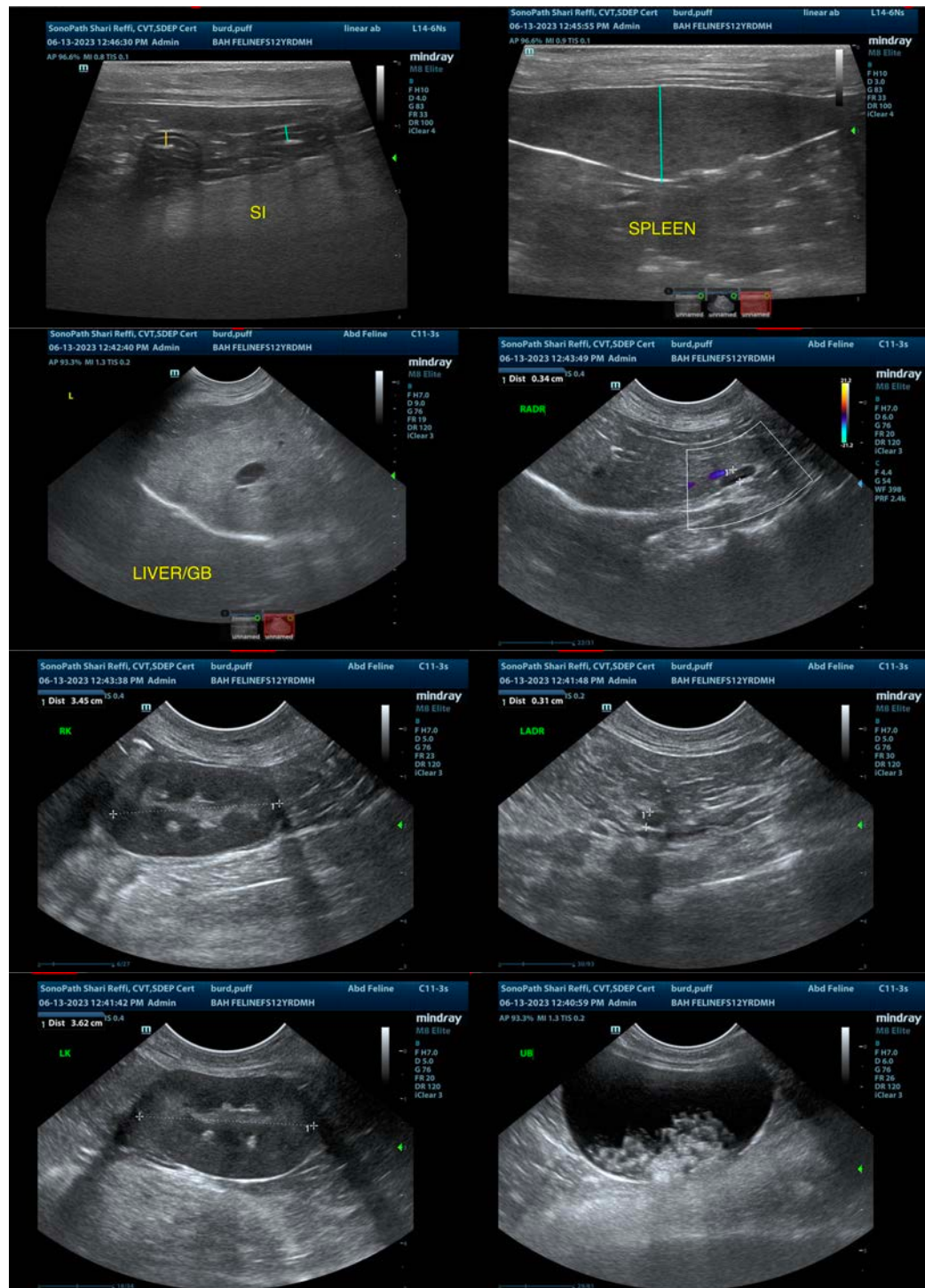
Dr. Lovell

INVOICE

43105

DATE

7/13/23





PATIENT

Puff Burd

SPECIES

Feline

BREED

DMH

SEX

Spayed Female

AGE

12 Years

WEIGHT

Not Provided

INTERPRETED BY

Kathleen Sennello DVM,
MS, Diplomate ACVIM
(Small Animal Internal
Medicine)

**IMAGING
PERFORMED BY**

Shari Reffi, CVT

HOSPITAL NAME

VCA Blirstown AH

REFERRING VET

Dr. Lovell

INVOICE

43105

DATE

7/13/23

The information and recommendations provided are based on the images presented by the referring veterinarian/sonographer. No evaluation can be communicated regarding pathology that was not visible in the image/video clips provided.

Thank you for this referral. If the clinical or image interpretation does not parallel your findings or if I can be of any further assistance please contact me.

Kathleen Sennello DVM,MS, Diplomate ACVIM (Small animal Internal Medicine)

info@sonopath.com