

**PATIENT**

Daisy Price

**PRESENTING CLINICAL SIGNS**

**SPECIES**

Canine

**BREED**

Cockapoo

Vital Sign MM1 Weight 22.6 pounds BodyScor e9 5 - Ideal - 5 Temp 101.4 Pulse 150 CRT <2 sec BP 124/120/122 llat/rfl/7-15cm Dental 4 - Significant Pain 1 - No Visible Pain Alert BAR Muc Memb Pink/Healthy Chief Concern / Provisional Diagnosis: ~erythrocytosis elevated PCV (66%) initially noted on wellness BW in Febuary rechecked CBC 05/2022 and HCT had increased to 70.2%. the remainder of cbc was unremarkable. chemistry unremarkable, UA showed well concentrated urine, but was otherwise unremarkable. ab/chest rads were taken which were unremarkable. r/o open other history: therapeutic phlebotomy performed 5/29/2022- reduced PCV to 62% ~ Recent Diagnostics: Relevant Labratory Results / Abnormalities: ~chronically elevated HCT ~ Current medications (include full name, dosage and frequency): ~none

**SEX**

Spayed Female

**ULTRASONOGRAPHIC EXAMINATION OF THE ABDOMEN**

**AGE**

6 Years 2 Months

**WEIGHT**

22.6 Pounds

**Urinary System**

The urinary bladder is moderately distended with anechoic urine. The Bladder wall, trigone, ureteral papillae and visible urethra (to a depth of 2cm) appear normal with no evidence of wall thickening, mucosal irregularities, masses or cystic calculi.

The left kidney has a normal shape and size (4.7 cm). Overall echogenicity is normal with adequate corticomedullary distinction and a typical 1:3 cortex:medulla ratio. There is no evidence of perinephric inflammation or effusion. There is no evidence of pyelectasia, nephroliths, infarcts or hydroureter. Renal vasculature is normal.

The right kidney has a normal shape and size (5.29 cm). Overall echogenicity is normal with adequate corticomedullary distinction and a typical 1:3 cortex:medulla ratio. There is no evidence of perinephric inflammation or effusion. There is no evidence of pyelectasia, nephroliths, infarcts or hydroureter. Renal vasculature is normal.

**INTERPRETED BY**

Kathleen Sennello DVM,  
MS, Diplomate ACVIM  
(Small Animal Internal  
Medicine)

**Adrenal Glands**

The left adrenal gland is normal in size measuring 0.44 cm at the caudal pole. It is observed in its normal position cranial to the left renal artery. It is normal in appearance (uniformly hypoechoic) and shape with no evidence of a mass effect.

**IMAGING BY**

Loetitia Saint-Jacques,  
LVT

The right adrenal gland is normal in size measuring 0.52 cm at the caudal pole. It is observed in its normal position between the cranial aspect of the right kidney and the caudal vena cava. It is normal in appearance (uniformly hypoechoic) and shape with no evidence of a mass effect.

**HOSPITAL NAME**

MountainView AH

**Spleen**

The spleen is subjectively normal in size. The spleen echotexture is heterogenous and mottled, the splenic capsule is smooth with no irregularities. The blood flow through the hilus and splenic parenchyma appears normal. No focal parenchymal abnormalities are visualized.

**REFERRING VET**

Dr. Sarah Kalivoda

**Liver**

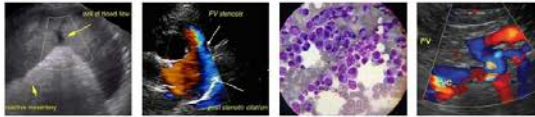
The liver is subjectively normal in size, and echogenicity with smooth peripheral margins. The parenchyma is homogenous echotexture. The visible portions of the vasculature and biliary tract appear normal. No focal nodules or cystic lesions are observed.

**INVOICE**

38604

**DATE**

6/10/22



## PATIENT

Daisy Price

The gall bladder lumen is moderately distended. The wall of the gall bladder is not thickened and has a smooth mucosal surface. There is a moderate amount of non-organized echogenic debris. The cystic and common bile ducts are normal/not visible.

## SPECIES

Canine

### **Gastrointestinal**

The stomach contains minimal luminal contents. It measures at a normal thickness of <0.7cm with some variability due to the presence of rugal folds. The distinction of the gastric wall layers is adequate and there is no impression of reduced peristaltic activity. No masses or focal lesions were observed.

## BREED

Cockapoo

The visualized areas of duodenum, jejunum and ileum have a relatively uniform diameter with minimal fluid distension. Wall thickness is normal. Bowel loops follow a curvilinear path with distinct wall layering maintaining the typical 1:3 muscularis:mucosa layer ratio. The duodenum measured as normal (between 0.3-0.5cm in wall thickness) and the jejunum measured as normal (between 0.2-0.47cm.) Visualized peristalsis appears appropriate. There were no focal lesions consistent with obstruction or a mass effect observed.

## SEX

Spayed Female

The ileocecal junction was visualized and exhibited normal intact wall layering and is subjectively of normal thickness. Sections of colon are visualized with formed fecal material and gas shadowing distally. There is no observed focal or generalized colon wall thickening or loss of layering.

## AGE

6 Years 2 Months

### **Pancreas**

The pancreas is normal and isoechoic to surrounding mesentery. There is no evidence of nodules or cystic lesions. There is no evidence of regional mesenteric inflammation or fluid.

## WEIGHT

22.6 Pounds

### **Free Abdomen**

Evaluation of the peritoneal cavity did not reveal any evidence of effusion, or subjective lymphadenomegaly. The Medial iliac nodes appear normal and there was no evidence of a caudal aortic thrombus at the bifurcation. The omentum is of normal uniform echogenicity.

## INTERPRETED BY

Kathleen Sennello DVM,  
MS, Diplomate ACVIM  
(Small Animal Internal  
Medicine)

## ULTRASONOGRAPHIC FINDINGS

## IMAGING BY

Loetitia Saint-Jacques,  
LVT

- Subjectively mildly mottled spleen – The diffuse splenic changes are non-specific and could be consistent with lymphoid hyperplasia, extramedullary hematopoiesis, infiltrative neoplasia, inflammation, other. Cytology or histopathology would be necessary to get a definitive diagnosis.
- Moderate gallbladder debris – The significance of the aggregated gallbladder sludge is unclear. This could represent an early mucocele, cholestasis, or may be secondary to fasting.

## HOSPITAL NAME

MountainView AH

## INTERPRETATION OF THE FINDINGS & FURTHER RECOMMENDATIONS

## REFERRING VET

Dr. Sarah Kalivoda

The lesions observed on today's scan are relatively mild and unlikely to be associated with polycythemia reported. A fine needle aspirate could be considered. There were no lesions visualized involving the kidneys or surrounding tissues that would suggest a cause for secondary polycythemia.

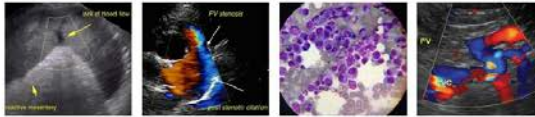
## INVOICE

38604

Recommend further evaluation for possible secondary polycythemia with chest radiographs, cardiac ultrasound (pending), abdominal ultrasound (already done), +/- pulse ox, etc.

## DATE

6/10/22



**PATIENT**

Daisy Price

**SPECIES**

Canine

**BREED**

Cockapoo

**SEX**

Spayed Female

**AGE**

6 Years 2 Months

**WEIGHT**

22.6 Pounds

**INTERPRETED BY**

Kathleen Sennello DVM,  
MS, Diplomate ACVIM  
(Small Animal Internal  
Medicine)

**IMAGING BY**

Loetitia Saint-Jacques,  
LVT

**HOSPITAL NAME**

MountainView AH

**REFERRING VET**

Dr. Sarah Kalivoda

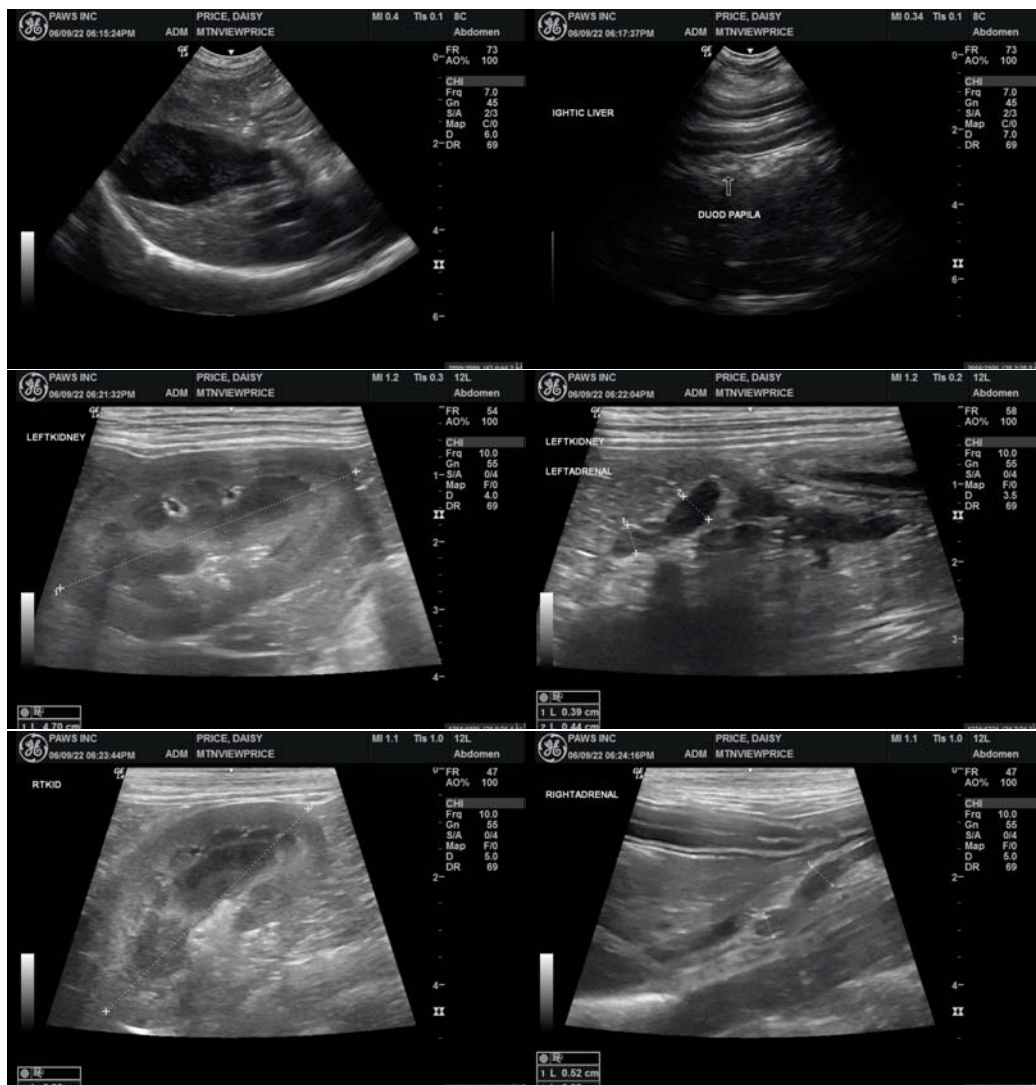
**INVOICE**

38604

**DATE**

6/10/22

If no cause for secondary polycythemia is found, then primary polycythemia would be suspected. I am not aware of a lab in the US that currently runs erythropoietin levels, but this could be further evaluated. Treatment for primary polycythemia hinges on reduction of the red blood cell count based on phlebotomy, or medications that cause myelosuppression. Hydroxyurea is commonly utilized and can be very variable on how well it is tolerated, as it can have significant side effects.





### PATIENT

Daisy Price

### SPECIES

Canine

### BREED

Cockapoo

### SEX

Spayed Female

### AGE

6 Years 2 Months

### WEIGHT

22.6 Pounds

### INTERPRETED BY

Kathleen Sennello DVM,  
MS, Diplomate ACVIM  
(Small Animal Internal  
Medicine)

### IMAGING BY

Loetitia Saint-Jacques,  
LVT

### HOSPITAL NAME

MountainView AH

### REFERRING VET

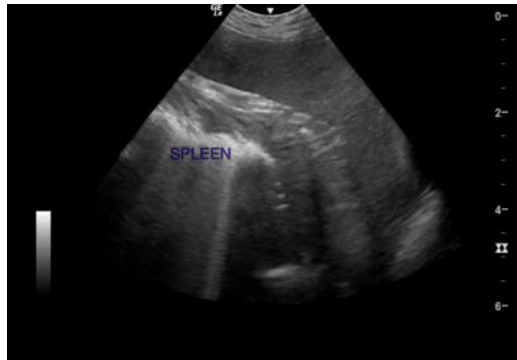
Dr. Sarah Kalivoda

### INVOICE

38604

### DATE

6/10/22



The information and recommendations provided are based on the images presented by the referring veterinarian/sonographer. No evaluation can be communicated regarding pathology that was not visible in the image/video clips provided.

Thank you for this referral. If the clinical or image interpretation does not parallel your findings or if I can be of any further assistance please contact me.

Kathleen Sennello DVM,MS, Diplomate ACVIM (Small animal Internal Medicine)  
kathleen.sennello@sonopath.com