



PATIENT

Oliver Curry

SPECIES

Canine

BREED

Toy Poodle

SEX

Neutered Male

AGE

11 Years 7 Months

WEIGHT

8.8 Pounds

INTERPRETED BY

Kathleen Sennello DVM,
MS, Diplomate ACVIM
(Small Animal Internal
Medicine)

**IMAGING
PERFORMED BY**

Kelly Vazquez

HOSPITAL NAME

Englewood Vet Center

REFERRING VET

Dr. Ezik

INVOICE

38175

DATE

6/1/22

PRESENTING CLINICAL SIGNS

Patient presents for extensive ecchymosis extending from the abdomen to the flanks. Had recently boarded at a kennel, picked up yesterday. Being treated with Vitamin K. BAR today. Abnormal PE/Chem/CBC/UA Results: ALT 335, PT 19.6 (H) / PTT 117.5 (H).

ULTRASONOGRAPHIC EXAMINATION OF THE ABDOMEN

Urinary System

The urinary bladder is moderately distended with anechoic urine. The Bladder wall, trigone, ureteral papillae and visible urethra (to a depth of 2cm) appear normal with no evidence of wall thickening, mucosal irregularities, masses or cystic calculi.

The prostate is normal in size (0.48 cm) and shape for this neutered male dog. The parenchyma is homogenous and the external margins are smooth. The prostatic urethra appears normal with no evidence of irregularity, invasion, mass effect or calculi.

The left kidney has a normal shape and size (3.68 cm). Overall echogenicity is normal with adequate corticomedullary distinction and a typical 1:3 cortex:medulla ratio. There is no evidence of perinephric inflammation or effusion. There is no evidence of pyelectasia, nephroliths, infarcts or hydroureter. Renal vasculature is normal.

The right kidney has a normal shape and size (3.58 cm). Overall echogenicity is normal with adequate corticomedullary distinction and a typical 1:3 cortex:medulla ratio. There is no evidence of perinephric inflammation or effusion. There is no evidence of pyelectasia, nephroliths, infarcts or hydroureter. Renal vasculature is normal.

Adrenal Glands

The left adrenal gland is normal in size measuring 0.47 cm at the caudal pole. It is observed in its normal position cranial to the left renal artery. It is normal in appearance (uniformly hypoechoic) and shape with no evidence of a mass effect.

The right adrenal gland is normal in size measuring 0.26 cm at the caudal pole. It is observed in its normal position between the cranial aspect of the right kidney and the caudal vena cava. It is normal in appearance (uniformly hypoechoic) and shape with no evidence of a mass effect.

Spleen

The spleen is subjectively normal in size. The spleen echotexture is heterogenous and mildly mottled, the splenic capsule is smooth with no irregularities. The blood flow through the hilus and splenic parenchyma appears normal. No focal parenchymal abnormalities are visualized.

Liver

The liver is subjectively normal in size, and echogenicity with smooth peripheral margins. The parenchyma is heterogenous in echotexture with subtle, indistinct focal mottling. The visible portions of the vasculature and biliary tract appear normal. No focal nodules or cystic lesions are observed.

The gall bladder lumen is moderately distended. The wall of the gall bladder is not thickened and has a smooth mucosal surface. There is a mild amount of non-organized echogenic debris. The cystic and common bile ducts are normal/not visible.



PATIENT

Gastrointestinal

Oliver Curry

The stomach contains minimal luminal contents. It measures at a normal thickness of <0.7cm with some variability due to the presence of rugal folds. The distinction of the gastric wall layers is adequate and there is no impression of reduced peristaltic activity. No masses or focal lesions were observed.

SPECIES

Canine

The visualized areas of duodenum, jejunum and ileum have a relatively uniform diameter with minimal fluid distension. Wall thickness is normal. Bowel loops follow a curvilinear path with distinct wall layering maintaining the typical 1:3 muscularis:mucosa layer ratio. The duodenum measured as normal (between 0.3-0.5cm in wall thickness) and the jejunum measured as normal (between 0.2-0.47cm.)

BREED

Toy Poodle

Visualized peristalsis appears appropriate. There were no focal lesions consistent with obstruction or a mass effect observed.

SEX

Neutered Male

The ileocecal junction was visualized and exhibited normal intact wall layering and is subjectively of normal thickness. Sections of colon are visualized with formed fecal material and gas shadowing distally. There is no observed focal or generalized colon wall thickening or loss of layering.

Pancreas

AGE

11 Years 7 Months

The pancreas is normal and isoechoic to surrounding mesentery. There is no evidence of nodules or cystic lesions. There is no evidence of regional mesenteric inflammation or fluid.

Free Abdomen

WEIGHT

8.8 Pounds

Evaluation of the peritoneal cavity did not reveal any evidence of effusion, or subjective lymphadenomegaly. The Medial iliac nodes appear normal and there was no evidence of a caudal aortic thrombus at the bifurcation. The omentum is of normal uniform echogenicity.

Other

INTERPRETED BY

Kathleen Sennello DVM,
MS, Diplomate ACVIM
(Small Animal Internal
Medicine)

A 0.47 cm hypoechoic, rounded lesion is visualized in the left cranial abdomen. Possible differentials include an omental cyst, pancreatic cyst, or hypoechoic lymph node.

ULTRASONOGRAPHIC FINDINGS

IMAGING PERFORMED BY

Kelly Vazquez

- Mildly mottled spleen – The diffuse splenic changes are non-specific and could be consistent with lymphoid hyperplasia, extramedullary hematopoiesis, infiltrative neoplasia, inflammation, other. Cytology or histopathology would be necessary to get a definitive diagnosis.
- Heterogeneous liver – The diffuse hepatic changes are non-specific and could be consistent with vacuolar hepatopathy, nodular hyperplasia, inflammatory/immune-mediated disease, fibrosis, extramedullary hematopoiesis, toxic hepatopathy (e.g., copper), infiltrative neoplasia (less likely) or other hepatopathy.
- Mild gallbladder – The significance of the aggregated gallbladder sludge is unclear. This could represent an early mucocele, cholestasis, or may be secondary to fasting.
- Hypoechoic, rounded structure visualized in the left cranial abdomen. This could very well be an incidental finding, but differentials would include an omental cyst, pancreatic cyst, lymph node, etc. A fine needle aspirate could be considered.

HOSPITAL NAME

Englewood Vet Center

REFERRING VET

Dr. Ezik

INVOICE

38175

DATE

6/1/22

INTERPRETATION OF THE FINDINGS & FURTHER RECOMMENDATIONS

Most of the lesions observed on today's scan are relatively subtle and non-specific. An obvious cause for the symptoms described is not visualized.



PATIENT

Oliver Curry

- Consider a coagulopathy including platelet count and function testing.
- Consider vasculitis.
- Consider a drug reaction causing a cutaneous erythema.
- Consider trauma (seems unlikely).

SPECIES

Canine

- Consider Rocky Mountain Spotted Fever and other infectious diseases that can cause skin lesions.

BREED

Toy Poodle

These cases can be very challenging, as there is often not an obvious source for the lesion observed. If there are any new medications, recommend discontinuing them. Consider consultation with a veterinary dermatologist (in person or take photos). A fine needle aspirate of the liver and spleen could be considered, primarily looking for round cell neoplasia, but this should only be done if coagulation parameters are normal.

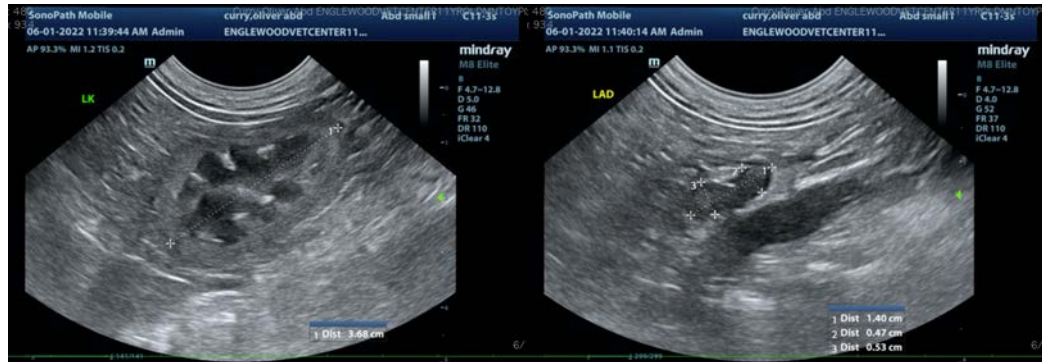
SEX

Neutered Male

Consider three view thoracic radiographs to rule out concurrent thoracic disease/involvement.

AGE

11 Years 7 Months

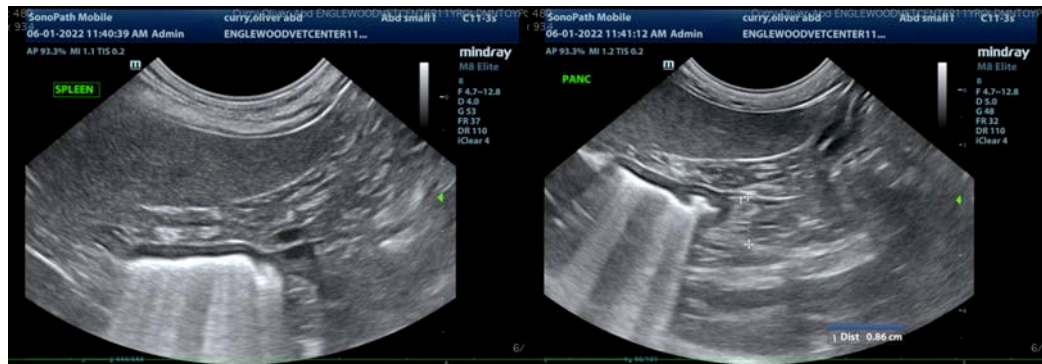


WEIGHT

8.8 Pounds

INTERPRETED BY

Kathleen Sennello DVM, MS, Diplomate ACVIM (Small Animal Internal Medicine)

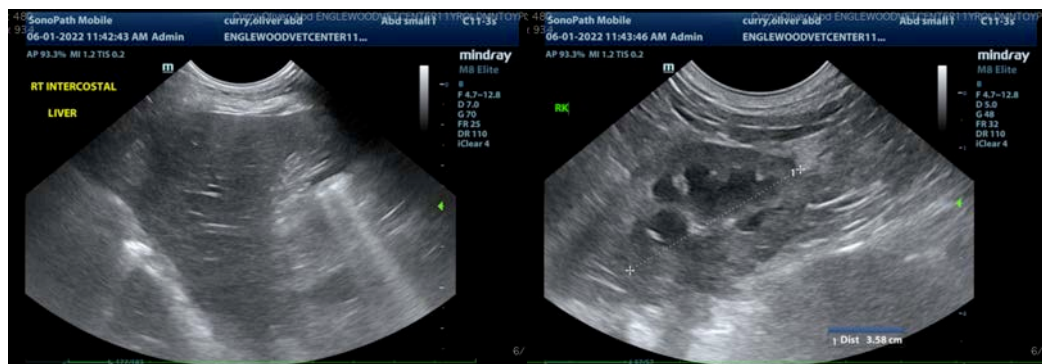


IMAGING PERFORMED BY

Kelly Vazquez

HOSPITAL NAME

Englewood Vet Center



REFERRING VET

Dr. Ezik

INVOICE

38175

DATE

6/1/22



PATIENT

Oliver Curry

SPECIES

Canine

BREED

Toy Poodle

SEX

Neutered Male

AGE

11 Years 7 Months

WEIGHT

8.8 Pounds

INTERPRETED BY

Kathleen Sennello DVM,
MS, Diplomate ACVIM
(Small Animal Internal
Medicine)

**IMAGING
PERFORMED BY**

Kelly Vazquez

HOSPITAL NAME

Englewood Vet Center

REFERRING VET

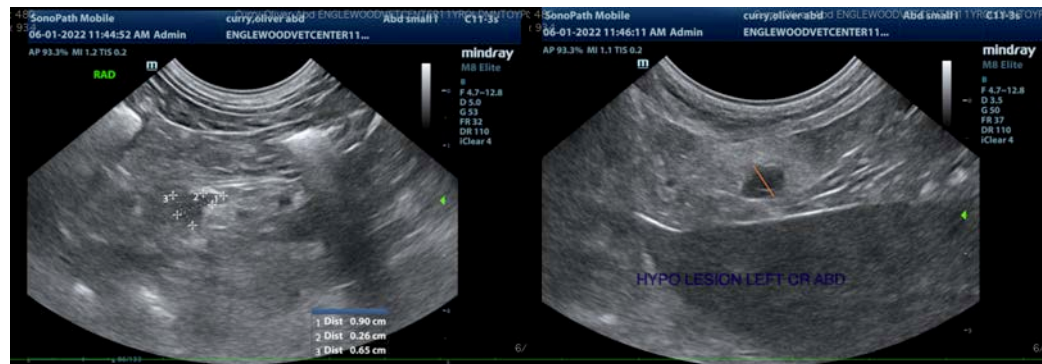
Dr. Ezik

INVOICE

38175

DATE

6/1/22



The information and recommendations provided are based on the images presented by the referring veterinarian/sonographer. No evaluation can be communicated regarding pathology that was not visible in the image/video clips provided.

Thank you for this referral. If the clinical or image interpretation does not parallel your findings or if I can be of any further assistance please contact me.

Kathleen Sennello DVM,MS, Diplomate ACVIM (Small animal Internal Medicine)

kathleen.sennello@sonopath.com