

**PATIENT PRESENTING CLINICAL SIGNS**

Jasper Smith Eating has decreased again. Started about 2 days ago. No vomiting Still eating, but very small amount. Not interested in wet food. Hiding more, less social Also decreased U/BM ASSESSMENT: Abdominal palpation WNL. P doesn't feel constipated Bladder is small, firm. Mod dental tartar. Hyporexia Weight loss--- Decreased from 5.6kg in April, 2022, to 5.1kg on May 28th  
Abnormal PE/Chem/CBC/UA Results: All bloodwork WNL

**SPECIES**

Feline

**ULTRASONOGRAPHIC EXAMINATION OF THE ABDOMEN**

**BREED**

DLH

**Urinary System**

The urinary bladder is moderately distended with anechoic urine. The Bladder wall, trigone, ureteral papillae and visible urethra (to a depth of 2cm) appear normal with no evidence of wall thickening, mucosal irregularities, masses or cystic calculi.

**SEX**

Neutered Male

The left kidney has a normal shape and size (4.35 cm). Overall echogenicity is normal with adequate corticomedullary distinction and a typical 1:3 cortex:medulla ratio. There is no evidence of perinephric inflammation or effusion. There is no evidence of pyelectasia, nephroliths, infarcts or hydroureter. Renal vasculature is normal.

**AGE**

7 Years

The right kidney has a normal shape and size (4.03 cm). Overall echogenicity is normal with adequate corticomedullary distinction and a typical 1:3 cortex:medulla ratio. There is no evidence of perinephric inflammation or effusion. There is no evidence of pyelectasia, nephroliths, infarcts or hydroureter. Renal vasculature is normal.

**WEIGHT**

5.1 kg

**Adrenal Glands**

The left adrenal gland is normal in size measuring 0.46 cm at the caudal pole. It is observed in its normal position cranial to the left renal artery. It is normal in appearance (uniformly hypoechoic) and shape with no evidence of a mass effect.

**INTERPRETED BY**

Kathleen Sennello DVM,  
MS, Diplomate ACVIM  
(Small Animal Internal  
Medicine)

The right adrenal gland is normal in size measuring 0.27 cm at the caudal pole. It is observed in its normal position between the cranial aspect of the right kidney and the caudal vena cava. It is normal in appearance (uniformly hypoechoic) and shape with no evidence of a mass effect.

**IMAGING PERFORMED BY**

Kelly Reschny

**Spleen**

The spleen is subjectively normal in size, echotexture is homogenous, and the splenic capsule is smooth with no irregularities. The blood flow through the hilus and splenic parenchyma appears normal. No focal parenchymal abnormalities are visualized.

**HOSPITAL NAME**

BPH Burlington

**Liver**

The liver is subjectively normal in size, and echogenicity with smooth peripheral margins. The parenchyma is homogenous echotexture. The visible portions of the vasculature and biliary tract appear normal. No focal nodules or cystic lesions are observed.

**REFERRING VET**

Dr. Ruggieri

**INVOICE**

38115

The gallbladder lumen is moderately distended. The wall of the gall bladder is not thickened and has a smooth mucosal surface. Luminal contents are primarily anechoic. The cystic and common bile ducts are normal/not visible.

**DATE**

6/1/22


**PATIENT** *Gastrointestinal*

Jasper Smith The stomach is mildly dilated with fluid and irregular shadowing material most consistent with normal ingesta and gas. It measures at a normal thickness of <0.36cm with some variability due to the presence of rugal folds. The distinction of the gastric wall layering is adequate and there is no impression of reduced peristaltic activity. No masses or focal lesions were observed.

**SPECIES**

Feline The visualized areas of duodenum, jejunum and ileum have a uniform diameter with minimal fluid distension. Wall thickness is normal to slightly increased. Bowel loops follow a typical curvilinear path with distinct wall layering, but some areas display a prominent muscularis layer which does not display the typical 1:3 muscularis:mucosa layer ratio. Jejunum wall measured 0.20 cm. Visualized peristalsis appears appropriate. There were no focal lesions consistent with obstruction or a mass effect observed.

**BREED**

DLH

**SEX**

Neutered Male

The ileocecal junction was visualized and exhibited normal intact wall layering and is subjectively of normal thickness. Sections of colon are visualized with formed fecal material and gas shadowing distally. There is no observed focal or generalized colon wall thickening or loss of layering.

**Pancreas**
**AGE**

7 Years

The pancreas is normal and isoechoic to surrounding mesentery. There is no evidence of nodules or cystic lesions. There is no evidence of regional mesenteric inflammation or fluid.

**Free Abdomen**
**WEIGHT**

5.1 kg

Evaluation of the peritoneal cavity did not reveal any evidence of effusion, or subjective lymphadenomegaly. The Medial iliac nodes appear normal and there was no evidence of a caudal aortic thrombus at the bifurcation. The omentum is of normal uniform echogenicity.

**ULTRASONOGRAPHIC FINDINGS**
**INTERPRETED BY**

 Kathleen Sennello DVM,  
 MS, Diplomate ACVIM  
 (Small Animal Internal  
 Medicine)

- Small amount of shadowing material within the gastric lumen – This could be consistent with normal ingesta. Recommend correlation with feeding history and abdominal radiographs. If the patient was adequately fasted, there could be some soft shadowing material such as hair, etc. in the stomach.
- Mildly prominent muscularis layer to the small intestine – The small intestinal wall changes are most consistent with an inflammatory process (i.e., inflammatory bowel disease) with a low possibility of emerging lymphoma.

**IMAGING PERFORMED BY**

Kelly Reschny

**HOSPITAL NAME**

BPH Burlington

**INTERPRETATION OF THE FINDINGS & FURTHER RECOMMENDATIONS**

The lesions observed on today's scan were very mild and could be within normal limits for this individual. If bloodwork is normal and metabolic disease is thought unlikely, then a primary gastrointestinal issue is possible. Consider such differentials as food allergy/dietary intolerance, GI parasitism, pancreatitis, IBD, and much less likely intestinal neoplasia.

**REFERRING VET**

Dr. Ruggieri

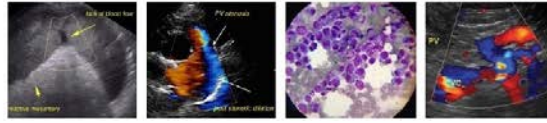
- Consider a novel protein/hydrolyzed protein prescription diet.
- Recommend empirical therapy for acute gastroenteritis/pancreatitis.
- Recommend the aforementioned GI panel.
- Correlate findings with thoracic and abdominal radiographs.
- If symptoms persist, consider obtaining GI biopsies.

**INVOICE**

38115

**DATE**

6/1/22



**PATIENT**

Jasper Smith

**SPECIES**

Feline

**BREED**

DLH

**SEX**

Neutered Male

**AGE**

7 Years

**WEIGHT**

5.1 kg

**INTERPRETED BY**

Kathleen Sennello DVM,  
MS, Diplomate ACVIM  
(Small Animal Internal  
Medicine)

**IMAGING  
PERFORMED BY**

Kelly Reschny

**HOSPITAL NAME**

BPH Burlington

**REFERRING VET**

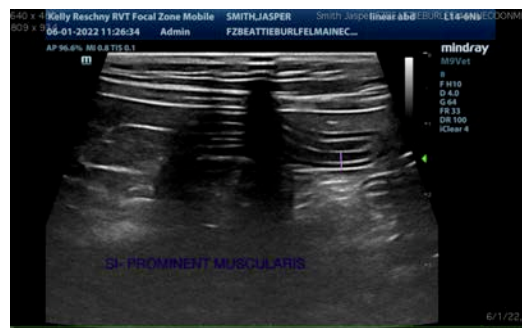
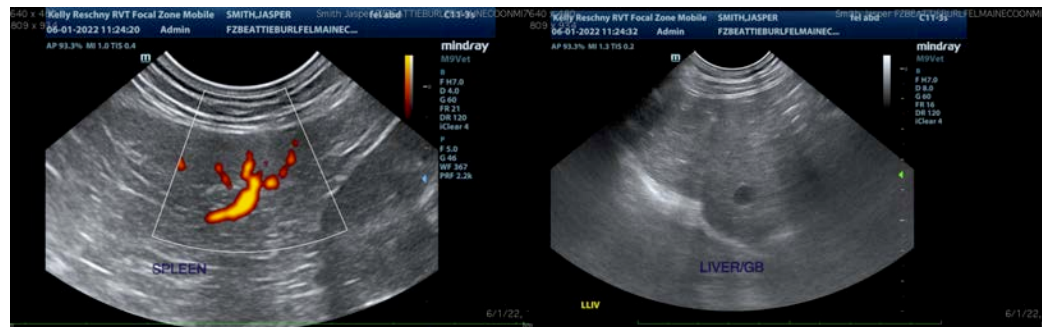
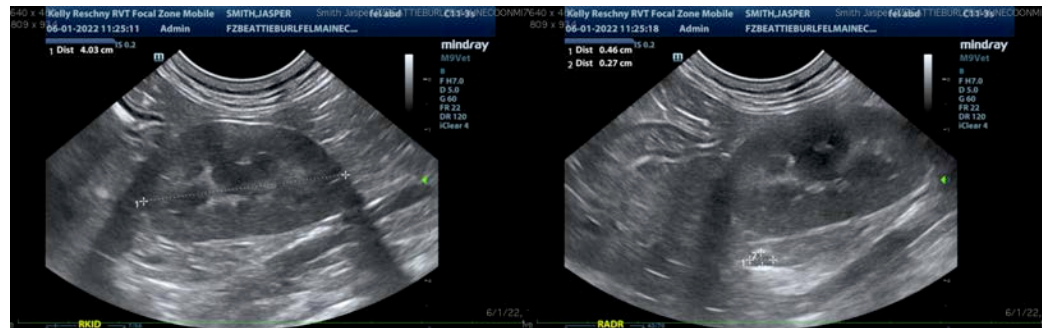
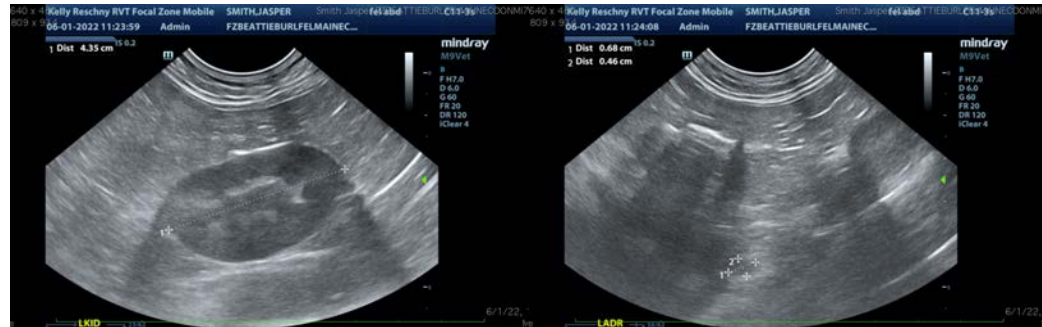
Dr. Ruggieri

**INVOICE**

38115

**DATE**

6/1/22



The information and recommendations provided are based on the images presented by the referring veterinarian/sonographer. No evaluation can be communicated regarding pathology that was not visible in the image/video clips provided.

Thank you for this referral. If the clinical or image interpretation does not parallel your findings or if I can be of any further assistance please contact me.

Kathleen Sennello DVM,MS, Diplomate ACVIM (Small animal Internal Medicine)

kathleen.sennello@sonopath.com