



PATIENT

Prince Reagor

SPECIES

Canine

BREED

Cavalier

SEX

Male

AGE

7 Years

WEIGHT

46 Pounds

INTERPRETED BY

Kathleen Sennello DVM,
MS, Diplomate ACVIM
(Small Animal Internal
Medicine)

**IMAGING
PERFORMED BY**

Dr. Elaina Petrone

HOSPITAL NAME

Long Branch AH

REFERRING VET

Dr. Elaina Petrone

INVOICE

47256

DATE

5/9/23

PRESENTING CLINICAL SIGNS

ALP, ALT, and platelets mildly elevated.

ULTRASONOGRAPHIC EXAMINATION OF THE ABDOMEN

Urinary System

The urinary bladder is moderately distended with anechoic urine. The Bladder wall, trigone, ureteral papillae and visible urethra (to a depth of 2cm) appear normal with no evidence of wall thickening, mucosal irregularities, masses or cystic calculi.

The visualized areas of prostate and surrounding tissue appear normal. Unfortunately, the prostate is not fully visualized likely due to its intrapelvic location. Correlate with rectal exam findings.

The left kidney has a normal shape and size (5.67 cm). Overall echogenicity is normal with adequate corticomedullary distinction and a typical 1:3 cortex:medulla ratio. There is no evidence of focal perinephric inflammation or effusion. There is no evidence of pyelectasia, nephroliths, infarcts or hydroureter. Renal vasculature is normal.

The right kidney has a normal shape and size (4.6 cm). Overall echogenicity is normal with adequate corticomedullary distinction and a typical 1:3 cortex:medulla ratio. There is no evidence of focal perinephric inflammation or effusion. There is no evidence of pyelectasia, nephroliths, infarcts or hydroureter. Renal vasculature is normal.

Adrenal Glands

The left adrenal gland is normal in size measuring 0.62 cm at the caudal pole. It is observed in its normal position cranial to the left renal artery. It is normal in appearance (uniformly hypoechoic) and shape with no evidence of a mass effect.

The right adrenal gland is normal in size measuring 0.64 cm at the caudal pole. It is observed in its normal position between the cranial aspect of the right kidney and the caudal vena cava. It is normal in appearance (uniformly hypoechoic) and shape with no evidence of a mass effect.

Spleen

The spleen is subjectively normal in size, echotexture is homogenous, and the splenic capsule is smooth with no irregularities. The blood flow through the hilus and splenic parenchyma appears normal. No focal parenchymal abnormalities are visualized.

Liver

The liver is subjectively normal in size, and echogenicity with smooth peripheral margins. The parenchyma is homogenous echotexture. The visible portions of the vasculature and biliary tract appear normal. No focal nodules or cystic lesions are observed.

The gallbladder lumen is moderately distended. The wall of the gall bladder is not thickened and has a smooth mucosal surface. Luminal contents are mild and primarily anechoic. The cystic and common bile ducts are normal/not visible.

Gastrointestinal

The stomach contains moderate shadowing ingesta. It measures at a normal thickness of 0.47 cm with some variability due to the presence of rugal folds. The distinction of the gastric wall layers is adequate and there is no impression of reduced peristaltic activity. No masses or focal lesions were observed.



PATIENT

Prince Reagor

SPECIES

Canine

BREED

Cavalier

SEX

Male

AGE

7 Years

WEIGHT

46 Pounds

INTERPRETED BY

Kathleen Sennello DVM,
MS, Diplomate ACVIM
(Small Animal Internal
Medicine)

IMAGING PERFORMED BY

Dr. Elaina Petrone

HOSPITAL NAME

Long Branch AH

REFERRING VET

Dr. Elaina Petrone

INVOICE

47256

DATE

5/9/23

The visualized areas of duodenum, jejunum and ileum have a relatively uniform diameter with minimal fluid distension. Wall thickness is normal. Bowel loops follow a curvilinear path with distinct wall layering maintaining the typical 1:3 muscularis:mucosa layer ratio. Duodenum wall measures 0.57 cm. Jejunum wall measures 0.39 cm. Visualized peristalsis appears appropriate. There were no focal lesions consistent with obstruction or a mass effect observed.

The ileocecal junction was visualized and exhibited normal intact wall layering and is subjectively of normal thickness. Sections of colon are visualized with formed fecal material and gas shadowing distally. There is no observed focal or generalized colon wall thickening or loss of layering.

Pancreas

The area of the pancreas is normal and isoechoic to surrounding mesentery. There is no evidence of nodules or cystic lesions. There is no evidence of regional mesenteric inflammation or fluid.

Free Abdomen

Evaluation of the peritoneal cavity did not reveal any evidence of effusion, or subjective lymphadenomegaly. The Medial iliac nodes appear normal and there was no evidence of a caudal aortic thrombus at the bifurcation. The omentum is of normal uniform echogenicity.

ULTRASONOGRAPHIC FINDINGS

- Moderate shadowing debris visualized within the gastric lumen – Correlate with the feeding history and abdominal radiographs. If the patient was adequately fasted consider such differentials as delayed gastric emptying, a partial outflow tract obstruction (none seen) or ingested foreign material.

INTERPRETATION OF THE FINDINGS & FURTHER RECOMMENDATIONS

Today's scan appears relatively normal. No focal lesions are visualized associated with the liver, and no biliary disease is observed. Findings are most consistent with a primary hepatopathy. Recommendations will vary depending on the severity of the liver enzyme elevation and the ratio of ALT to ALP, but here are some general recommendations to consider:

- Consider close evaluation of history for possible toxic changes examine medications, diet, dietary indiscretion etc...
- Consider PCR on urine/serum for leptospirosis (if not on antibiotics)/serology if recent antibiotic history
- If not already done, consider pre and post prandial bile acids to evaluate liver function
- If the ALP is significantly elevated relative to the ALT and symptoms consistent with Cushing's are present, consider adrenal function testing (ACTH stim)
- Consider Fine needle aspirate if round cell neoplasia is on your differentia list (25 g needle, normal coags)
- If no response to supportive care (Denamarin, fluids, antibiotics, +/- ursodiol etc.) Consider liver biopsy with samples obtained for histopathology, culture, and copper levels.



PATIENT

Prince Reagor

SPECIES

Canine

BREED

Cavalier

SEX

Male

AGE

7 Years

WEIGHT

46 Pounds

INTERPRETED BY

Kathleen Sennello DVM,
MS, Diplomate ACVIM
(Small Animal Internal
Medicine)

IMAGING PERFORMED BY

Dr. Elaina Petrone

HOSPITAL NAME

Long Branch AH

REFERRING VET

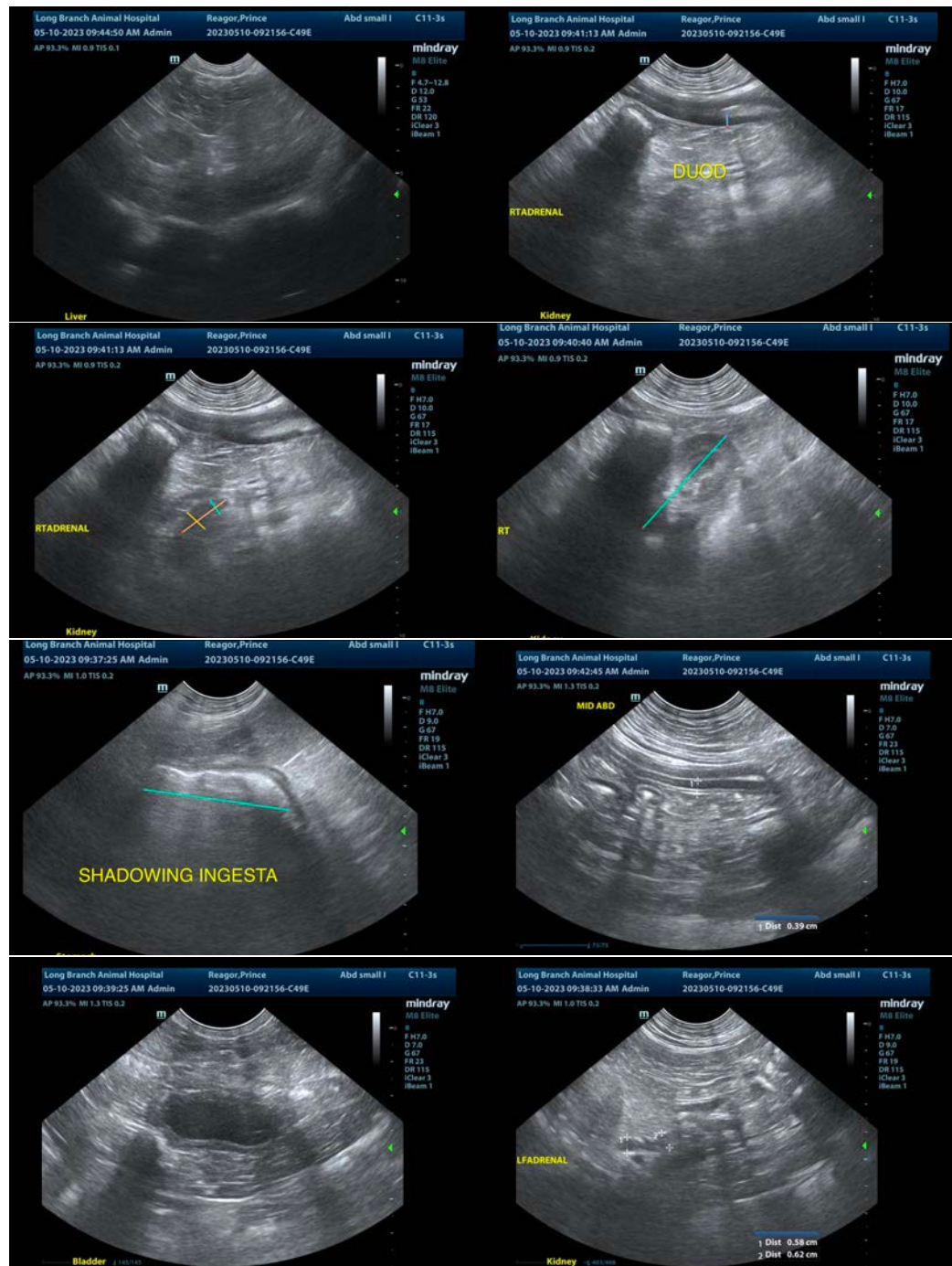
Dr. Elaina Petrone

INVOICE

47256

DATE

5/9/23





PATIENT

Prince Reagor

SPECIES

Canine

BREED

Cavalier

SEX

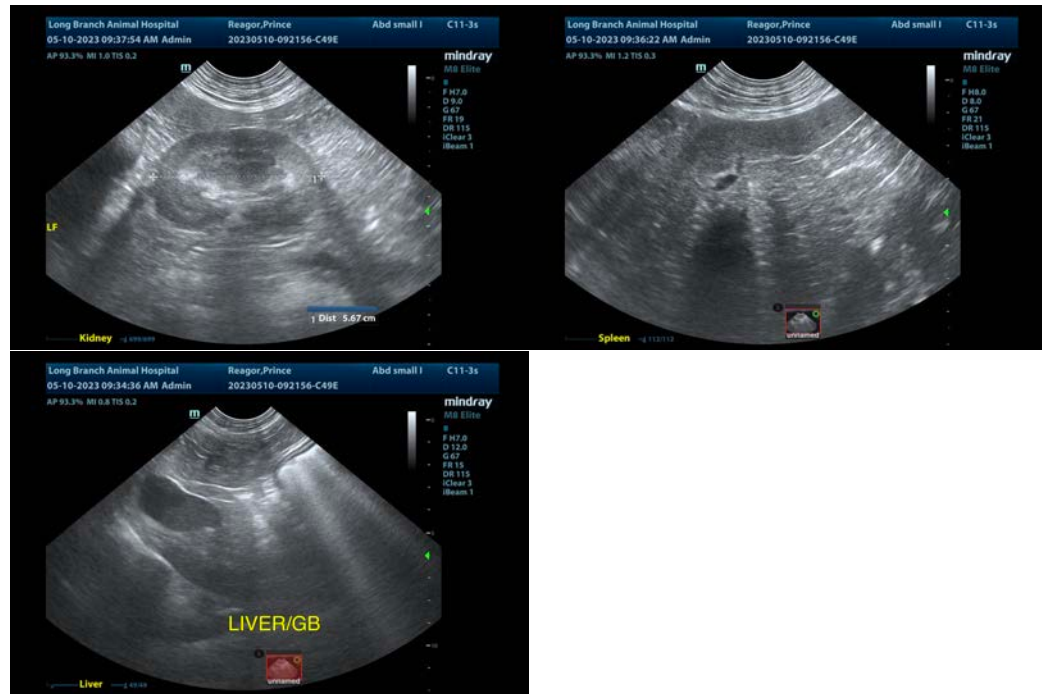
Male

AGE

7 Years

WEIGHT

46 Pounds



INTERPRETED BY

Kathleen Sennello DVM,
MS, Diplomate ACVIM
(Small Animal Internal
Medicine)

The information and recommendations provided are based on the images presented by the referring veterinarian/sonographer. No evaluation can be communicated regarding pathology that was not visible in the image/video clips provided.

Thank you for this referral. If the clinical or image interpretation does not parallel your findings or if I can be of any further assistance please contact me.

IMAGING PERFORMED BY

Dr. Elaina Petrone

Kathleen Sennello DVM,MS, Diplomate ACVIM (Small animal Internal Medicine)

kathleen.sennello@sonopath.com

HOSPITAL NAME

Long Branch AH

REFERRING VET

Dr. Elaina Petrone

INVOICE

47256

DATE

5/9/23