

**DATE PRESENTING CLINICAL SIGNS**

5/9/23

Was here yesterday for lethargy and seeming painful- r/o was back vs belly treated outpatient still lethargic, still not eating or drinking started having diarrhea overnight- now bloody discharge other dog in the house is being treated for UTI; not aware of getting into anything no change in diet/ no new treats

**PATIENT**

Piper Kitler

Current Medications: ondanestron, gabapentin sent home- currently getting buprenorphine, maropitant, metronidazole

**SPECIES**

Canine

Lab Results: WNL.

Radiographs: NSF.

Date of Previous IntraPet Ultrasound: No previous.

Sedation: Not required to complete full diagnostic ultrasound.

Stat Report: Not requested.

**BREED**

Dachshund

Imaging Performed By: Rachel Brillhart, RDMS.

**ULTRASONOGRAPHIC EXAMINATION OF THE ABDOMEN****SEX**

Spayed Female

**Urinary System**

The urinary bladder is moderately distended with anechoic urine. The Bladder wall, trigone, ureteral papillae and visible urethra (to a depth of 2cm) appear normal with no evidence of wall thickening, mucosal irregularities, masses or cystic calculi.

**AGE**

5/7/20

The left kidney has a normal shape and size (4.13 cm). Overall echogenicity is normal with adequate corticomedullary distinction and a typical 1:3 cortex:medulla ratio. There is no evidence of focal perinephric inflammation or effusion. There is no evidence of pyelectasia, nephroliths, infarcts or hydroureter. Renal vasculature is normal.

**WEIGHT**

14.6 Pounds

The right kidney has a normal shape and size (4.09 cm). Overall echogenicity is normal with adequate corticomedullary distinction and a typical 1:3 cortex:medulla ratio. There is no evidence of focal perinephric inflammation or effusion. There is no evidence of pyelectasia, nephroliths, infarcts or hydroureter. Renal vasculature is normal.

**INTERPRETED BY**Eric Lindquist, DMV  
DABVP, Cert. IVUSS**HOSPITAL NAME**Animal Emergency  
Hospital**Adrenal Glands**

The left adrenal gland is normal in size measuring 0.53 cm at the caudal pole. It is observed in its normal position cranial to the left renal artery. It is normal in appearance (uniformly hypoechoic) and shape with no evidence of a mass effect.

**REFERRING VET**

Dr. Willer

The right adrenal gland is normal in size measuring 0.55 cm at the caudal pole. It is observed in its normal position between the cranial aspect of the right kidney and the caudal vena cava. It is normal in appearance (uniformly hypoechoic) and shape with no evidence of a mass effect.

**INVOICE**

47235

**Spleen**

The spleen is subjectively normal in size, echotexture is homogenous, and the splenic capsule is smooth with no irregularities. The blood flow through the hilus and splenic parenchyma appears normal. No focal parenchymal abnormalities are visualized.

**Liver**

The liver is subjectively normal in size, and echogenicity with smooth peripheral margins. The parenchyma is homogenous echotexture. The visible portions of the vasculature and biliary tract appear normal. No focal nodules or cystic lesions are observed.

The gallbladder lumen is moderately distended. The wall of the gall bladder is not thickened and has a smooth mucosal surface. Luminal contents are mild and primarily anechoic. The cystic and common bile ducts are normal/not visible.

### ***Gastrointestinal***

The stomach contains moderate fluid. It measures at a normal thickness of <0.7cm with some variability due to the presence of rugal folds. The distinction of the gastric wall layers is adequate and there is no impression of reduced peristaltic activity. No masses or focal lesions were observed.

The visualized areas of duodenum, jejunum and ileum have a relatively uniform diameter with mild fluid distension. Wall thickness is normal. Bowel loops follow a curvilinear path with distinct wall layering maintaining the typical 1:3 muscularis:mucosa layer ratio. Duodenum wall measures 0.29 cm. Jejunum wall measures 0.23 cm. Visualized peristalsis appears appropriate. There were no focal lesions consistent with obstruction or a mass effect observed.

The ileocecal junction was visualized and exhibited normal intact wall layering and is subjectively of normal thickness. Sections of colon are visualized with formed fecal material and gas shadowing distally. There is no observed focal or generalized colon wall thickening or loss of layering.

### ***Pancreas***

The pancreas is normal and isoechoic to surrounding mesentery. There is no evidence of nodules or cystic lesions. There is no evidence of regional mesenteric inflammation or fluid.

### ***Free Abdomen***

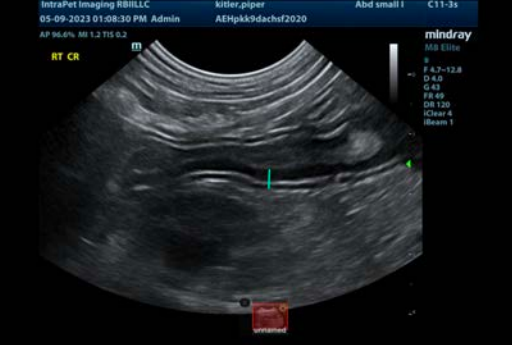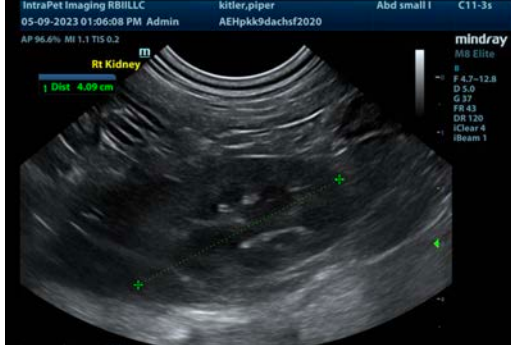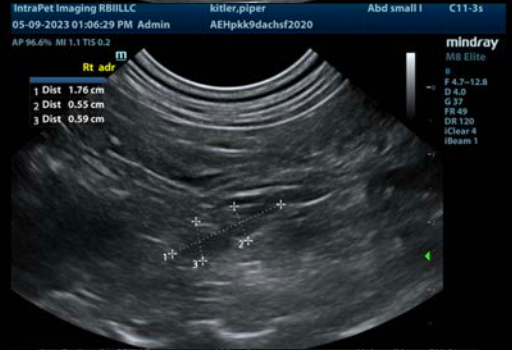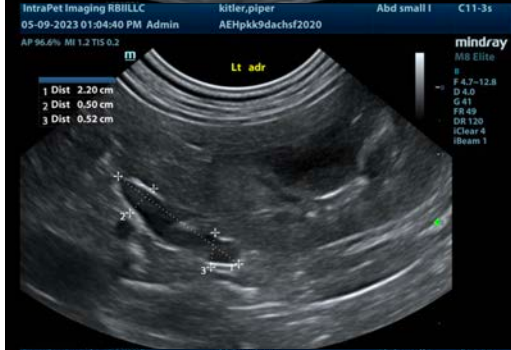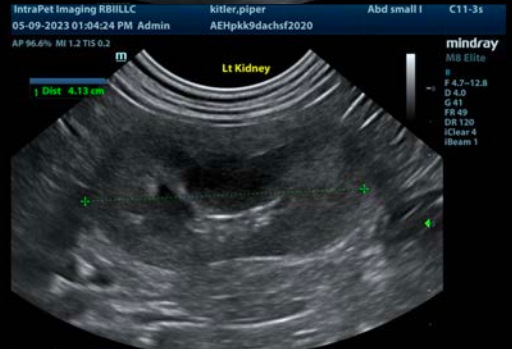
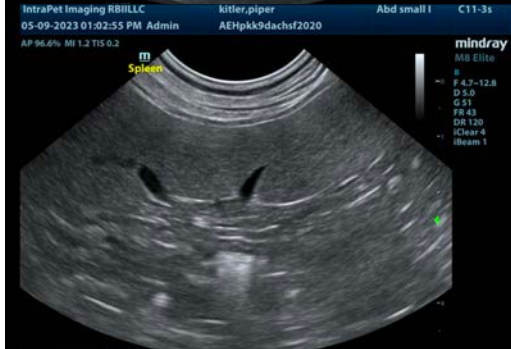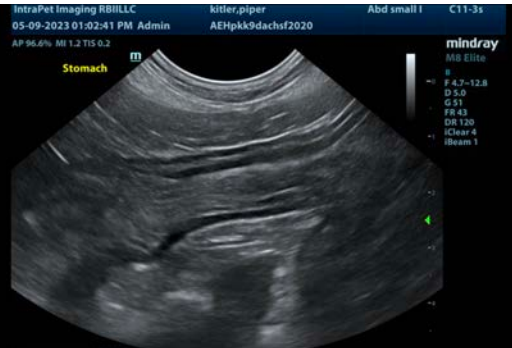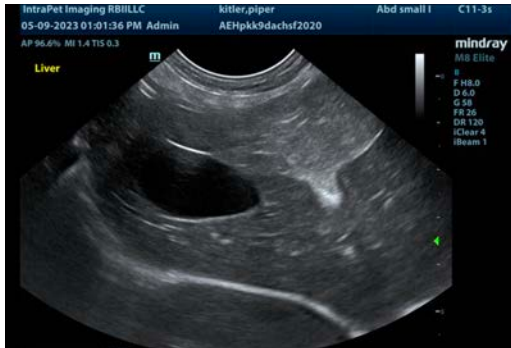Evaluation of the peritoneal cavity did not reveal any evidence of effusion, or subjective lymphadenomegaly. The Medial iliac nodes appear normal and there was no evidence of a caudal aortic thrombus at the bifurcation. The omentum is of normal uniform echogenicity.

## **ULTRASONOGRAPHIC FINDINGS**

- Mild fluid distention of the gastric lumen – This is very mild and the significance is unclear. No evidence of obstruction is visualized. Consider mild ileus.

## **INTERPRETATION OF THE FINDINGS & FURTHER RECOMMENDATIONS**

No significant abnormalities were noted on today's scan to explain the abdominal pain, anorexia, and diarrhea reported. Based on the active GI signs, it seems like this discomfort would be most likely to be arising from the abdomen, but no focal lesions are visualized. Subjectively, there may be some mildly hyperechoic mesentery in the right cranial abdomen, but no evidence of an actively inflamed pancreas is observed. Correlate these findings with a quantitative cPLI level, as sometimes pancreatitis cannot be readily identified. Consider empirical treatment for pancreatitis and close continued monitoring. If symptoms are persisting, recommend repeat imaging (radiographs +/- ultrasound). Consider the possibility of an HGE episode.



**The information and recommendations provided are based on the images presented by the referring veterinarian/sonographer. No evaluation can be communicated regarding pathology that was not visible in the image/video clips provided.**

Thank you for this referral. If the clinical or image interpretation does not parallel your findings or if I can be of any further assistance please contact me.

Kathleen Sennello DVM,MS, Diplomate ACVIM (Small animal Internal Medicine)  
kathleen.sennello@sonopath.com