

**DATE PRESENTING CLINICAL SIGNS**

5/9/23

PC: hematuria / blood in urine. Breathing quickly. History: 5/8/23: Did not eat at all yesterday vomited last night increased effort when breathing last night- worse this morning noticed blood or brown coloration to the urine no prior health issues no exposure to rat poison is walked in the owner's yard and owners are with dog coughing/gagging after vomiting no s no diarrhea.

PATIENT

Lexi Grauling

Current Medications: Cerenia, Dexamethasone.

Lab Results: See attached.

SPECIES

Canine

Radiographs: big liver and spleen no significant pulmonary changes no visible stones

Date of Previous IntraPet Ultrasound: No previous.

Sedation: Not required to complete full diagnostic ultrasound.

Stat Report: Not requested.

BREED

Pomeranian

Imaging Performed By: Rachel Brillhart, RDMS.

ULTRASONOGRAPHIC EXAMINATION OF THE ABDOMEN**SEX**

Spayed Female

Urinary System

The urinary bladder is moderately distended with anechoic urine. The Bladder wall, trigone, ureteral papillae and visible urethra (to a depth of 2cm) appear normal with no evidence of wall thickening, mucosal irregularities, masses or cystic calculi.

AGE

5/10/18

The left kidney has a normal shape and size (4.18 cm). Overall echogenicity is normal with adequate corticomedullary distinction and a typical 1:3 cortex:medulla ratio. There is no evidence of focal perinephric inflammation or effusion. There is no evidence of pyelectasia, nephroliths, infarcts or hydroureter. Renal vasculature is normal.

WEIGHT

7.2 Pounds

The right kidney has a normal shape and size (3.98 cm). Overall echogenicity is normal with adequate corticomedullary distinction and a typical 1:3 cortex:medulla ratio. There is no evidence of focal perinephric inflammation or effusion. There is no evidence of pyelectasia, nephroliths, infarcts or hydroureter. Renal vasculature is normal.

INTERPRETED BY

Kathleen Sennello DVM,
MS, Diplomate ACVIM
(Small Animal Internal
Medicine)

Adrenal Glands

The left adrenal gland is normal in size measuring 0.60 cm at the caudal pole. It is observed in its normal position cranial to the left renal artery. It is normal in appearance (uniformly hypoechoic) and shape with no evidence of a mass effect.

HOSPITAL NAME

Animal Emergency
Hospital

The right adrenal gland is normal in size measuring 0.65 cm at the caudal pole. It is observed in its normal position between the cranial aspect of the right kidney and the caudal vena cava. It is normal in appearance (uniformly hypoechoic) and shape with no evidence of a mass effect.

REFERRING VET

Dr. Willer

Spleen

The spleen is subjectively normal in size, echotexture is homogenous, and the splenic capsule is smooth with no irregularities. The blood flow through the hilus and splenic parenchyma appears normal. No focal parenchymal abnormalities are visualized.

INVOICE

47233

Liver

The liver is large in size, and normal in echogenicity with smooth peripheral margins. The parenchyma is heterogenous in echotexture with subtle, indistinct focal mottling. The visible portions of the vasculature and biliary tract appear normal. No focal nodules or cystic lesions are observed.

The gall bladder lumen is moderately distended. The wall of the gall bladder is not thickened and has a smooth mucosal surface. There is a moderate amount of non-organized echogenic debris. The cystic and common bile ducts are normal/not visible.

Gastrointestinal

The stomach contains minimal luminal contents. It measures at a normal thickness of <0.7cm with some variability due to the presence of rugal folds. The distinction of the gastric wall layers is adequate and there is no impression of reduced peristaltic activity. No masses or focal lesions were observed.

The visualized areas of duodenum, jejunum and ileum have a relatively uniform diameter with minimal fluid distension. Wall thickness is normal. Bowel loops follow a curvilinear path with distinct wall layering maintaining the typical 1:3 muscularis:mucosa layer ratio. Duodenum wall measures 0.38 cm. Jejunum wall measures 0.24 cm. Visualized peristalsis appears appropriate. There were no focal lesions consistent with obstruction or a mass effect observed.

The ileocecal junction was visualized and exhibited normal intact wall layering and is subjectively of normal thickness. Sections of colon are visualized with formed fecal material and gas shadowing distally. There is no observed focal or generalized colon wall thickening or loss of layering.

Pancreas

The pancreas is normal and isoechoic to surrounding mesentery. There is no evidence of nodules or cystic lesions. There is no evidence of regional mesenteric inflammation or fluid.

Free Abdomen

Evaluation of the peritoneal cavity did not reveal any evidence of effusion, or subjective lymphadenomegaly. The Medial iliac nodes appear normal and there was no evidence of a caudal aortic thrombus at the bifurcation. The omentum is of normal uniform echogenicity.

Other

Ringdown artifact is seen at the level of the diaphragm. These findings can be seen with pulmonary parenchymal disease. Recommend 3-view thoracic radiographs (I believe these were normal).

PRIMARY FINDINGS

- Large, mildly heterogeneous liver – The diffuse hepatic changes are non-specific and could be consistent with vacuolar hepatopathy, nodular hyperplasia, inflammatory/immune-mediated disease, fibrosis, extramedullary hematopoiesis, toxic hepatopathy (e.g., copper), infiltrative neoplasia (less likely) or other hepatopathy.
- Moderate gallbladder debris – The significance of the aggregated gallbladder debris is unclear. This could represent an early mucocele, cholestasis, or may be secondary to fasting but seems unlikely to be causing a current issue. Recommend continued monitoring.

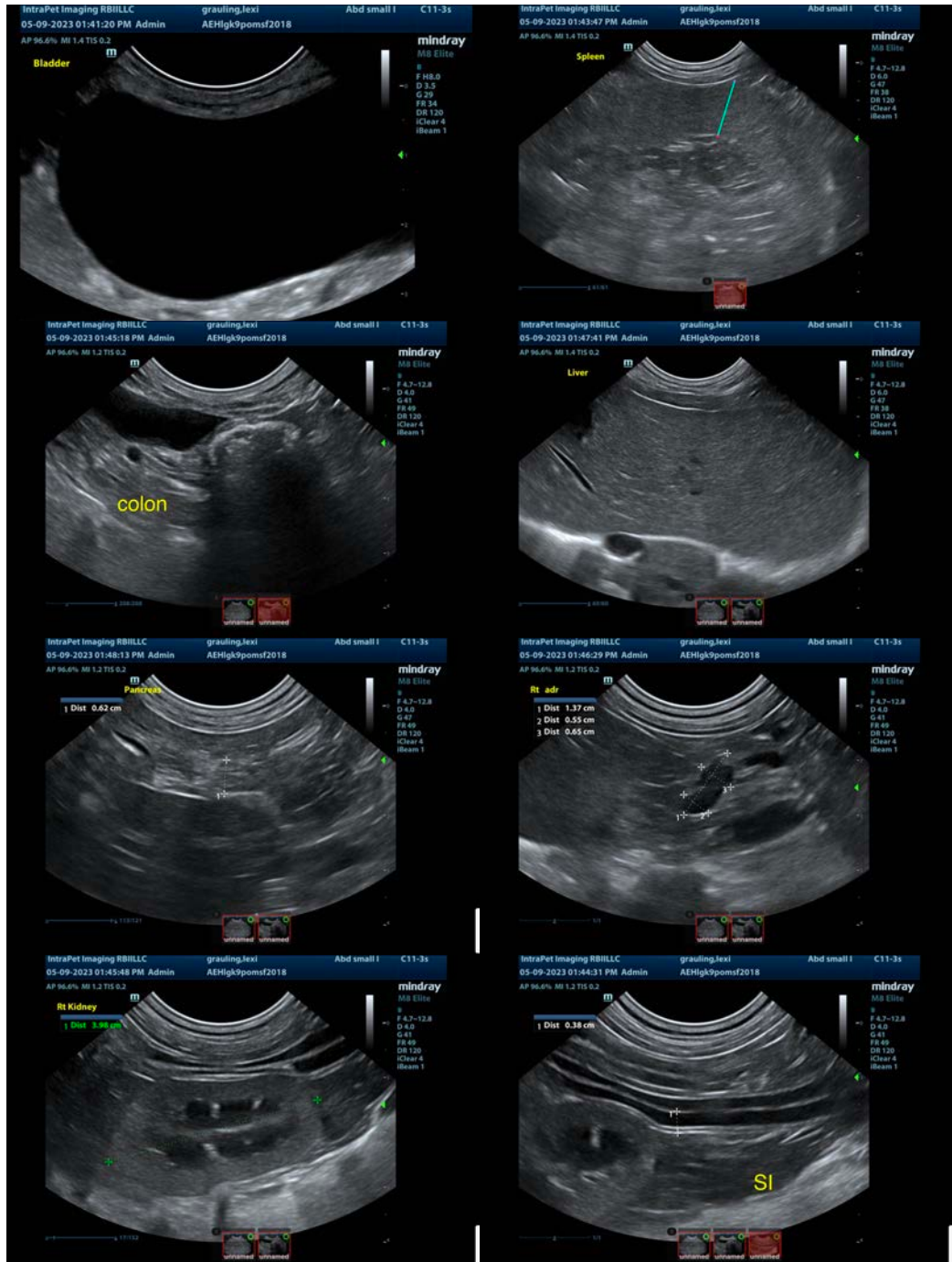
SECONDARY FINDINGS

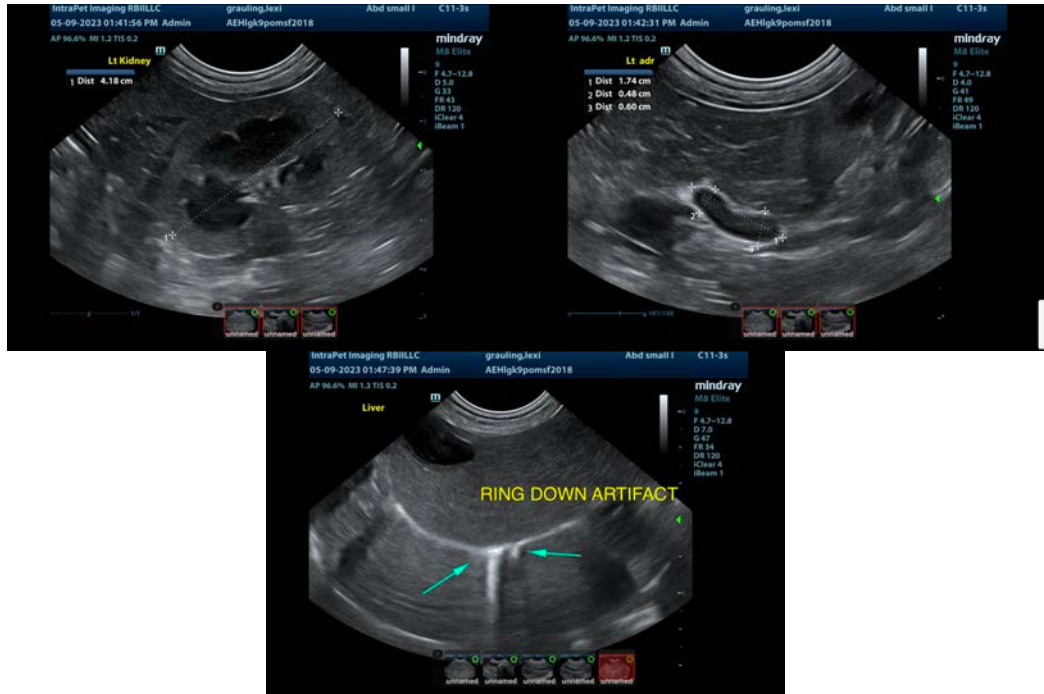
- Ringdown artifact at the diaphragm – Can be seen with pulmonary parenchymal disease – Recommend 3-view thoracic radiographs (if not already done).

INTERPRETATION OF THE FINDINGS & FURTHER RECOMMENDATIONS

The changes observed on today's scan were mild and non-specific. No focal mass effects were visualized, and no obvious source or association with the anemia is seen.

Based on the history provided, a hemolytic anemia seems likely. Consider the possibility of any drugs or toxins that could cause hemolysis, any infectious diseases such as babesia, but immune mediated hemolytic anemia is the most commonly seen differential. Correlate this with your clinical picture, exam finding, etc. If autoimmune disease is thought likely, recommend immunosuppressive doses of steroids (2 mg/kg per day), and if needed, an additional immunosuppressant +/- platelet inhibitor.





The information and recommendations provided are based on the images presented by the referring veterinarian/sonographer. No evaluation can be communicated regarding pathology that was not visible in the image/video clips provided.

Thank you for this referral. If the clinical or image interpretation does not parallel your findings or if I can be of any further assistance please contact me.

Kathleen Sennello DVM,MS, Diplomate ACVIM (Small animal Internal Medicine)
kathleen.sennello@sonopath.com