



PATIENT

Tootie McConnell

SPECIES

Feline

BREED

DSH

SEX

Neutered Male

AGE

15 Years

WEIGHT

13.5 lbs

INTERPRETED BY

Kathleen Sennello
DVM, MS, Diplomate
ACVIM (Small animal
Internal Medicine)

IMAGING PERFORMED BY

Dr. Mary Pearce

HOSPITAL NAME

Chambersburg Animal
Hospital

REFERRING VET

Dr. Mary Pearce

INVOICE

14945

DATE

05/08/26

PRESENTING CLINICAL SIGNS

4/8/26 presented for vomiting and diarrhea. Hx chronic vomiter but recently worsened. About 2lb weight loss over the last 2 years. BW performed found elevated liver values, o declined additional recommended diagnostics at that time including radiographs/ultrasound. Treatments recommended including Denamarin, Cerenia, o declined. Since that visit p has improved and vomiting/diarrhea resolved, clinically is doing well. O elected to pursue ultrasound today.

Abnormal PE/Chem/CBC/UA Results: 5/8/26: Glob 5.4, ALT 381, ALP 156, GGT 9, tbili normal 0.2. 4/9/26: HCT 38.6%, WBC normal, PLT 666 (H). SDMA 15 (0-14), BUN/creat normal, K 5.9, Na:K 25, ALT 422, AST 80, ALP 117, GGT 3 (normal). TT4 2.0.

ULTRASONOGRAPHIC EXAMINATION OF THE ABDOMEN

Urinary System

The urinary bladder is moderately distended with anechoic urine. The bladder wall, trigone, ureteral papillae and visible urethra (to a depth of 2.0 cm) appear normal with no evidence of wall thickening, mucosal irregularities, masses or cystic calculi.

The left kidney has a normal shape and size (4.07 cm). Overall echogenicity is normal with adequate corticomedullary distinction and a typical 1:3 cortex:medulla ratio. There is no evidence of perinephric inflammation or effusion. There is no evidence of pyelectasia, nephroliths, infarcts or hydroureter. Renal vasculature is normal.

The right kidney has a normal shape and size (4.25 cm). Overall echogenicity is normal with adequate corticomedullary distinction and a typical 1:3 cortex:medulla ratio. There is no evidence of perinephric inflammation or effusion. There is no evidence of pyelectasia, nephroliths, infarcts or hydroureter. Renal vasculature is normal.

Adrenal Glands

The left adrenal gland is normal in size. It is observed in its normal position cranial to the left renal artery. It is normal in appearance (uniformly hypoechoic) and shape with no evidence of a mass effect.

The right adrenal gland is normal in size measuring 0.37 cm width. It is observed in its normal position between the cranial aspect of the right kidney and the caudal vena cava. It is normal in appearance (uniformly hypoechoic) and shape with no evidence of a mass effect.

Spleen

The spleen is subjectively normal in size, echotexture is homogenous, and the splenic capsule is smooth with no irregularities. The blood flow through the hilus and splenic parenchyma appears normal. The spleen measured 0.90 cm. A mixed echogenicity splenic mass is suspected. *See description of mid abdominal mass lesion/splenic mass under other.

Liver

The liver is subjectively normal in size, and echogenicity with smooth peripheral margins. The parenchyma is homogenous echotexture. The visible portions of the vasculature and biliary tract appear normal. There is a cystic appearing lesion visualized just dorsal to the gallbladder measuring 2.16 cm x 2.45 cm. Additionally, there is a poorly defined subtle hypoechoic nodule on the left side measuring 0.77 cm.



PATIENT

Tootie McConnell

SPECIES

Feline

BREED

DSH

SEX

Neutered Male

AGE

15 Years

WEIGHT

13.5 lbs

INTERPRETED BY

Kathleen Sennello
DVM, MS, Diplomate
ACVIM (Small animal
Internal Medicine)

IMAGING PERFORMED BY

Dr. Mary Pearce

HOSPITAL NAME

Chambersburg Animal
Hospital

REFERRING VET

Dr. Mary Pearce

INVOICE

14945

DATE

05/08/26

The gall bladder lumen is moderately distended. The wall of the gall bladder is not thickened and has a smooth mucosal surface. Luminal contents are primarily anechoic. The cystic and common bile ducts are normal/not visible. An association with the gall bladder and cystic lesion is possible but two separate structures are suspected.

Gastrointestinal

The stomach contains minimal luminal contents. It measures at a normal thickness of <0.7 cm with some variability due to the presence of rugal folds. The distinction of the gastric wall layers is adequate and there is no impression of reduced peristaltic activity. No masses or focal lesions were observed.

Most areas of duodenum, jejunum and ileum have a uniform diameter with minimal fluid distension. Wall thickness is normal to slightly increased. Bowel loops follow a typical curvilinear path with distinct wall layering, but some areas display a prominent muscularis layer which does not display the typical 1:3 muscularis:mucosa layer ratio. The duodenum measured 0.36 cm in diameter and the jejunum measured 0.26 cm in diameter. Visualized peristalsis appears appropriate. The ileum wall measures 0.44 cm. There is a hypoechoic structure visualized in the right cranial abdomen concerning for a possible focal bowel mass lesion measuring approximately 1.61 cm x 3.22 cm. This is concerning for a possible duodenal mass lesion or overlapping segment of bowel.

The ileocecal junction was visualized and exhibited normal intact wall layering and is subjectively of normal thickness. Sections of colon are visualized with formed fecal material and gas shadowing distally. There is no observed focal or generalized colon wall thickening or loss of layering.

Pancreas

The area of the pancreas is normal and isoechoic to surrounding mesentery. There is no evidence of nodules or cystic lesions. There is no evidence of regional mesenteric inflammation or fluid.

Free Abdomen

Evaluation of the peritoneal cavity did not reveal any evidence of effusion, or subjective lymphadenomegaly. The omentum is of normal uniform echogenicity.

Other

There's a large irregular mixed echogenicity/partially cystic mass effect visualized in mid-abdomen measuring 6.56 cm x 3.76 cm. A definitive vascular attachment/organ of origin is not clear, although a splenic lesion is suspected due to the proximity and association with these structures.

ULTRASONOGRAPHIC FINDINGS

- Large irregular cystic lesion visualized near the gallbladder- findings are most consistent with a hepatic cyst, and association with the gallbladder/biliary tract cannot be definitively ruled out.
- Diffusely thickened small intestine with prominent muscularis layer- The small intestinal wall changes are most consistent with an inflammatory process (i.e., inflammatory bowel disease) with a low possibility of emerging lymphoma.



PATIENT

Tootie McConnell

SPECIES

Feline

BREED

DSH

SEX

Neutered Male

AGE

15 Years

WEIGHT

13.5 lbs

INTERPRETED BY

Kathleen Sennello
DVM, MS, Diplomate
ACVIM (Small animal
Internal Medicine)

IMAGING PERFORMED BY

Dr. Mary Pearce

HOSPITAL NAME

Chambersburg Animal
Hospital

REFERRING VET

Dr. Mary Pearce

INVOICE

14945

DATE

05/08/26

- Focal hypoechoic mass effect in the right cranial abdomen- the appearance is concerning for possible cranial abdominal bowel mass/duodenal mass/thickening. No evidence of an obstruction is visualized.
- Large mixed echogenicity mid abdominal mass lesion- primary differential is a splenic mass lesion, although an association with the liver, pancreas or a large lymph node cannot be definitively ruled out.

INTERPRETATION OF THE FINDINGS & FURTHER RECOMMENDATIONS

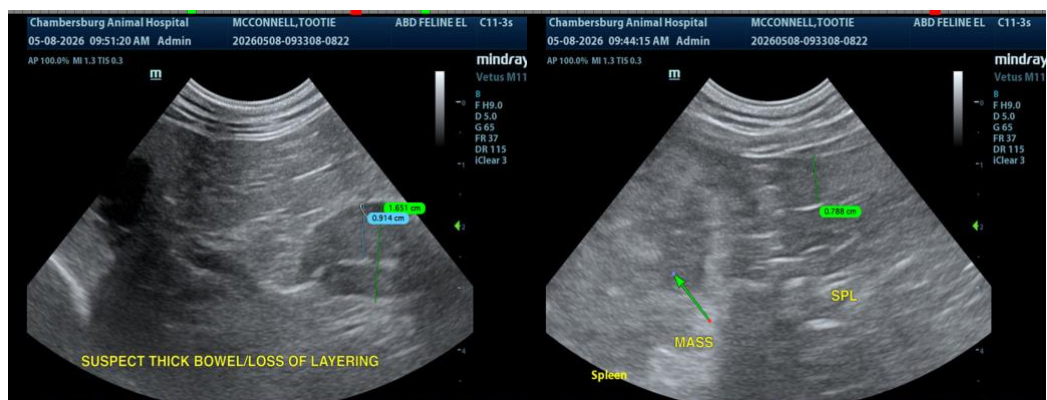
There's a large mixed echogenicity mid-abdominal mass lesion observed. This overlaps the spleen in several areas, increasing concern for possible splenic origin. A definitive vascular attachment is not observed but is suspected. Recommend a fine needle aspirate of this lesion for cytologic evaluation.

Additionally, there is a hypoechoic structure in the region of the duodenum concerning for possible duodenal mass lesion. There's no evidence of proximal obstruction and overlapping bowel lesion or similar cannot be ruled out. If a safe window for sampling is available, a fine needle aspirate could be considered.

There is what appears to be an irregular cystic structure visualized dorsal to the gallbladder. This is suspected to be a benign hepatic cyst, although an association with the gallbladder cannot be definitively ruled out.

In this individual, a contrast CT scan would be very helpful (particularly if surgical intervention would be considered) to better establish the extent and origins of these structures. Additionally, cytology would help to guide potential medical management.

Recommend three view thoracic radiographs to evaluate for possible concurrent thoracic disease/involvement.





PATIENT

Tootie McConnell

SPECIES

Feline

BREED

DSH

SEX

Neutered Male

AGE

15 Years

WEIGHT

13.5 lbs

INTERPRETED BY

Kathleen Sennello
DVM, MS, Diplomate
ACVIM (Small animal
Internal Medicine)

IMAGING PERFORMED BY

Dr. Mary Pearce

HOSPITAL NAME

Chambersburg Animal
Hospital

REFERRING VET

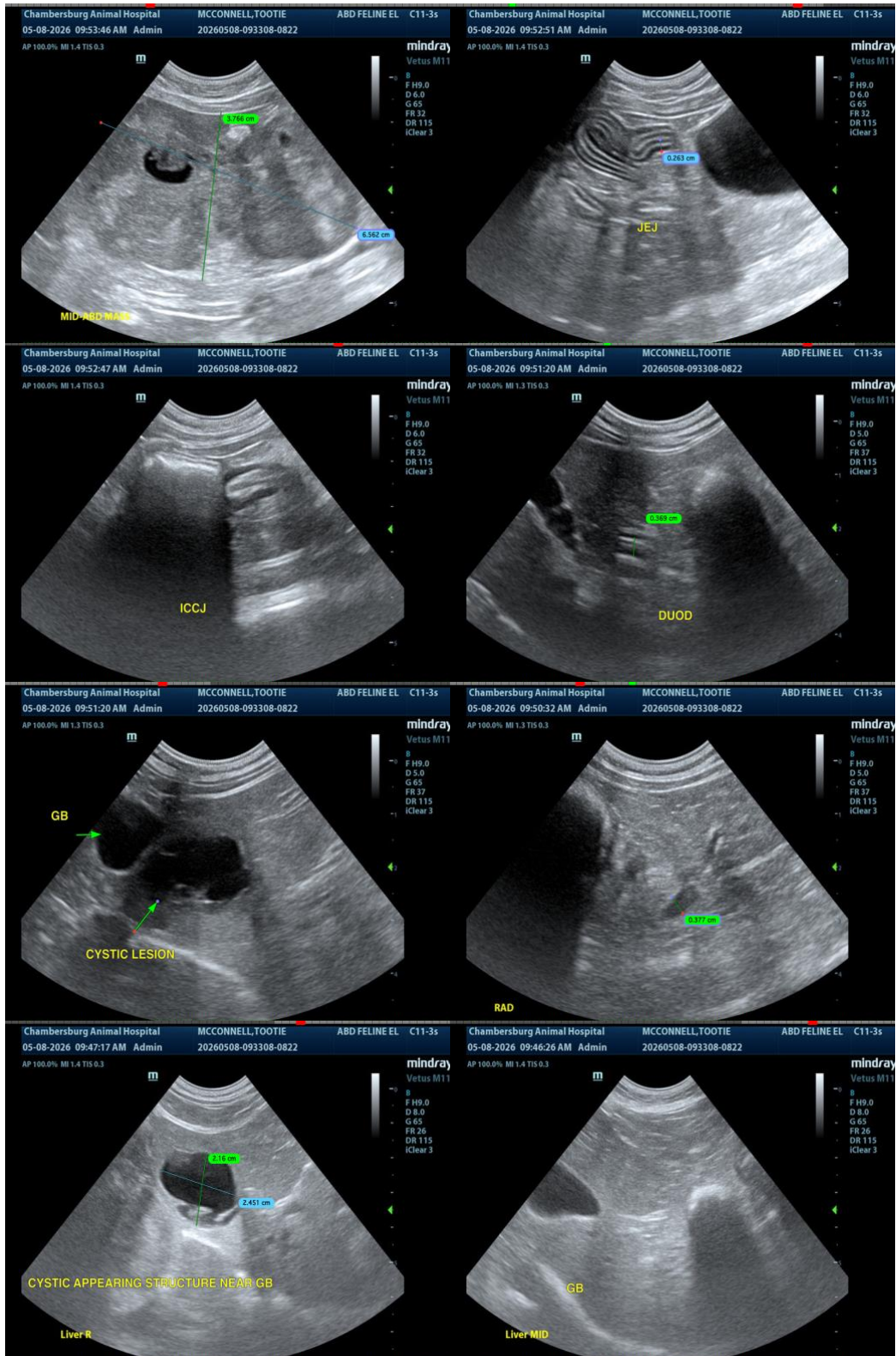
Dr. Mary Pearce

INVOICE

14945

DATE

05/08/26





PATIENT

Tootie McConnell

SPECIES

Feline

BREED

DSH

SEX

Neutered Male

AGE

15 Years

WEIGHT

13.5 lbs

INTERPRETED BY

Kathleen Sennello
DVM, MS, Diplomate
ACVIM (Small animal
Internal Medicine)

IMAGING PERFORMED BY

Dr. Mary Pearce

HOSPITAL NAME

Chambersburg Animal
Hospital

REFERRING VET

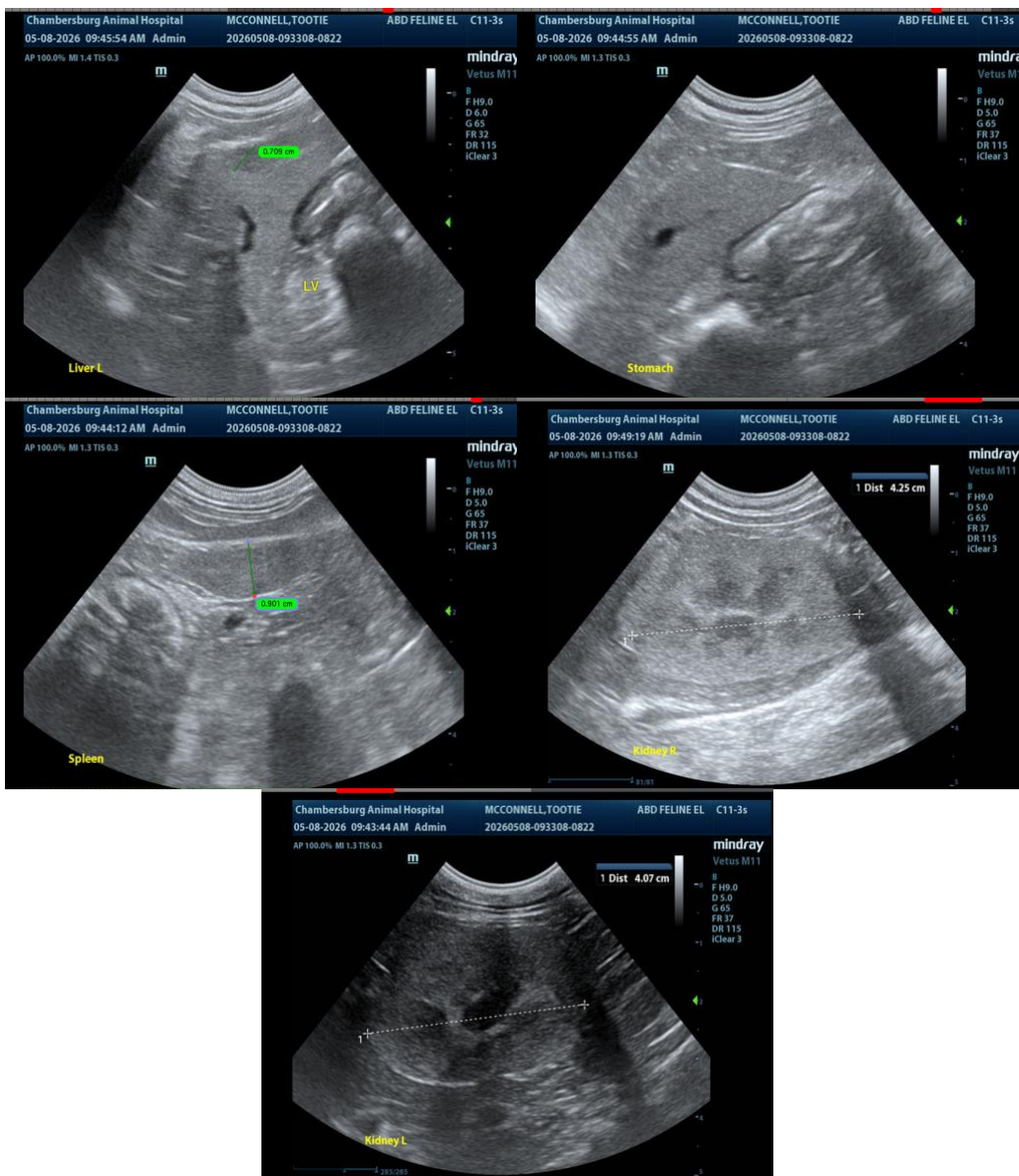
Dr. Mary Pearce

INVOICE

14945

DATE

05/08/26



The information and recommendations provided are based on the images presented by the referring veterinarian/sonographer. No evaluation can be communicated regarding pathology that was not visible in the image/video clips provided.

Thank you for this referral. If the clinical or image interpretation does not parallel your findings or if I can be of any further assistance, please contact me.

Kathleen Sennello DVM, MS, Diplomate ACVIM (Small animal Internal Medicine)

info@sonopath.com