



DATE PRESENTING CLINICAL SIGNS

5/7/26 **Patient History:** UPC 10.7, alkphos 3,933 - no clinical issues, not pu/pd, severe periodontal dis.

PATIENT Current Medications: None current.

Rosie Lackle **Labwork Results:** Labwork not attached, reported as above.

Date of Previous IntraPet Ultrasound: No previous.

Sedation: Not required to complete full diagnostic ultrasound.

Stat Report: Not requested.

SPECIES Imaging Performed by: Stephanie Warga RDCS, RVT.

Canine

ULTRASONOGRAPHIC EXAMINATION OF THE ABDOMEN

BREED Urinary System

Toy Poodle The urinary bladder is moderately distended with anechoic urine. The Bladder wall, trigone, ureteral papillae and visible urethra (to a depth of 2cm) appear normal with no evidence of wall thickening, mucosal irregularities, masses or cystic calculi.

SEX

Spayed Female

The left kidney has a normal shape and size (4.57 cm) with mild pyelectasia and too numerous to count small cortical cysts. Overall echogenicity is slightly hyperechoic with significantly decreased corticomedullary distinction and a typical 1:3 cortex:medulla ratio. There is no evidence of focal perinephric inflammation or effusion. There is no evidence of nephroliths, infarcts or hydroureter. Renal vasculature is normal.

AGE

8/21/14

WEIGHT

16 lbs

The right kidney has a normal shape and size (4.23 cm) with pyelectasia at 0.38 cm and too numerous to count small cortical cysts. An example of a larger cyst measures 0.68 cm. Overall echogenicity is slightly hyperechoic with significantly decreased corticomedullary distinction and a typical 1:3 cortex:medulla ratio. There is no evidence of focal perinephric inflammation or effusion. There is no evidence of nephroliths, infarcts or hydroureter. Renal vasculature is normal.

INTERPRETED BY

Kathleen Sennello DVM,
MS, Diplomate ACVIM
(Small Animal Internal
Medicine)

Adrenal Glands

The left adrenal gland is large and abnormal in appearance, measuring 0.86 cm at the cranial pole and 1.12 cm at the caudal pole. The parenchyma is somewhat mottled. It is observed in its normal position cranial to the left renal artery. It is abnormal in appearance in that it is large and there is a hyperechoic nodule in the cranial pole measuring 0.57 cm x 0.85 cm. No evidence of vascular invasion visualized.

HOSPITAL NAME

Essex Middle River
Veterinary Center

The right adrenal gland is large, measuring 0.86 cm at the cranial pole and 1.28 cm at the caudal pole. It is observed in its normal position between the cranial aspect of the right kidney and the caudal vena cava. The parenchyma is slightly mottled in appearance. No evidence of vascular invasion visualized.

REFERRING VET

Dr. Zulty

Spleen

The spleen is normal in size and shape. The blood flow through the hilus and splenic parenchyma appears normal. There are hyperechoic pinpoint foci/striations visualized within the parenchyma, most consistent with dystrophic mineralization.

INVOICE

75033

Liver

The liver is large in size and rounded. The parenchyma is heterogenous in echotexture with subtle, indistinct focal mottling. The visible portions of the vasculature and biliary tract appear normal. There are numerous poorly defined hypoechoic nodules in the parenchyma. Some are fairly large. Examples measure 2.54 cm x 1.43 cm and 2.01 cm x 1.19 cm.

The gall bladder lumen is significantly distended. Some areas of the wall appear mildly thickened with adherent debris. There is a large amount of primarily non-organized echogenic debris. Some of the debris appears mineralized consistent with sandy debris and mucinous debris. There is no evidence of bile duct dilation.

Gastrointestinal

The stomach contains minimal luminal contents. It measures at a normal thickness of 0.47 cm with some variability due to the presence of rugal folds. The distinction of the gastric wall layers is adequate and there is no impression of reduced peristaltic activity. No masses or focal lesions were observed.

The visualized areas of duodenum, jejunum and ileum have a uniform diameter with minimal fluid distension. Wall appears subjectively, mildly increased. Bowel loops follow a typical curvilinear path with distinct wall layering. Duodenum wall measures 0.42 cm. Jejunum wall measures 0.32 cm. Visualized peristalsis appears appropriate. There is mucosal speckling visualized in some sections of small bowel.

Sections of colon are visualized with formed fecal material and gas shadowing distally. There is no observed focal or generalized colon wall thickening or loss of layering.

Pancreas

The pancreas is prominent and mottled compared to the surrounding isoechoic mesentery. There is no evidence of nodules or cystic lesions. There is no evidence of regional mesenteric inflammation or fluid.

Free Abdomen

Evaluation of the peritoneal cavity did not reveal any evidence of effusion, or subjective lymphadenomegaly. The Medial iliac nodes appear normal and there was no evidence of a caudal aortic thrombus at the bifurcation. The omentum is of normal uniform echogenicity.

PRIMARY FINDINGS

- Bilateral adrenomegaly with hyperechoic nodule in the cranial pole of the left adrenal gland – The bilateral adrenomegaly could be consistent with bilateral hyperplasia (e.g., secondary to pituitary-dependent hyperadrenocorticism), bilateral infiltrative neoplasia, inflammatory adrenal disease, other. Correlation with clinical findings is recommended. The hyperechoic nodule has a somewhat benign appearance, consistent with possible focal hyperplasia, an adenoma, other. An early neoplastic lesion cannot be ruled out.
- Decreased corticomedullary distinction in both kidneys with bilateral mild pyelectasia – Mild loss of corticomedullary distinction in both kidneys could be consistent with chronic degenerative disease or interstitial nephrosis. Pyelectasia of the kidneys could be consistent with pyelonephritis, chronic renal disease, secondary to PU/PD or fluid therapy (if applicable), other.
- Large, heterogeneous liver with numerous hypoechoic nodules – The diffuse hepatic changes are non-specific and could be consistent with vacuolar hepatopathy, nodular hyperplasia, inflammatory/immune-mediated disease, fibrosis, extramedullary hematopoiesis, toxic hepatopathy (e.g., copper), infiltrative neoplasia (less likely) or other hepatopathy. The hypoechoic nodules have somewhat of a benign appearance, although an early neoplastic process cannot be ruled out.
- Large fluid as well as some mucinous and mineralized debris visualized in the gallbladder.

- Mildly thickened small intestine with some areas exhibiting mucosal speckling – Bright mucosal speckling has been postulated to represent dilated lacteals or focal accumulations of mucus, cellular debris, etc.. in the mucosal crypts.

SECONDARY FINDINGS

- Dystrophic mineralization visualized associated with the spleen. This is likely a benign change associated with an endocrinopathy.
- Pancreatic changes most consistent with chronic pancreatic remodeling. Mild chronic pancreatitis cannot be ruled out.

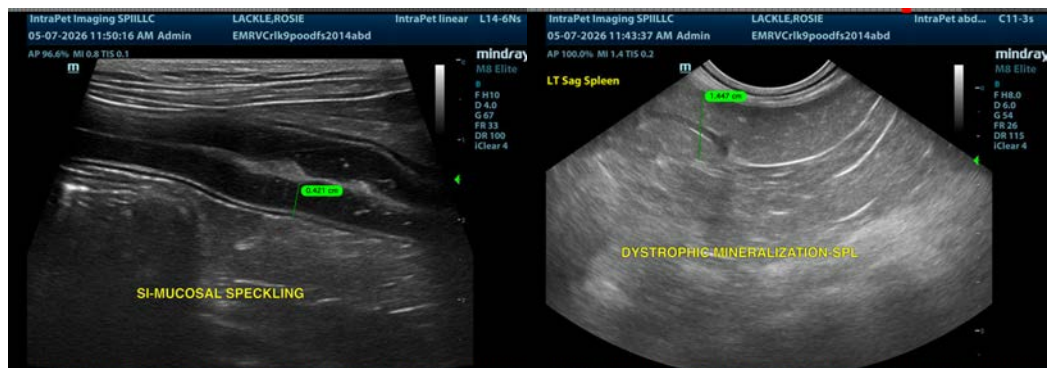
INTERPRETATION OF THE FINDINGS & FURTHER RECOMMENDATIONS

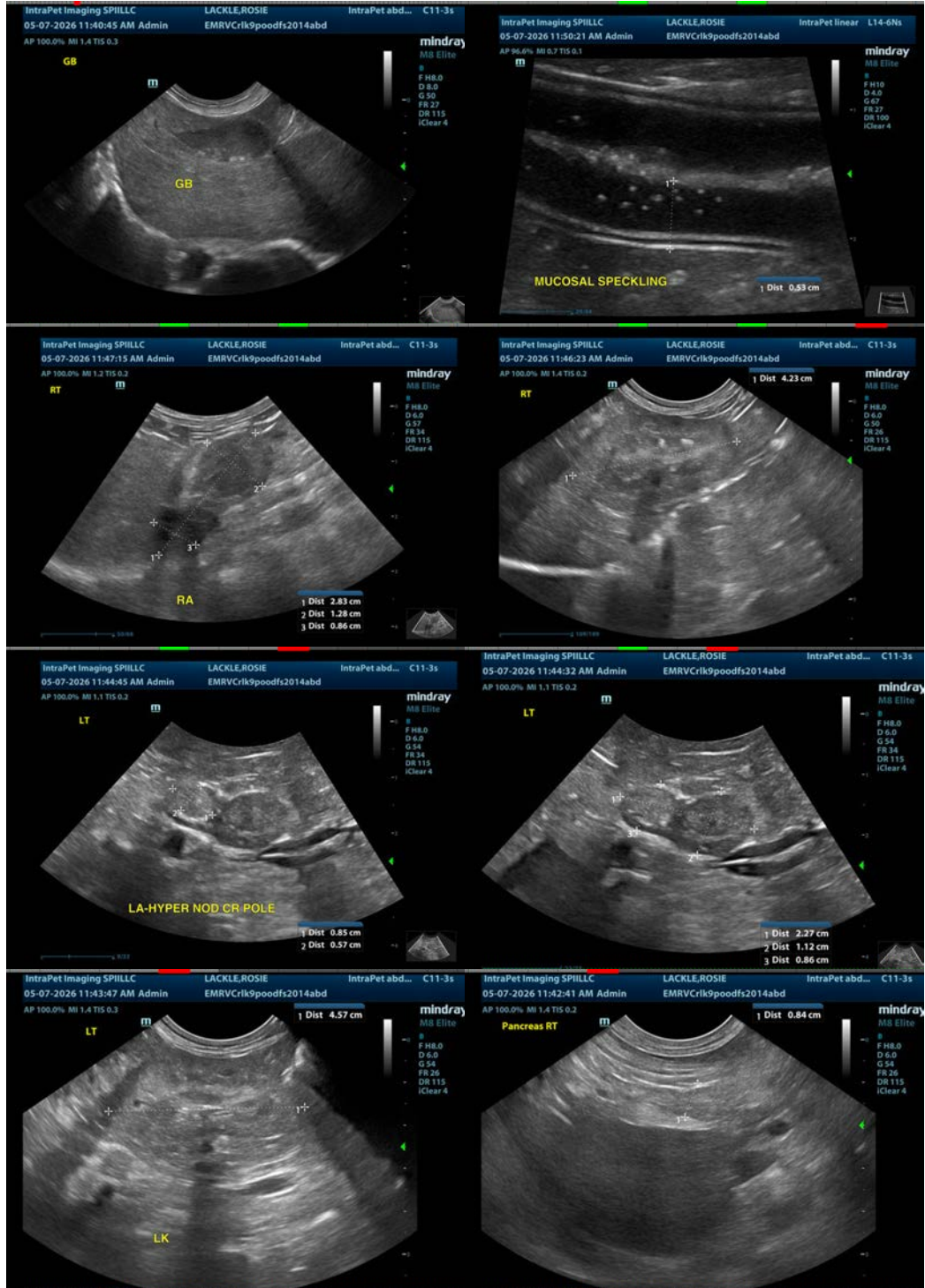
Both adrenals are extremely enlarged, and the liver is large and heterogeneous with some hypoechoic nodules. Findings would be concerning for possible pituitary dependent hyperadrenocorticism with the combination of elevation in ALP, proteinuria, etc. Recommend adrenal function testing and a blood pressure evaluation. In this situation, treatment would likely be recommended even if symptoms are not perceived to the severe proteinuria reported, as this would increase the risk for complications such as thrombi, etc. due to a potentially hypercoagulable state. Medical management for proteinuria should be considered as well as a urine culture due to the pyelectasia noted. Continued monitoring of the adrenals is recommended, particularly the left adrenal, for progressive enlargement of the hyperechoic nodule visualized (recheck in 2-3 months).

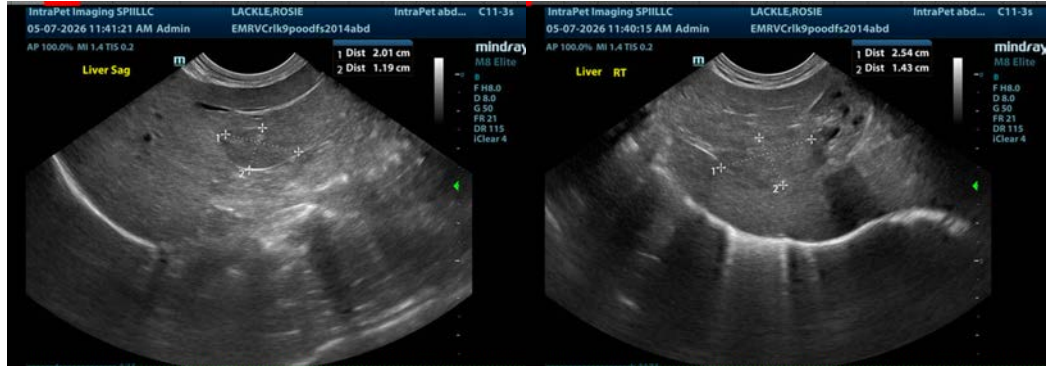
Both kidneys are significantly abnormal, most consistent with chronic renal disease.

There are numerous hypoechoic nodules in the liver. Options would include continued monitoring or a fine needle aspirate.

There is a large amount of disorganized debris visualized in the gallbladder. Recommend starting chronic Ursodiol therapy and continued monitoring of the gallbladder







The information and recommendations provided are based on the images presented by the referring veterinarian/sonographer. No evaluation can be communicated regarding pathology that was not visible in the image/video clips provided.

Thank you for this referral. If the clinical or image interpretation does not parallel your findings or if I can be of any further assistance please contact me.

Kathleen Sennello DVM,MS, Diplomate ACVIM (Small animal Internal Medicine)
info@sonopath.com