**DATE PRESENTING CLINICAL SIGNS**

5/7/26 **Patient History:** Yearly increasing ALT for unknown reason.

PATIENT **Current Medications:** Fluoxetine 40mg 1 SID.

Comet Robinson **Labwork Results:** Labwork attached.

Date of Previous IntraPet Ultrasound: No previous.

Sedation: IM dose required to complete full diagnostic ultrasound.

Stat Report: Not requested.

SPECIES **Imaging Performed by:** Rachel Brillhart, RDMS.

Canine

ULTRASONOGRAPHIC EXAMINATION OF THE ABDOMEN**BREED** *Urinary System*

Border Collie The urinary bladder is moderately distended with anechoic urine. The Bladder wall, trigone, ureteral papillae and visible urethra (to a depth of 2cm) appear normal with no evidence of wall thickening, mucosal irregularities, masses or cystic calculi.

SEX

Neutered Male

The prostate is normal in size (1.11 cm) and shape for this neutered male dog. The parenchyma is homogenous and the external margins are smooth. The prostatic urethra appears normal with no evidence of irregularity, invasion, mass effect or calculi.

AGE

9/15/15

The left kidney has a normal shape and size (6.85 cm) with a small cortical cyst measuring 0.47 cm. Overall echogenicity is normal with adequate corticomedullary distinction and a typical 1:3 cortex:medulla ratio.

WEIGHT

53 lbs

There is no evidence of focal perinephric inflammation or effusion. There is no evidence of pyelectasia, nephroliths, infarcts or hydroureter. Renal vasculature is normal.

INTERPRETED BY

Kathleen Sennello DVM,
MS, Diplomate ACVIM
(Small Animal Internal
Medicine)

The right kidney has a normal shape and size (6.64 cm) with a small cortical cyst measuring 0.34 cm. Overall echogenicity is normal with adequate corticomedullary distinction and a typical 1:3 cortex:medulla ratio.

There is no evidence of focal perinephric inflammation or effusion. There is no evidence of pyelectasia, nephroliths, infarcts or hydroureter. Renal vasculature is normal.

HOSPITAL NAME

Edgewood Veterinary
Hospital

Adrenal Glands

The left adrenal gland is normal in size measuring 0.64 cm at the cranial pole and 0.62 cm at the caudal pole. It is observed in its normal position cranial to the left renal artery. It is normal in appearance (uniformly hypoechoic) and shape with no evidence of a mass effect.

REFERRING VET

Dr. Wright

The right adrenal gland is normal in size measuring 0.69 cm at the cranial pole and 0.68 cm at the caudal pole. It is observed in its normal position between the cranial aspect of the right kidney and the caudal vena cava. It is normal in appearance (uniformly hypoechoic) and shape with no evidence of a mass effect.

INVOICE

75034

Spleen

The spleen is subjectively normal in size (2.66 cm), echotexture is homogenous, and the splenic capsule is smooth with no irregularities. The blood flow through the hilus and splenic parenchyma appears normal. There is a slightly irregular, hypoechoic region in the hepatic parenchyma measuring approximately 2.13 cm x 2.12 cm, possibly consistent with an irregular nodule, an infarct, etc.

Liver

The liver is normal in size but slightly irregular in shape. The parenchyma is heterogenous in echotexture with subtle, indistinct focal mottling. The visible portions of the vasculature and biliary tract appear normal. There

is a hypoechoic solid mass effect visualized in the right cranial abdomen (caudal to the stomach), which appears to have a narrow vascular attachment to the liver, most consistent with a pedunculated liver mass lesion.

The gall bladder lumen is significantly distended. Some areas of the wall appear mildly thickened with adherent debris. There is a large amount of primarily non-organized echogenic debris. There is no evidence of bile duct dilation.

Gastrointestinal

The stomach contains minimal luminal contents. It measures at a normal thickness of 0.75 cm with some variability due to the presence of rugal folds. The distinction of the gastric wall layers is adequate and there is no impression of reduced peristaltic activity. No masses or focal lesions were observed.

The visualized areas of duodenum, jejunum and ileum have a relatively uniform diameter with minimal fluid distension. Wall thickness is normal. Bowel loops follow a curvilinear path with distinct wall layering maintaining the typical 1:3 muscularis:mucosa layer ratio. Jejunum wall measures 0.33 cm. Visualized peristalsis appears appropriate. There were no focal lesions consistent with obstruction or a mass effect observed.

Sections of colon are visualized with formed fecal material and gas shadowing distally. There is no observed focal or generalized colon wall thickening or loss of layering.

Pancreas

The pancreas is normal and isoechoic to surrounding mesentery. There is no evidence of nodules or cystic lesions. There is no evidence of regional mesenteric inflammation or fluid.

Free Abdomen

Evaluation of the peritoneal cavity did not reveal any evidence of effusion, or subjective lymphadenomegaly. The Medial iliac nodes appear normal and there was no evidence of a caudal aortic thrombus at the bifurcation. The omentum is of normal uniform echogenicity.

ULTRASONOGRAPHIC FINDINGS

- Irregular, hypoechoic region of the spleen – Consider differentials such as extramedullary hematopoiesis, infarction, nodular hyperplasia, splenic hematoma, hemangiosarcoma, other.
- Solid, hypoechoic, pedunculated right-sided liver mass lesion – Findings could be consistent with an adenoma, carcinoma, other.
- Large gallbladder debris – A large amount of debris is evident in the gall bladder with no evidence of a mucocele or associated inflammation at this time. This could represent an early mucocele or cholestasis, with minimal evidence of associated inflammation at this time. Continued monitoring of labwork and ultrasound are warranted for progression of this lesion. Ursodiol therapy could be considered.

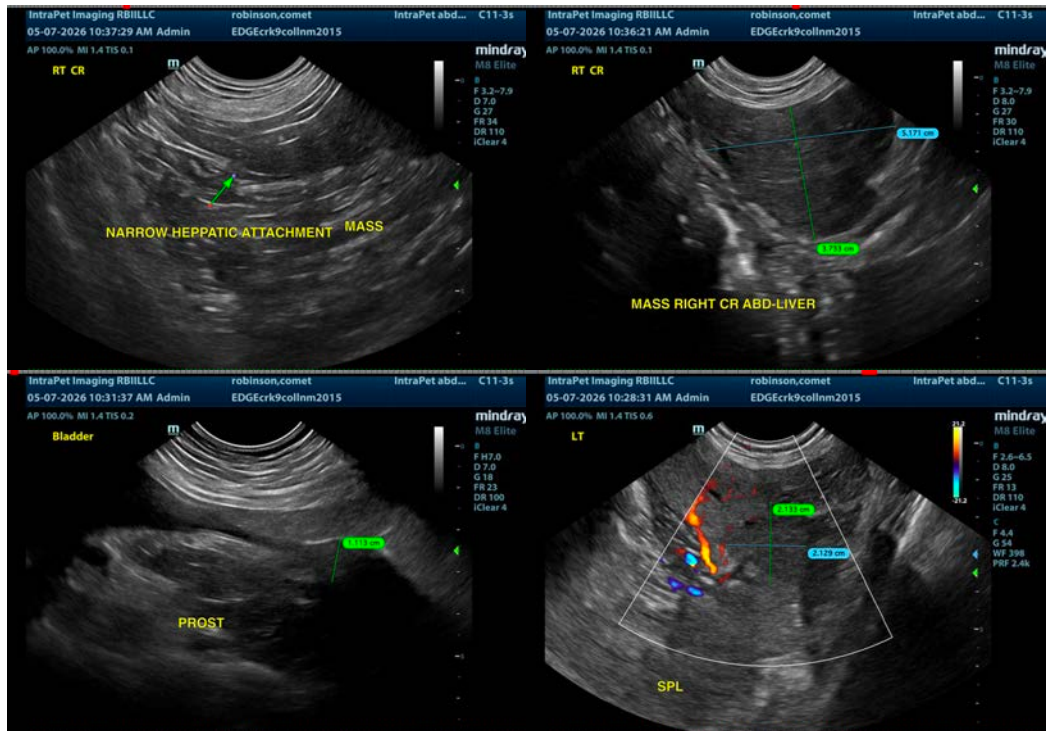
INTERPRETATION OF THE FINDINGS & FURTHER RECOMMENDATIONS

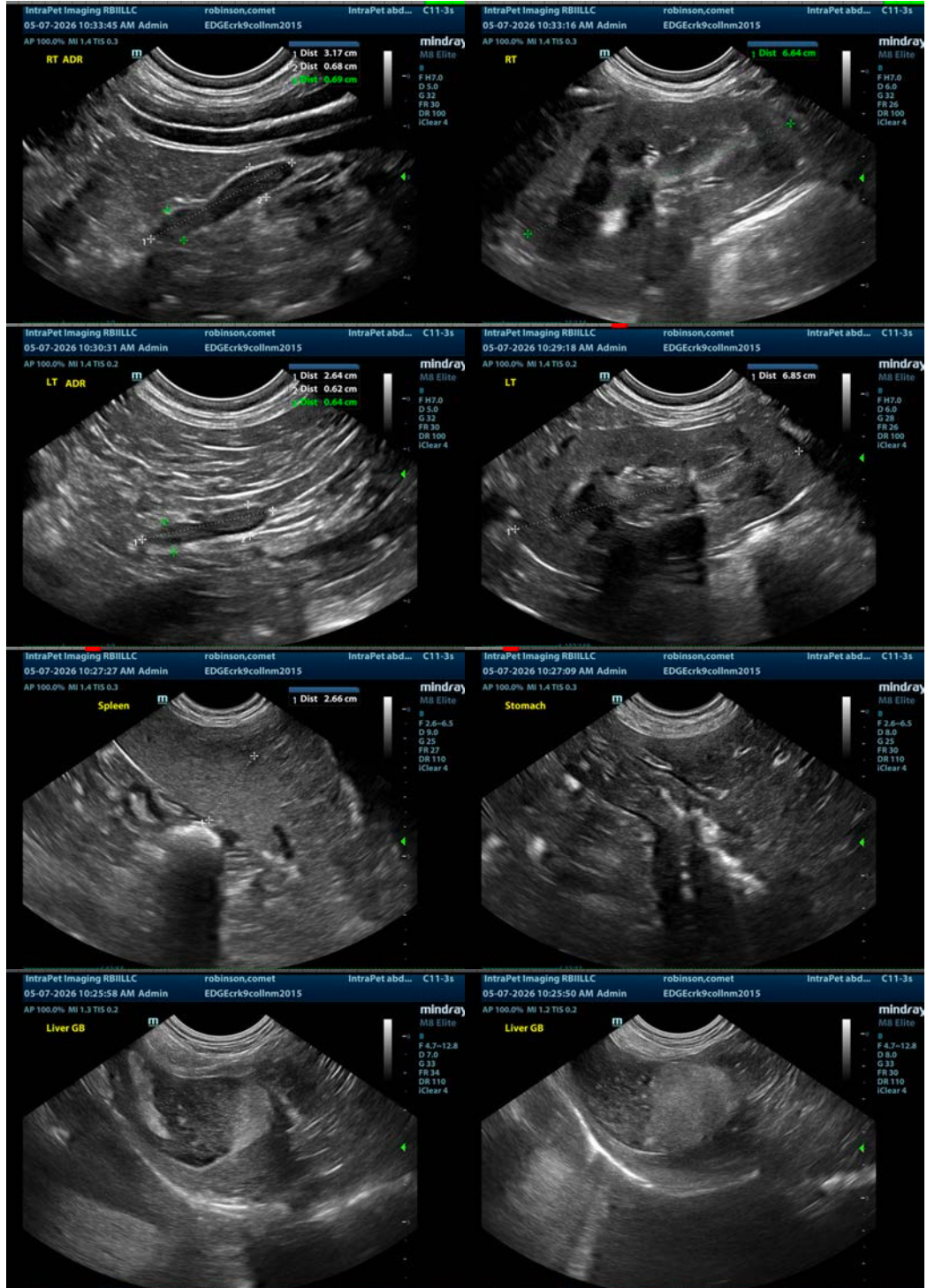
There is a solid hypoechoic mass effect visualized on the right side caudal to the stomach with the appearance of a narrow vascular attachment to the liver, most consistent with a pedunculated liver mass lesion. Recommend a fine needle aspirate.

This would likely be a good candidate for surgery. Ideally a contrast CT scan would be considered to confirm the nature and extent of the lesion. Normal liver tissue should be biopsied at the same time with samples for histopathology, culture and copper levels, as a chronic hepatopathy has been present, and 3-view thoracic radiographs should be performed.

There is an irregular hypoechoic region of the spleen that does not deform the splenic margins. Consider differentials such as extramedullary hematopoiesis, infarction, nodular hyperplasia, splenic hematoma, hemangiosarcoma, other. Recommend a fine needle aspirate of this area. If CT scan is pursued, this area could also be evaluated, as well as the gallbladder, which has a large amount of debris with a prominent wall but no evidence of surrounding inflammation at this time. Recommend starting Ursodiol therapy and continued monitoring of the gallbladder.

Recommend three view thoracic radiographs to evaluate for possible concurrent thoracic disease/involvement (disregard if this has already been done).





The information and recommendations provided are based on the images presented by the referring veterinarian/sonographer. No evaluation can be communicated regarding pathology that was not visible in the image/video clips provided.

Thank you for this referral. If the clinical or image interpretation does not parallel your findings or if I can be of any further assistance please contact me.

Kathleen Sennello DVM,MS, Diplomate ACVIM (Small animal Internal Medicine)
info@sonopath.com