



**PATIENT**

Penny Snyder

**PRESENTING CLINICAL SIGNS**

lethargic, not eating, suspect abdo mass. Mass? Neoplasia?

**SPECIES**

Feline

**ULTRASONOGRAPHIC EXAMINATION OF THE ABDOMEN**

**Urinary System**

**BREED**

DSH

The urinary bladder is moderately distended with anechoic urine. The Bladder wall, trigone, ureteral papillae and visible urethra (to a depth of 2cm) appear normal with no evidence of wall thickening, mucosal irregularities, masses or cystic calculi.

**SEX**

Spayed Female

The left kidney has a normal shape and size (4.22 cm). Overall echogenicity is normal with adequate corticomedullary distinction and a typical 1:3 cortex:medulla ratio. There is no evidence of focal perinephric inflammation or effusion. There is no evidence of pyelectasia, nephroliths, infarcts or hydroureter. Renal vasculature is normal.

**AGE**

13 Years

The right kidney has a normal shape and size (4.56 cm). Overall echogenicity is normal with adequate corticomedullary distinction and a typical 1:3 cortex:medulla ratio. There is no evidence of focal perinephric inflammation or effusion. There is no evidence of pyelectasia, nephroliths, infarcts or hydroureter. Renal vasculature is normal.

**WEIGHT**

5.83 kg

**Adrenal Glands**

**INTERPRETED BY**

Kathleen Sennello DVM,  
 MS, Diplomate ACVIM  
 (Small Animal Internal  
 Medicine)

The left adrenal gland is normal in size measuring 0.33 cm at the caudal pole. It is observed in its normal position cranial to the left renal artery. It is normal in appearance (uniformly hypoechoic) and shape with no evidence of a mass effect.

The right adrenal gland is normal in size measuring 0.37 cm at the caudal pole. It is observed in its normal position between the cranial aspect of the right kidney and the caudal vena cava. It is normal in appearance (uniformly hypoechoic) and shape with no evidence of a mass effect.

**IMAGING PERFORMED BY**

Amanda Stewart

**Spleen**

The spleen is large (0.88 cm) and irregular in shape and appearance. The blood flow through the hilus and splenic parenchyma appears normal. There is a large, mixed echogenicity, poorly defined mass effect visualized medial to the spleen, measuring >5.56 cm x 5.35 cm. There appears to be a vascular association between this structure and a portion of the spleen, concerning for a poorly defined expansile mass effect originating from the spleen. Pancreatic involvement or similar cannot be excluded.

**HOSPITAL NAME**

Buck Animal Hospital

**Liver**

The liver is subjectively normal in size, and echogenicity with smooth peripheral margins. The parenchyma is homogenous echotexture. The visible portions of the vasculature and biliary tract appear normal. No focal nodules or cystic lesions are observed.

**REFERRING VET**

Dr. Calvise

**INVOICE**

74976

The gall bladder lumen is moderately distended. The wall of the gall bladder is not thickened and has a smooth mucosal surface. Luminal contents are mild and likely incidental at this time. The cystic and common bile ducts are normal/not visible.

**DATE**

5/6/26



**PATIENT**

Penny Snyder

**SPECIES**

Feline

**BREED**

DSH

**SEX**

Spayed Female

**AGE**

13 Years

**WEIGHT**

5.83 kg

**INTERPRETED BY**

Kathleen Sennello DVM,  
 MS, Diplomate ACVIM  
 (Small Animal Internal  
 Medicine)

**IMAGING PERFORMED BY**

Amanda Stewart

**HOSPITAL NAME**

Buck Animal Hospital

**REFERRING VET**

Dr. Calvise

**INVOICE**

74976

**DATE**

5/6/26

***Gastrointestinal***

The stomach contains minimal luminal contents. It measures at a normal thickness of <0.36cm with some variability due to the presence of rugal folds. The distinction of the gastric wall layers is adequate and there is no impression of reduced peristaltic activity. No masses or focal lesions were observed.

The visualized areas of duodenum, jejunum and ileum have a relatively uniform diameter with minimal fluid distension. Wall thickness is normal. Bowel loops follow a curvilinear path with distinct wall layering maintaining the typical 1:3 muscularis:mucosa layer ratio. Duodenum wall measures 0.20 cm. Jejunum wall measures 0.18 cm. Visualized peristalsis appears appropriate. There were no focal lesions consistent with obstruction or a mass effect observed.

Sections of colon are visualized with formed fecal material and gas shadowing distally. There is no observed focal or generalized colon wall thickening or loss of layering.

***Pancreas***

There is a significant amount of mixed echogenicity inflammatory tissue in the region of the left limb of the pancreas. Some of this in the cranial abdomen appears to involve the left limb with some regional reactive mesentery.

***Free Abdomen***

There is a small to moderate amount of echogenic free fluid. No significant lymphadenopathy noted. The omentum is highly irregular and reactive, borderline nodular, possibly consistent with carcinomatosis.

**ULTRASONOGRAPHIC FINDINGS**

- Large, irregular, poorly defined, mixed echogenicity left-sided mass effect with surrounding peritonitis and echogenic free fluid – The appearance is suggestive of a poorly defined splenic mass lesion, although a pancreatic mass with splenic involvement or similar cannot be ruled out.
- Small to moderate echogenic effusion with reactive mesentery – Findings are most consistent with peritonitis (sterile versus septic).

**INTERPRETATION OF THE FINDINGS & FURTHER RECOMMENDATIONS**

There is a large amount of poorly defined mixed echogenicity tissue medial and caudal to the spleen in the region of the left limb of the pancreas. There is an area of this more solid tissue which appears to involve the spleen. Splenic origin is suspected, although pancreatic involvement cannot be ruled out. There is generalized omental inflammation, irregularity, and echogenic free fluid suggestive of peritonitis (likely sterile), possibly consistent with a neoplastic effusion, carcinomatosis, etc. Recommend fluid analysis and cytology as well as a fine needle aspirate of a more solid area of mass near the spleen (this would also rule out a hemoabdomen). If cytologic diagnosis can be obtained, recommend consultation with a veterinary oncologist regarding best treatment options and prognosis. Surgical options may be limited due to the expansile and poorly defined nature of this lesion. If surgery is considered, a contrast CT scan would be recommended to better determine the extent and nature of the lesion.

Recommend three view thoracic radiographs to evaluate for possible concurrent thoracic disease/involvement (disregard if this has already been done).



**PATIENT**

Penny Snyder

**SPECIES**

Feline

**BREED**

DSH

**SEX**

Spayed Female

**AGE**

13 Years

**WEIGHT**

5.83 kg

**INTERPRETED BY**

Kathleen Sennello DVM,  
 MS, Diplomate ACVIM  
 (Small Animal Internal  
 Medicine)

**IMAGING  
 PERFORMED BY**

Amanda Stewart

**HOSPITAL NAME**

Buck Animal Hospital

**REFERRING VET**

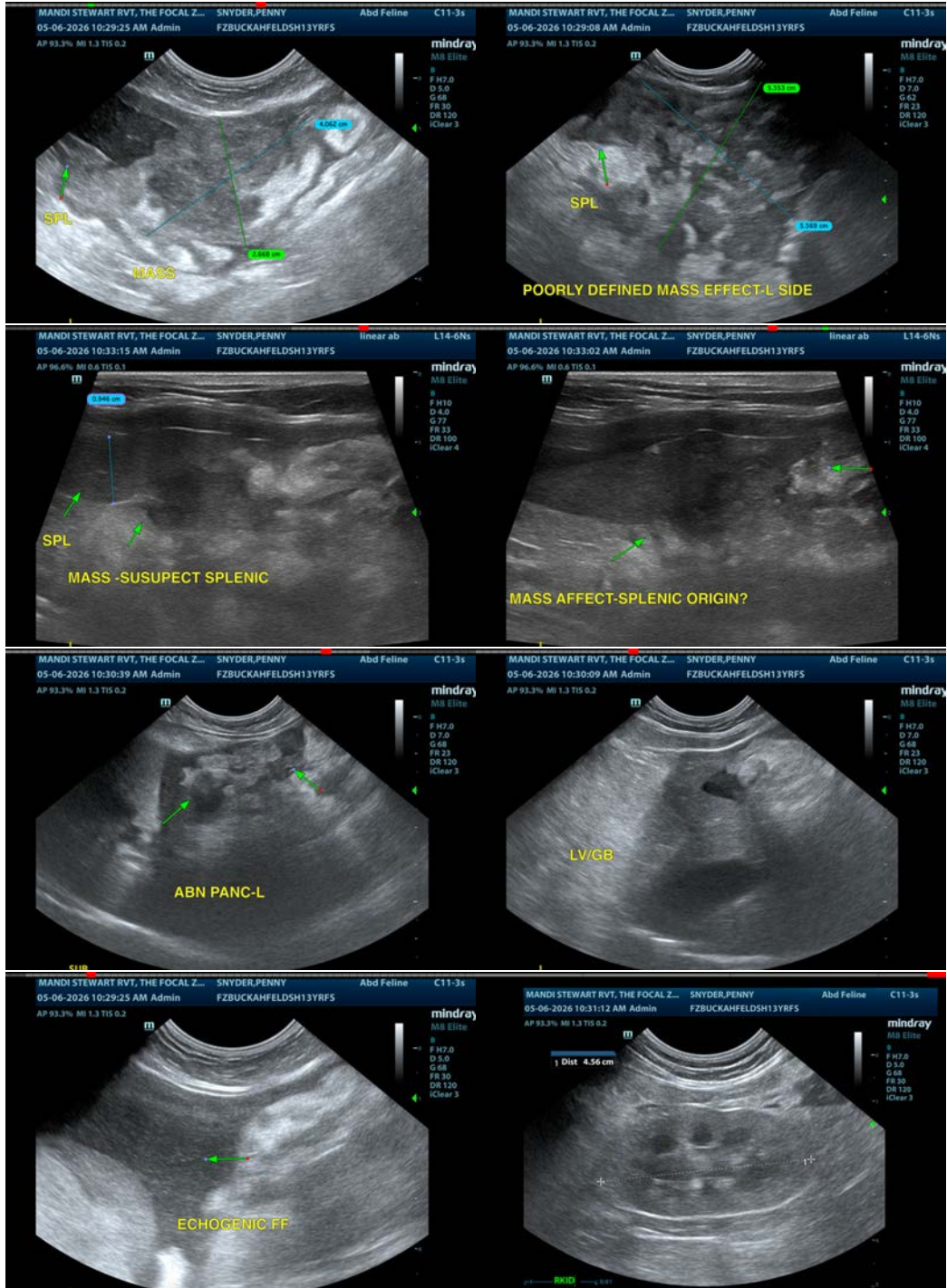
Dr. Calvise

**INVOICE**

74976

**DATE**

5/6/26





**PATIENT**

Penny Snyder

**SPECIES**

Feline

**BREED**

DSH

**SEX**

Spayed Female

**AGE**

13 Years

**WEIGHT**

5.83 kg

**INTERPRETED BY**

Kathleen Sennello DVM,  
 MS, Diplomate ACVIM  
 (Small Animal Internal  
 Medicine)

**IMAGING  
 PERFORMED BY**

Amanda Stewart

**HOSPITAL NAME**

Buck Animal Hospital

**REFERRING VET**

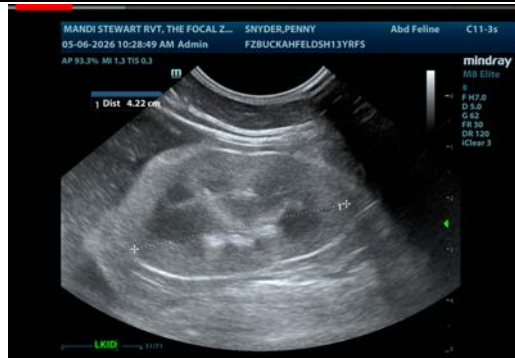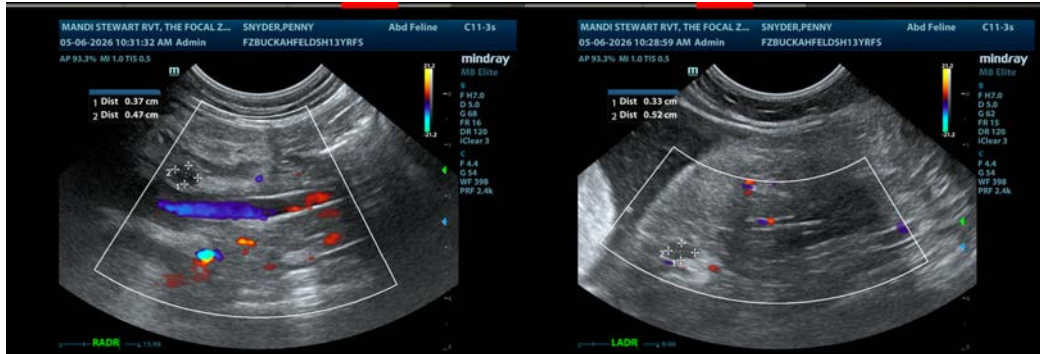
Dr. Calvise

**INVOICE**

74976

**DATE**

5/6/26



The information and recommendations provided are based on the images presented by the referring veterinarian/sonographer. No evaluation can be communicated regarding pathology that was not visible in the image/video clips provided.

Thank you for this referral. If the clinical or image interpretation does not parallel your findings or if I can be of any further assistance please contact me.

Kathleen Sennello DVM,MS, Diplomate ACVIM (Small animal Internal Medicine)

info@sonopath.com