



PATIENT

Harley Sullivan

SPECIES

Canine

BREED

Mix

SEX

Spayed Female

AGE

4

WEIGHT

53.6

INTERPRETED BY

Kathleen A. Sennello
DVM, MS, DACVIM
(SAIM)

IMAGING PERFORMED BY

Jenn

HOSPITAL NAME

Rockaway AH

REFERRING VET

Dr. Maniar

INVOICE

35958

DATE

5/6/26

PRESENTING CLINICAL SIGNS

History: Had a prev u/s 2/26 Hx of IBD now intermittent vomiting

ULTRASONOGRAPHIC EXAMINATION OF THE ABDOMEN

Urinary System

The urinary bladder is mildly distended with anechoic urine. The bladder wall, trigone, ureteral papillae appear normal with no evidence of wall thickening, mucosal irregularities, masses or cystic calculi. Lack of urine distention hinders full evaluation of the urinary bladder.

The left kidney has a normal shape and size (6.48 cm). Overall echogenicity is normal with adequate corticomedullary distinction and a typical 1:3 cortex:medulla ratio. There is no evidence of perinephric inflammation or effusion. There is no evidence of pyelectasia, nephroliths, infarcts or hydroureter. Renal vasculature is normal.

The right kidney has a normal shape and size (5.15 cm). Overall echogenicity is normal with adequate corticomedullary distinction and a typical 1:3 cortex:medulla ratio. There is no evidence of perinephric inflammation or effusion. There is no evidence of pyelectasia, nephroliths, infarcts or hydroureter. Renal vasculature is normal.

Adrenal Glands

The left adrenal gland is normal in size measuring 0.52 cm at the caudal pole. It is observed in its normal position cranial to the left renal artery. It is normal in appearance (uniformly hypoechoic) and shape with no evidence of a mass effect.

The right adrenal gland is normal in size measuring 0.58 cm at the cranial pole and 0.54 cm at the caudal pole. It is observed in its normal position between the cranial aspect of the right kidney and the caudal vena cava. It is normal in appearance (uniformly hypoechoic) and shape with no evidence of a mass effect.

Spleen

The spleen is subjectively normal in size (1.86 cm), echotexture is homogenous, and the splenic capsule is smooth with no irregularities. The blood flow through the hilus and splenic parenchyma appears normal. No focal parenchymal abnormalities are visualized.

Liver

The liver is subjectively normal in size, and echogenicity with smooth peripheral margins. The parenchyma is homogenous echotexture. The visible portions of the vasculature and biliary tract appear normal. No focal nodules or cystic lesions are observed. The gall bladder lumen is moderately distended. The wall of the gall bladder is not thickened and has a smooth mucosal surface. Luminal contents are primarily anechoic. The cystic and common bile ducts are normal/not visible.

Gastrointestinal

The stomach contains a mild/moderate amount of fluid/ingesta. It measures at a normal thickness of <0.7 cm with some variability due to the presence of rugal folds. The distinction of the gastric wall layers is adequate and there is no impression of reduced peristaltic activity. No masses or focal lesions were observed.



PATIENT

Harley Sullivan

SPECIES

Canine

BREED

Mix

SEX

Spayed Female

AGE

4

WEIGHT

53.6

INTERPRETED BY

Kathleen A. Sennello
DVM, MS, DACVIM
(SAIM)

IMAGING PERFORMED BY

Jenn

HOSPITAL NAME

Rockaway AH

REFERRING VET

Dr. Maniar

INVOICE

35958

DATE

5/6/26

The visualized areas of duodenum, jejunum and ileum have a relatively uniform diameter with minimal to mild fluid distension. Wall thickness is normal. Bowel loops follow a curvilinear path with distinct wall layering maintaining the typical 1:3 muscularis: mucosa layer ratio. The jejunum measured as normal (0.35 cm). Visualized peristalsis appears appropriate. There were no focal lesions consistent with obstruction or a mass effect observed.

Sections of colon are visualized with formed fecal material and gas shadowing distally. There is no observed focal or generalized colon wall thickening or loss of layering.

Pancreas

The pancreas is normal and isoechoic to surrounding mesentery. There is no evidence of nodules or cystic lesions. There is no evidence of regional mesenteric inflammation or fluid.

Free Abdomen

Evaluation of the peritoneal cavity did not reveal any evidence of effusion, or subjective lymphadenomegaly. The medial iliac nodes appear normal and there was no evidence of a caudal aortic thrombus at the bifurcation. The omentum is of normal uniform echogenicity.

ULTRASONOGRAPHIC FINDINGS

- Mild/moderate fluid/ingesta visualized within the stomach and small intestine- Correlate with the feeding history. If the patient was adequately fasted, this could represent delayed gastric emptying. No evidence of an outflow tract obstruction is clearly visualized.

INTERPRETATION OF THE FINDINGS & FURTHER RECOMMENDATIONS

The changes observed in today's scan are relatively mild (very similar to previous scan). The stomach has some fluid and ingesta within the lumen and some loops of small intestine have mild gas and fluid. No evidence of obstructive material is visualized. Correlate with feeding history. If the patient was adequately fasted, this could represent mild ileus.

Unfortunately, there are many causes for vomiting which cannot be definitively diagnosed by ultrasound alone. Consider the following for initial evaluation/treatment.

- Recommend full lab work, including urinalysis.
- If not recently done, recommend parasite screening and empirical deworming.
- Consider a baseline cortisol screen for Addison's.
- Consider a novel protein/hydrolyzed protein diet (exclusively at least 4-6 weeks).
- Consider a GI panel to Texas A&M for evaluation of B12 levels, folate, PLI/TLI etc.. to further evaluate for pancreatic/small intestinal disease.
- Consider probiotic therapy.

If symptoms are persistent despite taking these measures, ultimately, biopsies of the GI tract may be warranted. Additionally, you could consider repeat imaging in the future looking for the development of new lesions or progression of the changes observed on today's scan.



PATIENT

Harley Sullivan

SPECIES

Canine

BREED

Mix

SEX

Spayed Female

AGE

4

WEIGHT

53.6

INTERPRETED BY

Kathleen A. Sennello
DVM, MS, DACVIM
(SAIM)

IMAGING PERFORMED BY

Jenn

HOSPITAL NAME

Rockaway AH

REFERRING VET

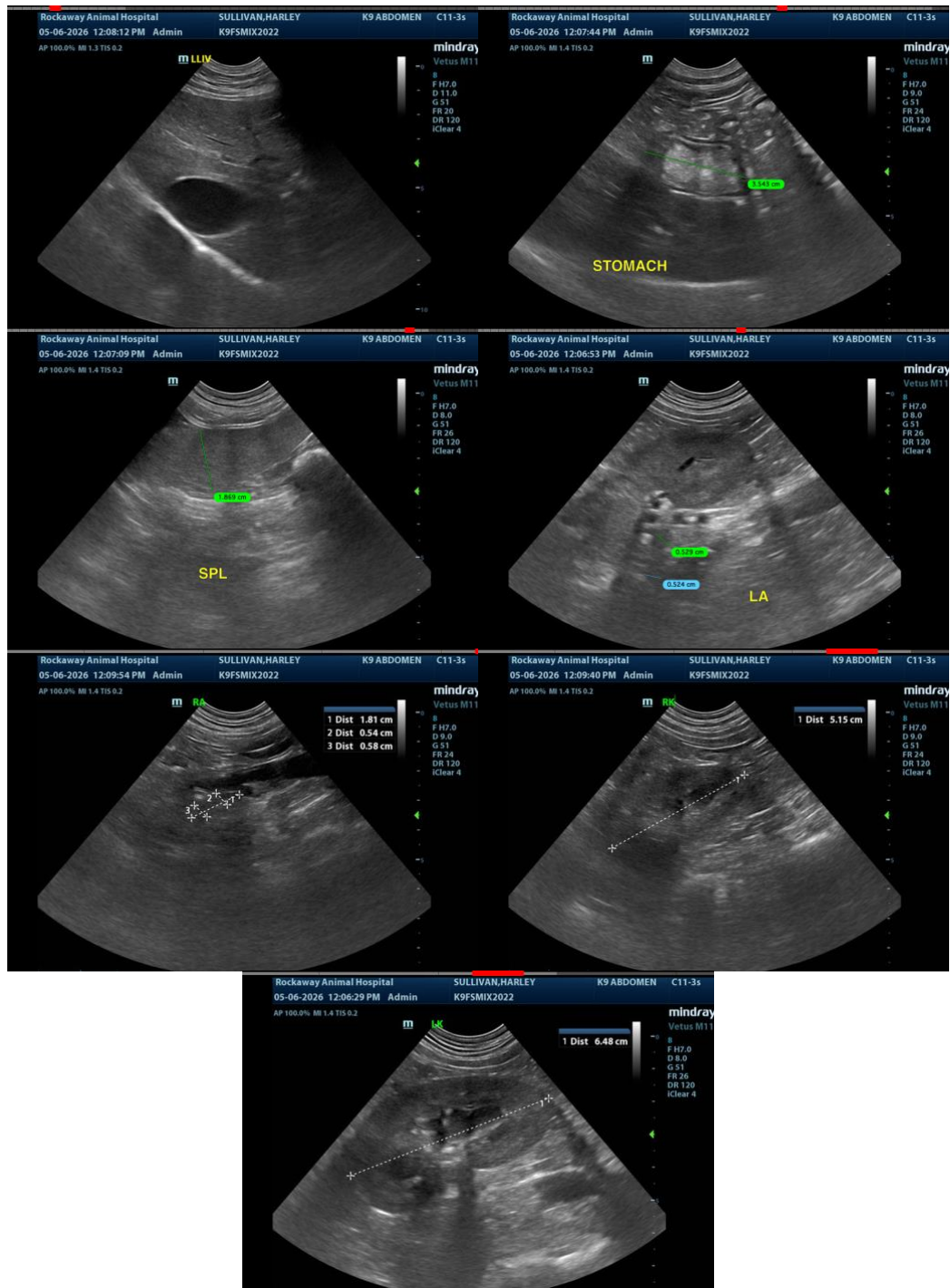
Dr. Maniar

INVOICE

35958

DATE

5/6/26



The information and recommendations provided are based on the images presented by the referring veterinarian/sonographer. No evaluation can be communicated regarding pathology that was not visible in the image/video clips provided.



PATIENT

Harley Sullivan

SPECIES

Canine

BREED

Mix

SEX

Spayed Female

AGE

4

WEIGHT

53.6

INTERPRETED BY

Kathleen A. Sennello
DVM, MS, DACVIM
(SAIM)

IMAGING PERFORMED BY

Jenn

HOSPITAL NAME

Rockaway AH

REFERRING VET

Dr. Maniar

INVOICE

35958

DATE

5/6/26

Thank you for this referral. If the clinical or image interpretation does not parallel your findings or if I can be of any further assistance, please contact me.

Kathleen Sennello DVM, MS, Diplomate ACVIM (Small animal Internal Medicine)

info@sonopath.com