

**DATE PRESENTING CLINICAL SIGNS**

5/5/22 Evaluation of abdomen (pancreas) following persistent low blood glucose readings. No abnormalities noted at home.

PATIENT

Shiloh Hoover Current Medications: None.
Lab Results: 3/24/22- Glucose 42 (Antech) P was NPO prior to blood sampling. 4/14/22- Glucose 57 (in-house) P was fed ~2 hours prior to sampling.
Date of Previous IntraPet Ultrasound: No previous.
SPECIES Sedation: Not required to complete full diagnostic ultrasound.
Canine Stat Report: Not requested.

BREED

Cocker Spaniel

SEX

Spayed Female

AGE

7/4/09

WEIGHT

27.2 Pounds

INTERPRETED BY

Kathleen Sennello DVM,
MS, Diplomate ACVIM
(Small Animal Internal
Medicine)

IMAGING PERFORMED BY

Andi Parkinson RDMS

HOSPITAL NAME

Belvedere Vet Hospital

REFERRING VET

Dr. Moulder

INVOICE

37420

ULTRASONOGRAPHIC EXAMINATION OF THE ABDOMEN**Urinary System**

The urinary bladder is moderately distended with anechoic urine. The Bladder wall, trigone, ureteral papillae and visible urethra (to a depth of 2cm) appear normal with no evidence of wall thickening, mucosal irregularities, masses or cystic calculi.

The prostate is normal in size and shape for this neutered male dog. The parenchyma is homogenous and the external margins are smooth. The prostatic urethra appears normal with no evidence of irregularity, invasion, mass effect or calculi.

The left kidney has a normal shape and size (5.1 cm) with small mineralizations/stones at the corticomedullary junction. Overall echogenicity is normal with adequate corticomedullary distinction and a typical 1:3 cortex:medulla ratio. There is no evidence of perinephric inflammation or effusion. There is no evidence of pyelectasia, nephroliths, infarcts or hydroureter. Renal vasculature is normal.

The right kidney has a normal shape and size (4.86 cm) with non-obstructive nephroliths visualized. Overall echogenicity is normal with adequate corticomedullary distinction and a typical 1:3 cortex:medulla ratio. There is no evidence of perinephric inflammation or effusion. There is no evidence of pyelectasia, infarcts or hydroureter. Renal vasculature is normal.

Adrenal Glands

The left adrenal gland is normal in size measuring 0.69 cm at the caudal pole. It is observed in its normal position cranial to the left renal artery. It is normal in appearance (uniformly hypoechoic) and shape with no evidence of a mass effect.

The right adrenal gland is normal in size measuring 0.66 cm at the caudal pole. It is observed in its normal position between the cranial aspect of the right kidney and the caudal vena cava. It is normal in appearance (uniformly hypoechoic) and shape with no evidence of a mass effect.

Spleen

The spleen is subjectively normal in size. The spleen echotexture is mildly heterogenous and mottled, the splenic capsule is smooth with no irregularities. The blood flow through the hilus and splenic parenchyma appears normal. There are two lesions visualized in the spleen. The first is a mixed echogenic solid mass effect measuring 3.21 cm x 2.33 cm. The second is a well-defined, hypoechoic nodule measuring 1.06 cm x 0.77 cm.

Liver

The liver is subjectively normal in size, and echogenicity with smooth peripheral margins. The parenchyma is homogenous echotexture. The visible portions of the vasculature and biliary tract appear normal. No focal nodules or cystic lesions are observed.

The gallbladder lumen is moderately distended. The wall of the gall bladder is not thickened and has a smooth mucosal surface. Luminal contents are primarily anechoic. The cystic and common bile ducts are normal/not visible.

Gastrointestinal

The stomach contains minimal luminal contents. It measures at a normal thickness of <0.7cm with some variability due to the presence of rugal folds. The distinction of the gastric wall layers is adequate and there is no impression of reduced peristaltic activity. No masses or focal lesions were observed.

The visualized areas of duodenum, jejunum and ileum have a relatively uniform diameter with minimal fluid distension. Wall thickness is normal. Bowel loops follow a curvilinear path with distinct wall layering maintaining the typical 1:3 muscularis:mucosa layer ratio. Jejunum wall measured 0.35 cm. Visualized peristalsis appears appropriate. There were no focal lesions consistent with obstruction or a mass effect observed.

The ileocecal junction was visualized and exhibited normal intact wall layering and is subjectively of normal thickness. Sections of colon are visualized with formed fecal material and gas shadowing distally. There is no observed focal or generalized colon wall thickening or loss of layering.

Pancreas

The pancreas is prominent and mottled compared to the surrounding isoechoic mesentery. There are two ill-defined, hypoechoic lesions visualized in the pancreas, one measuring 0.26 cm, the other measuring 0.60 cm x 0.43 cm. There is no evidence of regional mesenteric inflammation or fluid.

Free Abdomen

Evaluation of the peritoneal cavity did not reveal any evidence of effusion, or subjective lymphadenomegaly. The Medial iliac nodes appear normal and there was no evidence of a caudal aortic thrombus at the bifurcation. The omentum is of normal uniform echogenicity.

Other

A brief view of the heart was submitted. No significant pericardial effusion was seen.

ULTRASONOGRAPHIC FINDINGS

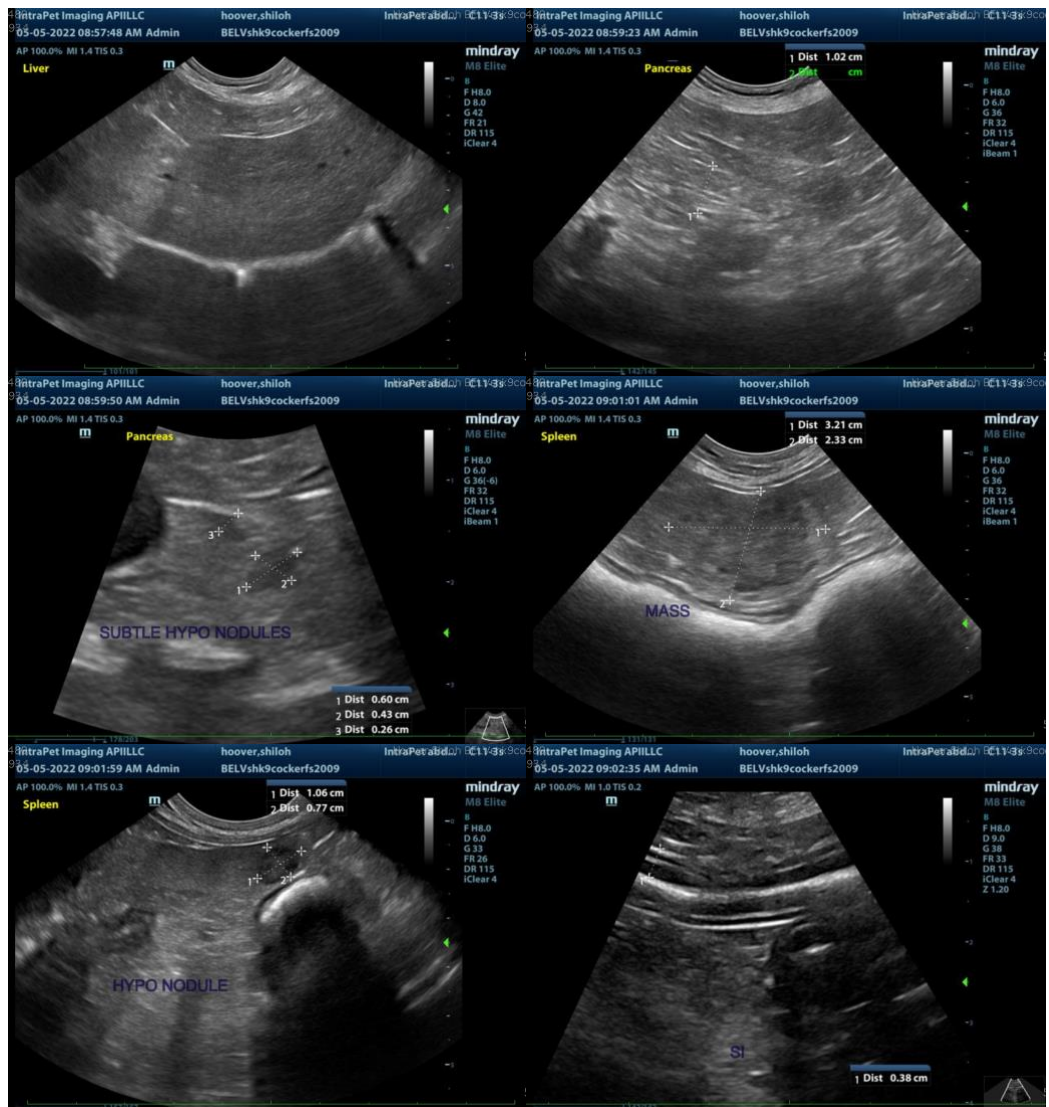
- One mixed echogenic mass effect and one hypoechoic nodule visualized with the spleen – These lesions could represent a benign or neoplastic process. Consider splenectomy or fine needle aspirates.
- Mottled pancreas with two ill-defined, hypoechoic nodules – The pancreas overall has a slightly mottled/nodular appearance with no surrounding inflammation. These changes can be seen with previous episodes of pancreatic inflammation, and in this situation, if insulin levels are elevation, these could represent insulin secreting tumors.
- Non-obstructive nephroliths/mineralizations in both kidneys – The hyperechoic mineralized foci observed at the corticomedullary junction of the left/right kidney are consistent with small, non-obstructive nephroliths.

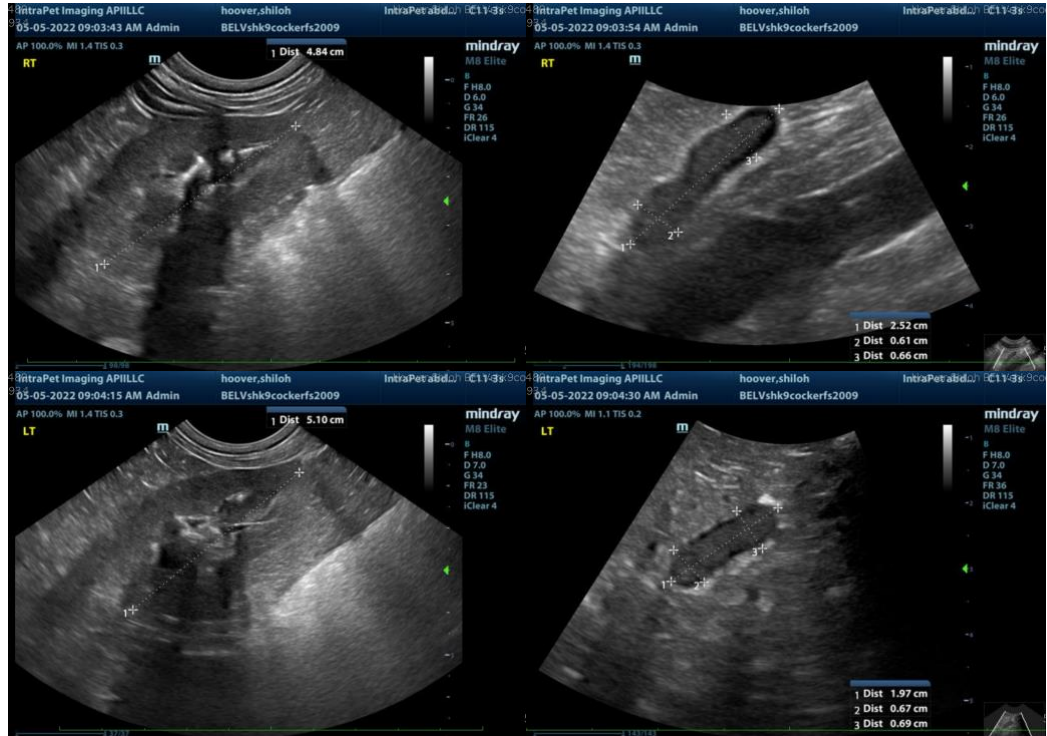
INTERPRETATION OF THE FINDINGS & FURTHER RECOMMENDATIONS

Initial evaluation for hypoglycemia should include a liver function test and screening for Addison's disease (baseline cortisol should be fine). Additionally, insulin to glucose ratio levels when the blood sugar is <40. If

insulin levels are elevated, this is an indicator of an insulin secreting tumor. These most commonly occur in the pancreas, but can be seen in the liver or spleen as well. Based on the presence of multiple mass lesions, I would consider a contrast CT scan to get better detail on the pancreatic lesions visualized and to screen for more subtle metastatic lesions, keeping in mind that all of these lesions could be benign. Some could be incidental or there could be more than one type of neoplastic process present.

Based on the CT scan findings and 3-view thoracic radiographs, I would consider referral to a veterinary surgeon. If insulin levels are elevated, then I would recommend removal of the pancreatic nodules and splenectomy, although recommendations may change based on CT scan results. If a CT scan is not possible, then consider referral to a veterinary surgeon for exploratory, likely splenectomy +/- removal of the pancreatic nodules (depending on insulin levels).





The information and recommendations provided are based on the images presented by the referring veterinarian/sonographer. No evaluation can be communicated regarding pathology that was not visible in the image/video clips provided.

Thank you for this referral. If the clinical or image interpretation does not parallel your findings or if I can be of any further assistance please contact me.

Kathleen Sennello DVM,MS, Diplomate ACVIM (Small animal Internal Medicine)
kathleen.sennello@sonopath.com