

**DATE PRESENTING CLINICAL SIGNS**

5/5/22 Weight loss, PU/PD, excessive to normal appetite. Chronic R torn CCL.

PATIENT Current Medications: Heartgard and Nexgard.

Chloe Wyman

Lab Results: Bloodwork showed mildly elevated ALP 900, mildly elevated amylase and lipase, hyperalbuminemia, elevated UPC 1.4, USG 1.020, hematuria.
Radiographs: Small liver.

SPECIES Date of Previous IntraPet Ultrasound: No previous.

Canine

Sedation: Not required to complete full diagnostic ultrasound.
Stat Report: Not requested.

BREED ULTRASONOGRAPHIC EXAMINATION OF THE ABDOMEN**Urinary System****SEX**

Spayed Female

The urinary bladder is moderately distended with anechoic urine. The Bladder wall, trigone, ureteral papillae and visible urethra (to a depth of 2cm) appear normal with no evidence of wall thickening, mucosal irregularities, masses or cystic calculi.

AGE

4/30/13

The left kidney has a normal shape and size (7.24 cm). Overall echogenicity is normal with adequate corticomedullary distinction and a typical 1:3 cortex:medulla ratio. There is no evidence of perinephric inflammation or effusion. There is no evidence of pyelectasia, nephroliths, infarcts or hydroureter. Renal vasculature is normal.

WEIGHT

58 Pounds

The right kidney has a normal shape and size (6.4 cm). Overall echogenicity is normal with adequate corticomedullary distinction and a typical 1:3 cortex:medulla ratio. There is no evidence of perinephric inflammation or effusion. There is no evidence of pyelectasia, nephroliths, infarcts or hydroureter. Renal vasculature is normal.

INTERPRETED BY

Kathleen Sennello DVM,
MS, Diplomate ACVIM
(Small Animal Internal
Medicine)

Adrenal Glands

The left adrenal gland is normal in size measuring 0.62 cm at the caudal pole. It is observed in its normal position cranial to the left renal artery. It is normal in appearance (uniformly hypoechoic) and shape with no evidence of a mass effect.

IMAGING PERFORMED BY

Stephanie Pearce
RDCS, RVT

The right adrenal gland is normal in size measuring 0.72 cm at the caudal pole. It is observed in its normal position between the cranial aspect of the right kidney and the caudal vena cava. It is normal in appearance (uniformly hypoechoic) and shape with no evidence of a mass effect.

Spleen**HOSPITAL NAME**

North Laurel AH

The spleen is subjectively normal in size, echotexture is homogenous, and the splenic capsule is smooth with no irregularities. The blood flow through the hilus and splenic parenchyma appears normal. No focal parenchymal abnormalities are visualized.

REFERRING VET

Dr. Nelson

Liver

The liver is subjectively normal in size, and echogenicity with smooth peripheral margins. The parenchyma is mildly heterogenous in echotexture with subtle, indistinct focal mottling. The visible portions of the vasculature and biliary tract appear normal. No focal nodules or cystic lesions are observed.

INVOICE

37424

The gall bladder lumen is moderately distended. The wall of the gall bladder is not thickened and has a smooth mucosal surface. There is a moderate amount of non-organized echogenic debris. The cystic and common bile ducts are normal/not visible.

Gastrointestinal

The stomach contains minimal luminal contents. It measures at a normal thickness of <0.7cm with some variability due to the presence of rugal folds. The distinction of the gastric wall layers is adequate and there is no impression of reduced peristaltic activity. No masses or focal lesions were observed.

The visualized areas of duodenum, jejunum and ileum have a relatively uniform diameter with minimal fluid distension. Wall thickness is normal. Bowel loops follow a curvilinear path with distinct wall layering maintaining the typical 1:3 muscularis:mucosa layer ratio. The duodenum measured as normal (between 0.3-0.5cm in wall thickness) and the jejunum measured as normal (between 0.2-0.47cm.) Visualized peristalsis appears appropriate. There were no focal lesions consistent with obstruction or a mass effect observed.

The ileocecal junction was visualized and exhibited normal intact wall layering and is subjectively of normal thickness. Sections of colon are visualized with formed fecal material and gas shadowing distally. There is no observed focal or generalized colon wall thickening or loss of layering.

Pancreas

The pancreas is normal and isoechoic to surrounding mesentery. There is no evidence of nodules or cystic lesions. There is no evidence of regional mesenteric inflammation or fluid.

Free Abdomen

Evaluation of the peritoneal cavity did not reveal any evidence of effusion, or subjective lymphadenomegaly. The Medial iliac nodes appear normal and there was no evidence of a caudal aortic thrombus at the bifurcation. The omentum is of normal uniform echogenicity.

ULTRASONOGRAPHIC FINDINGS

- Mild gallbladder debris – The significance of the aggregated gallbladder sludge is unclear. This could represent an early mucocele, cholestasis, or may be secondary to fasting.
- Mildly heterogeneous liver – The diffuse hepatic changes are non-specific and could be consistent with vacuolar hepatopathy, nodular hyperplasia, inflammatory/immune-mediated disease, fibrosis, extramedullary hematopoiesis, toxic hepatopathy (e.g., copper), infiltrative neoplasia (less likely) or other hepatopathy.

INTERPRETATION OF THE FINDINGS & FURTHER RECOMMENDATIONS

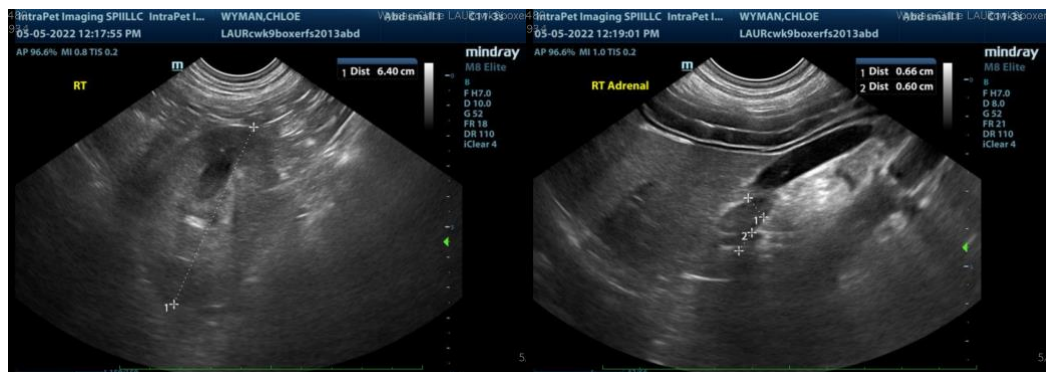No significant lesions are visualized on today's exam to explain the symptoms described in the history. Based on the liver enzyme elevations reported, I would consider a liver function test, screening for Leptospirosis, and if any signs of Cushing's are present, I would consider adrenal function testing, although the adrenal glands appear relatively normal. I would also consider a fine needle aspirate of the liver.

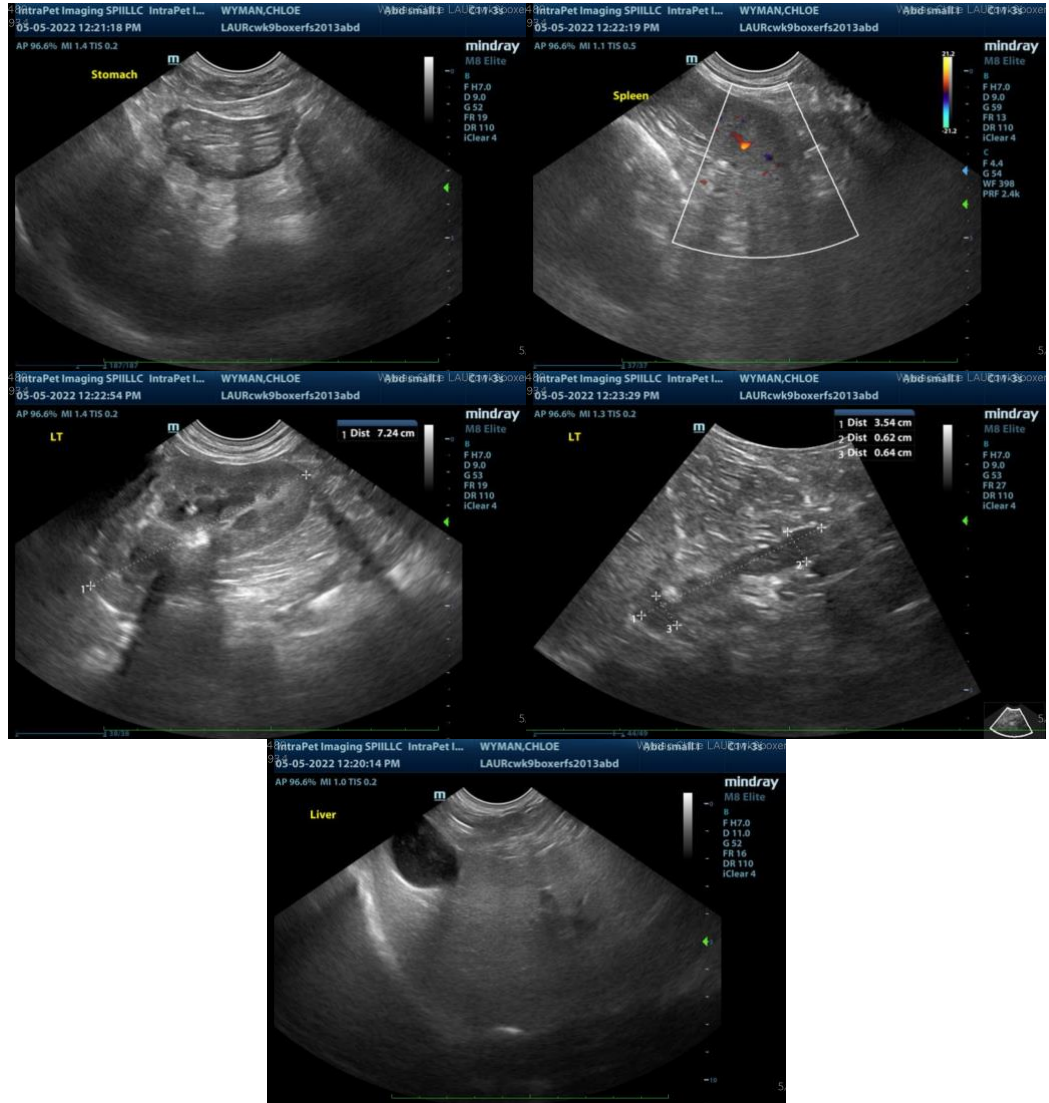
In terms of the PU/PD, I would have the owner quantitate water intake to confirm its presence. If confirmed, and none of the above recommendations result in a diagnosis, then I typically will go through a list of differentials for PU/PD to try to rule things in/out. Some issues such as early renal disease, Cushing's disease, behavioral disease, neurologic, dietary, electrolyte disturbances, etc. are not able to be diagnosed with ultrasound alone. I will provide a differential list below. The top 10 differentials can be ruled in/out with routine bloodwork, urinalysis and culture. Several more can be evaluated with a good history and imaging. Unfortunately, as you work your way down the list, the differentials become harder to definitively diagnosis.

- (1) Hyperadrenocorticism (may be a mixed primary PU and PD)
- (2) Hypoadrenocorticism (either Addison's or hypocortisolism)
- (3) Hypercalcemia
- (4) Diabetes Mellitus
- (5) Liver Disease (hepatic encephalopathy may be a mixed primary PU and PD)
- (6) Pyelonephritis
- (7) Leptospirosis (can present without azotemia)
- (8) Chronic Renal Disease/Renal Failure (can present pre-azotemic, especially in dogs, but expect the BUN & creatinine not to be at the low end of the reference range)
- (9) Hyperthyroidism
- (10) Hypokalemia
- (11) Pyometra (including stump pyometra in spayed dogs)
- (12) Renal Tubular Diseases (glycosuria or Fanconi & Fanconi-like syndromes or RTA)
- (13) Chronic Partial Urinary Obstruction or Post-Obstructive Diuresis
- (14) Iatrogenic Disease due to medications (diuretics, phenobarbital, KBr; diets either high in salt [such as S/D] or very low in protein (such as U/D))
- (15) Pheochromocytoma
- (16) Polycythemia
- (17) Hypertension Acromegaly (expect these patients to have diabetes)
- (18) Paraneoplastic Syndromes (particularly splenic hemangiosarcoma?)
- (19) Pericardial Effusion
- (20) Atypical Cushing's and SARDS Psychogenic Polydipsia (as in a true behavior disorder with a compulsive element)
- (21) Primary Non-Medical Polydipsia (aka "I drink a lot because I like it or I engage in activities that promote it, but that doesn't mean I'm sick")
- (22) Psychogenic Polydipsia (as in a true behavior disorder with a compulsive element)
- (23) Acromegaly (expect these patients to have diabetes)
- (24) Primary Nephrogenic Diabetes Insipidus (Congenital Nephrogenic Diabetes Insipidus, other diseases that cause primary PU other than Congenital Diabetes Insipidus would be considered Acquired Nephrogenic Diabetes Insipidus)
- (25) Central Diabetes Insipidus

**Keep in mind that diabetes insipidus is a VERY rare disorder and that water deprivation tests are rarely/if ever recommended-if possible consider referral to an internal medicine specialist if reaching that point.

Consider three view thoracic radiographs to rule out concurrent thoracic disease/involvement.





The information and recommendations provided are based on the images presented by the referring veterinarian/sonographer. No evaluation can be communicated regarding pathology that was not visible in the image/video clips provided.

Thank you for this referral. If the clinical or image interpretation does not parallel your findings or if I can be of any further assistance please contact me.

Kathleen Sennello DVM,MS, Diplomate ACVIM (Small animal Internal Medicine)
 kathleen.sennello@sonopath.com