

**DATE PRESENTING CLINICAL SIGNS**

5/5/22

DM diagnosed in Dec 2021, on Humulin N 10U BID, weight loss 24lbs since Dec. Anorexia, lethargy last 2 days, inconsistent insulin dosing per o.

PATIENT

Annabelle McGuern

Current Medications: Humulin N 10U BID since Dec 2021.

Lab Results: DKA dx 5/3/22- hospitalized pet.

Date of Previous IntraPet Ultrasound: No previous.

Sedation: Not required to complete full diagnostic ultrasound.

Stat Report: Not requested.

SPECIES

Canine

ULTRASONOGRAPHIC EXAMINATION OF THE ABDOMEN**BREED**

Catahoula Leopard Dog

Urinary System

The urinary bladder is moderately distended with anechoic urine. The Bladder wall, trigone, ureteral papillae and visible urethra (to a depth of 2cm) appear normal with no evidence of wall thickening, mucosal irregularities, masses or cystic calculi.

SEX

Spayed Female

The left kidney has a normal shape and size (8.23 cm). Overall echogenicity is normal with adequate corticomedullary distinction and a typical 1:3 cortex:medulla ratio. There is no evidence of perinephric inflammation or effusion. There is no evidence of pyelectasia, nephroliths, infarcts or hydroureter. Renal vasculature is normal.

AGE

8/28/11

The right kidney has a normal shape and size (7.3 cm). Overall echogenicity is normal with adequate corticomedullary distinction and a typical 1:3 cortex:medulla ratio. There is no evidence of perinephric inflammation or effusion. There is no evidence of pyelectasia, nephroliths, infarcts or hydroureter. Renal vasculature is normal.

WEIGHT

60 Pounds

INTERPRETED BY

Kathleen Sennello DVM,
MS, Diplomate ACVIM
(Small Animal Internal
Medicine)

Adrenal Glands

The left adrenal gland is normal/borderline large in size measuring 0.80 cm at the caudal pole. It is observed in its normal position cranial to the left renal artery. It is normal in appearance (uniformly hypoechoic) and shape with no evidence of a mass effect.

The right adrenal gland is normal/borderline large in size measuring 0.97 cm at the caudal pole. It is observed in its normal position between the cranial aspect of the right kidney and the caudal vena cava. It is normal in appearance (uniformly hypoechoic) and shape with no evidence of a mass effect.

IMAGING PERFORMED BY

Andi Parkinson RDMS

Spleen

The spleen is subjectively normal in size, echotexture is homogenous, and the splenic capsule is smooth with no irregularities. The blood flow through the hilus and splenic parenchyma appears normal. No focal parenchymal abnormalities are visualized.

HOSPITAL NAME

Eastern AH

Liver

The liver is large in size with smooth peripheral margins. The parenchyma is hyperechoic and homogenous in echotexture. The visible portions of the vasculature and biliary tract appear normal. No focal nodules or cystic lesions are observed.

REFERRING VET

Dr. Sole

INVOICE

37417

The gall bladder lumen is moderately distended. The wall of the gall bladder is not thickened and has a smooth mucosal surface. There is a moderate amount of non-organized echogenic debris. The cystic and common bile ducts are normal/not visible.

Gastrointestinal

The stomach contains minimal luminal contents. It measures at a normal thickness of <0.7cm with some variability due to the presence of rugal folds. The distinction of the gastric wall layers is adequate and there is no impression of reduced peristaltic activity. No masses or focal lesions were observed.

The visualized areas of duodenum, jejunum and ileum have a relatively uniform diameter with minimal fluid distension. Wall thickness is normal. Bowel loops follow a curvilinear path with distinct wall layering maintaining the typical 1:3 muscularis:mucosa layer ratio. Small intestinal wall measured 0.46 cm. Visualized peristalsis appears appropriate. There were no focal lesions consistent with obstruction or a mass effect observed.

The ileocecal junction was visualized and exhibited normal intact wall layering and is subjectively of normal thickness. Sections of colon are visualized with formed fecal material and gas shadowing distally. There is no observed focal or generalized colon wall thickening or loss of layering.

Pancreas

The pancreas is large and hypoechoic to surrounding mesentery. There is no evidence of nodules or cystic lesions. There is evidence of regional mesenteric inflammation. Consistent with moderate pancreatitis.

Free Abdomen

Evaluation of the peritoneal cavity did not reveal any evidence of effusion, or subjective lymphadenomegaly. The Medial iliac nodes appear normal and there was no evidence of a caudal aortic thrombus at the bifurcation. The mesentery is hyperechoic surrounding the pancreas.

PRIMARY FINDINGS

- Hypoechoic pancreas surrounded by hyperechoic mesentery – The pancreatic changes are most consistent with moderate pancreatitis/pancreatic inflammation. Recommend fPLI testing and continued monitoring for improvement or possible development of a pancreatic abscess. Consider fine needle aspirate if not improving.
- Large hyperechoic liver – The diffuse hepatic changes are non-specific and can be seen with vacuolar hepatopathy, reactive change, nodular hyperplasia or, less likely, inflammatory/immune-mediated disease, infiltrative neoplasia, or other hepatopathy.
- Moderate gallbladder debris – The significance of the aggregated gallbladder sludge is unclear. This could represent an early mucocele, cholestasis, or may be secondary to fasting.

SECONDARY FINDINGS

- Borderline bilateral adrenomegaly – The bilateral adrenomegaly could be consistent with bilateral hyperplasia (e.g., secondary to pituitary-dependent hyperadrenocorticism), bilateral infiltrative neoplasia, inflammatory adrenal disease, other. Correlation with clinical findings is recommended.

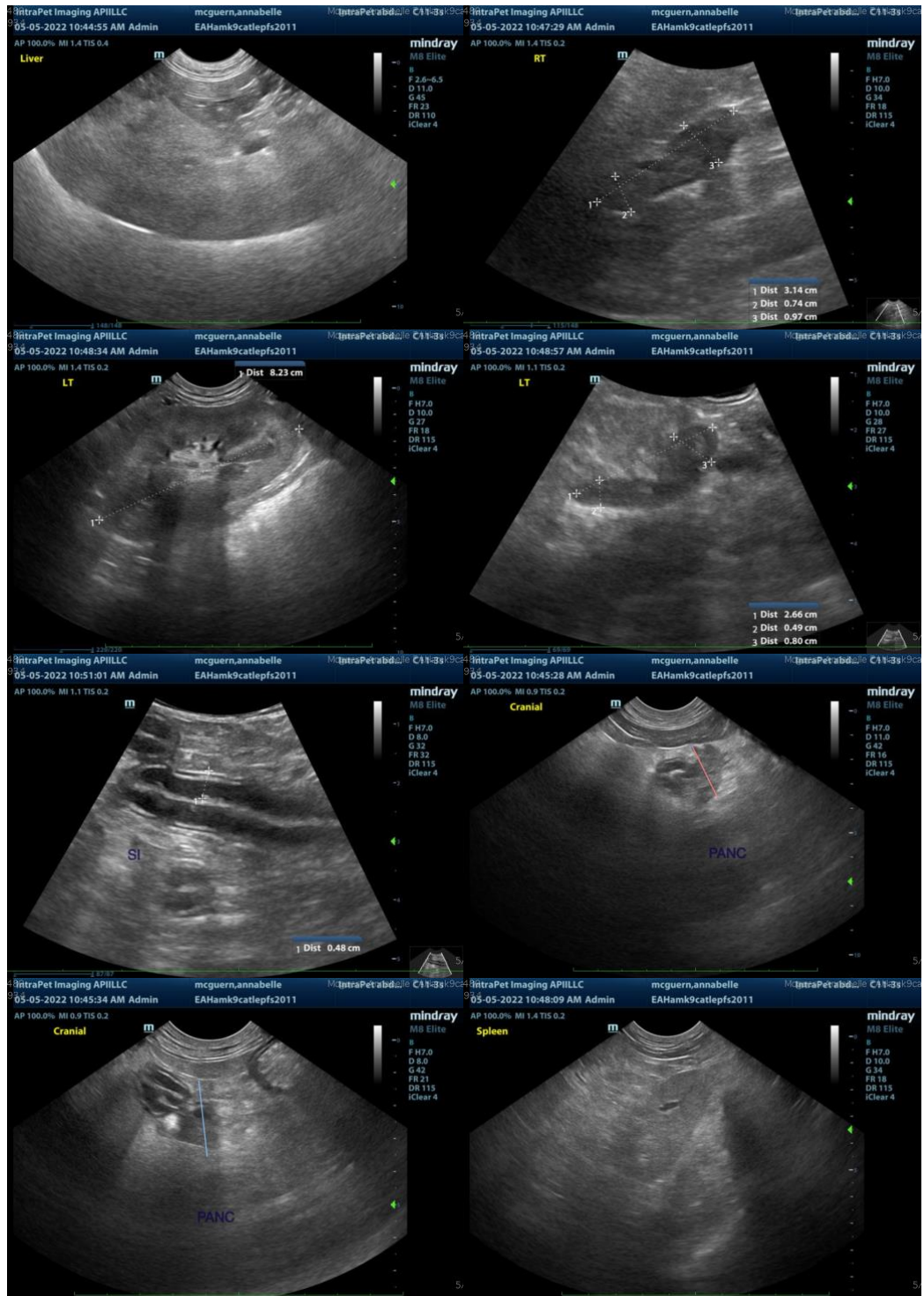
INTERPRETATION OF THE FINDINGS & FURTHER RECOMMENDATIONS

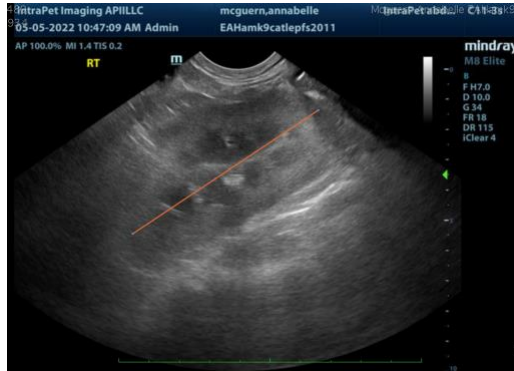The pancreas appears hypoechoic and surrounded by hyperechoic mesentery. These findings are most consistent with moderate pancreatitis. Correlate with a quantitative PLI level and recommend treatment for pancreatitis.

The liver is hyperechoic and large. This is a common finding associated with diabetic hepatopathy.

Additionally, both adrenal glands are borderline large in size. If other signs of Cushing's are present (this can

be difficult with diabetes, as many of the symptoms overlap), you could consider adrenal function testing (ACTH stimulation test) when Annabelle is feeling better.





The information and recommendations provided are based on the images presented by the referring veterinarian/sonographer. No evaluation can be communicated regarding pathology that was not visible in the image/video clips provided.

Thank you for this referral. If the clinical or image interpretation does not parallel your findings or if I can be of any further assistance please contact me.

Kathleen Sennello DVM,MS, Diplomate ACVIM (Small animal Internal Medicine)
kathleen.sennello@sonopath.com