

**DATE PRESENTING CLINICAL SIGNS**

5/4/23

Patient presented for 24 hour history of lethargy and vomiting. Patient has had a history of chronic intermittent vomiting for several years and is currently on a hydrolyzed protein diet. Physical examination revealed a mildly distended abdomen. aFAST scan revealed peritoneal effusion. Serosanguinous fluid was aspirated from the abdomen.

**PATIENT**

Scotch Sternberg

**SPECIES**

Feline

Current Medications: Felimazole 2.5mg BID

Lab Results: CBC/Chem: stress leukogram, remainder unremarkable

Radiographs: multiple small nodules in the caudal lung field.

Date of Previous IntraPet Ultrasound: No previous.

Sedation: Not required to complete full diagnostic ultrasound.

Stat Report: STAT requested.

Imaging Performed By: Rachel Brillhart, RDMS.

**BREED**

DSH

**ULTRASONOGRAPHIC EXAMINATION OF THE ABDOMEN****SEX**

Neutered Male

**Urinary System**

The urinary bladder is moderately distended with anechoic urine. The Bladder wall, trigone, ureteral papillae and visible urethra (to a depth of 2cm) appear normal with no evidence of wall thickening, mucosal irregularities, masses or cystic calculi.

**AGE**

1/14/11

The left kidney has a normal shape and size (3.71 cm). Overall echogenicity is normal with adequate corticomedullary distinction and a typical 1:3 cortex:medulla ratio. There is no evidence of focal perinephric inflammation or effusion. There is no evidence of pyelectasia, nephroliths, infarcts or hydroureter. Renal vasculature is normal.

**WEIGHT**

11.5 Pounds

The right kidney has a normal shape and size (3.99 cm). Overall echogenicity is normal with adequate corticomedullary distinction and a typical 1:3 cortex:medulla ratio. There is no evidence of focal perinephric inflammation or effusion. There is no evidence of pyelectasia, nephroliths, infarcts or hydroureter. Renal vasculature is normal.

**INTERPRETED BY**

Kathleen Sennello DVM,  
MS, Diplomate ACVIM  
(Small Animal Internal  
Medicine)

**Adrenal Glands**

The region of left adrenal (Cranial to left renal artery) is unremarkable but the adrenal is not distinctly visualized. No evidence of a mass effect is visualized.

**HOSPITAL NAME**

Eastern AH

The right adrenal gland is normal in size measuring 0.47 cm at the caudal pole. It is observed in its normal position between the cranial aspect of the right kidney and the caudal vena cava. It is normal in appearance (uniformly hypoechoic) and shape with no evidence of a mass effect.

**REFERRING VET**

Dr. Wu

**Spleen**

The spleen is subjectively normal in size (0.89 cm), echotexture is homogenous, and the splenic capsule is smooth with no irregularities. The blood flow through the hilus and splenic parenchyma appears normal. No focal parenchymal abnormalities are visualized.

**INVOICE**

47087

**Liver**

The liver is large and irregular. The parenchyma is heterogenous in echotexture with subtle, indistinct focal mottling. The visible portions of the vasculature and biliary tract appear normal. There are numerous irregular mass effects associated with the liver. There is an irregular mixed echogenic mass effect visualized on the right side of the liver measuring 2.89 cm x 3.17 cm, and a very large, mixed echogenic, mildly cystic/cavitated mass effect on the left side of the liver measuring 7.17 cm x 4.49 cm.

The gallbladder lumen is moderately distended. The wall of the gall bladder is not thickened and has a smooth mucosal surface. Luminal contents are mild and primarily anechoic. The cystic and common bile ducts are normal/not visible.

### ***Gastrointestinal***

The stomach contains minimal luminal contents. It measures at a normal thickness of <0.7cm with some variability due to the presence of rugal folds. The distinction of the gastric wall layers is adequate and there is no impression of reduced peristaltic activity. No masses or focal lesions were observed.

The visualized areas of duodenum, jejunum and ileum have a uniform diameter with minimal fluid distension. Wall thickness is increased. Bowel loops follow a typical curvilinear path. Some areas have reduced detail of wall layering. Jejunum wall measures 0.46 cm. Duodenum wall measures 0.54 cm. There is no mucosal speckling observed. Visualized peristalsis appears appropriate. There were no focal lesions consistent with obstruction or a mass effect observed.

The ileocecal junction was visualized and exhibited normal intact wall layering and is subjectively of normal thickness. Sections of colon are visualized with formed fecal material and gas shadowing distally. There is no observed focal or generalized colon wall thickening or loss of layering.

### ***Pancreas***

The pancreas is normal and isoechoic to surrounding mesentery. There is no evidence of nodules or cystic lesions. There is no evidence of regional mesenteric inflammation or fluid.

### ***Free Abdomen***

There is a large amount of free abdominal fluid. No lymphadenopathy. The omentum is diffusely hyperechoic.

## **ULTRASONOGRAPHIC FINDINGS**

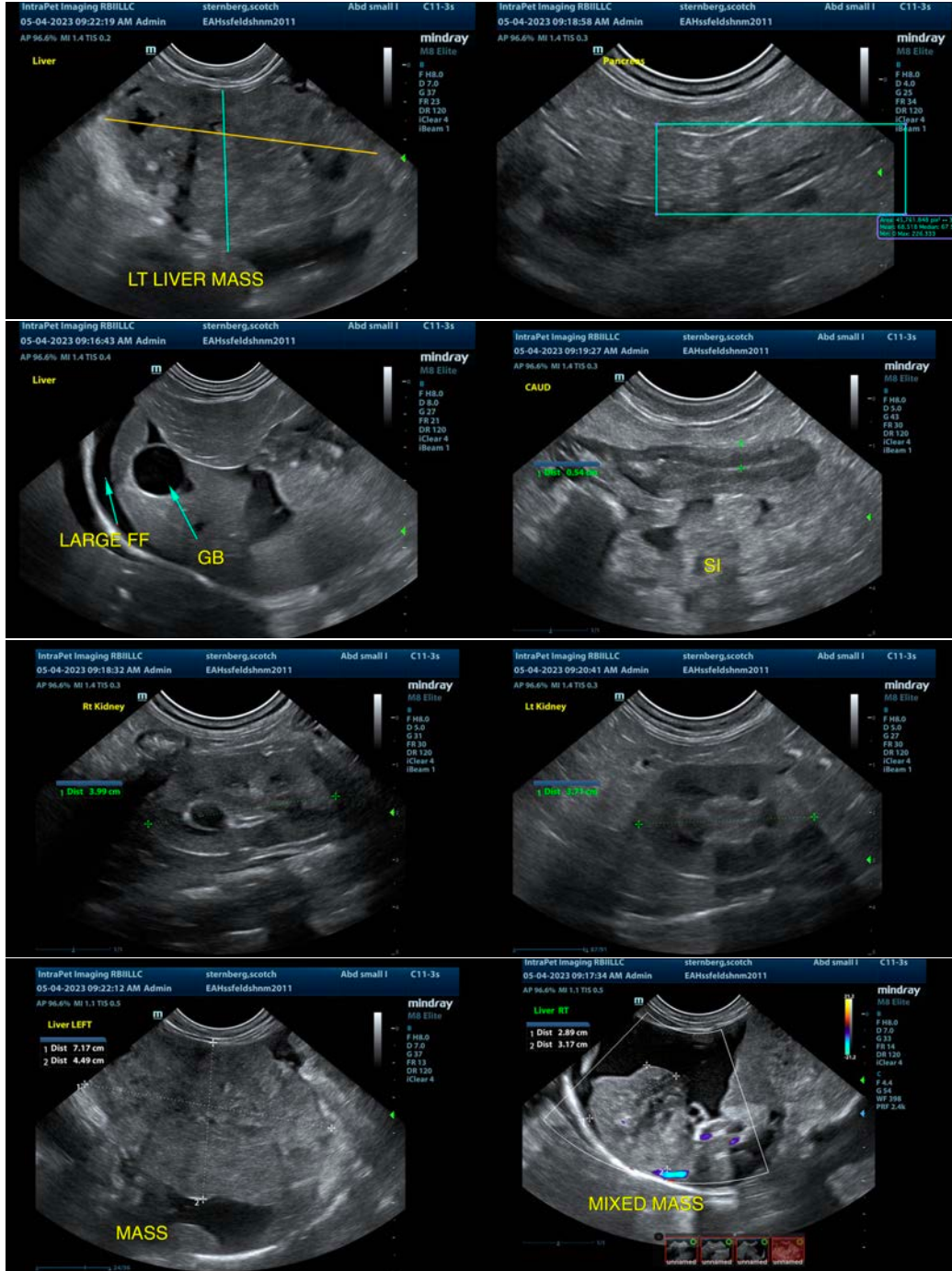
- Multiple mixed echogenic mass effects visualized associated with the liver – The appearance of these lesions is concerning for a neoplastic process (carcinoma, hemangiosarcoma, less likely adenoma, other).
- Thickened small intestine with decreased detail of wall layering – Findings could be secondary to edema from the large amount of free fluid present or due to infiltrative disease (round cell neoplasia, severe inflammation, other).
- Large volume free abdominal fluid – Recommend fluid analysis and cytology.

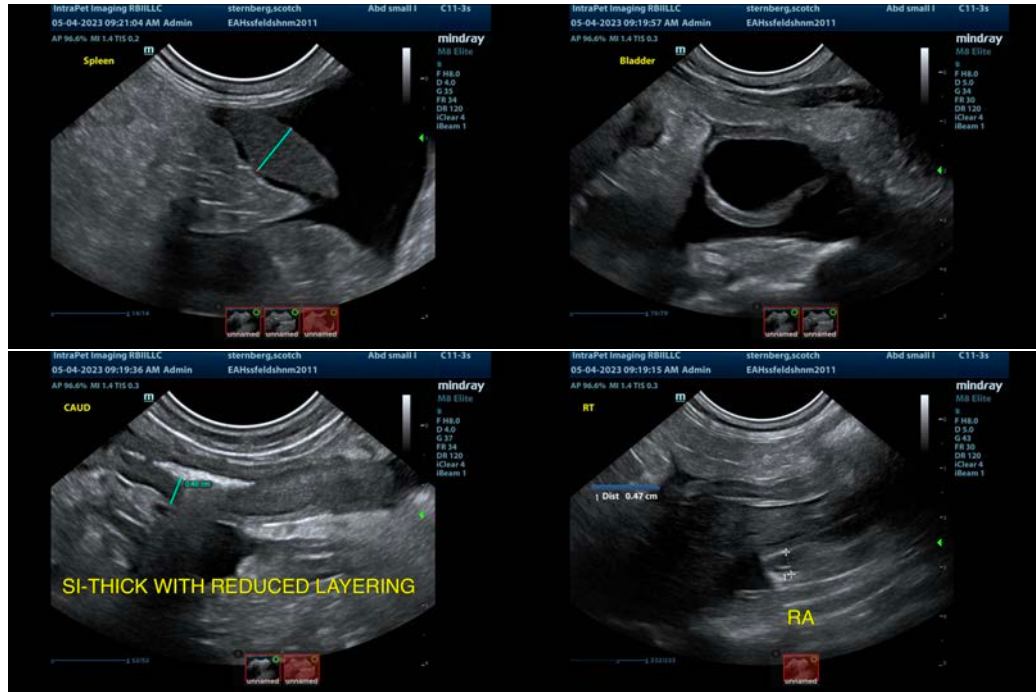
## **INTERPRETATION OF THE FINDINGS & FURTHER RECOMMENDATIONS**

There are at least two large, irregular mixed echogenic mass effects associated with the liver. The appearance of these lesions is concerning for an underlying neoplastic process. Recommend a fine needle aspirate of the hepatic mass and fluid analysis and cytology of the fluid. The presence of multiple lesions is concerning for possible metastatic disease. If possible surgical intervention is desired, a contrast CT scan could be evaluated to look at your options. There is some normal appearing liver present, but the abnormal tissue is extensive.

Additionally, much of the small bowel appears somewhat thickened with reduced detail of wall layering. Some of this could be secondary to the edema and fluid present, but primary or metastatic GI disease is also possible. If fluid analysis and cytology is not helpful, then biopsies of the GI tract would likely be necessary to know more.

Recommend three view thoracic radiographs to evaluate for possible concurrent thoracic disease/involvement.





The information and recommendations provided are based on the images presented by the referring veterinarian/sonographer. No evaluation can be communicated regarding pathology that was not visible in the image/video clips provided.

Thank you for this referral. If the clinical or image interpretation does not parallel your findings or if I can be of any further assistance please contact me.

Kathleen Sennello DVM,MS, Diplomate ACVIM (Small animal Internal Medicine)  
kathleen.sennello@sonopath.com