

**DATE PRESENTING CLINICAL SIGNS**

5/4/22 Screening ultrasound. No discharge from penis and no obvious dermatitis on prepuce= suspect atopy related.

**PATIENT**

Rain Hulbert

Current Medications: Doxycycline 100mg ½ SID for prostatitis- started abx on 4/7. No meds as of now.  
 Lab Results: Recent UA results that are unchanged as far as hematuria and now there are casts and struvite crystals and bilirubin. Recommended US to r/o neoplasia, polyp, etc.

Date of Previous IntraPet Ultrasound: No previous.

**SPECIES**

Canine

Sedation: Not required to complete full diagnostic ultrasound.  
 Stat Report: Not requested.

**BREED**

Cocker Spaniel

**ULTRASONOGRAPHIC EXAMINATION OF THE ABDOMEN****Urinary System**

The urinary bladder is moderately distended with anechoic urine. The Bladder wall, trigone, ureteral papillae and visible urethra (to a depth of 2cm) appear normal with no evidence of wall thickening, mucosal irregularities, masses or cystic calculi.

**SEX**

Intact Male

The prostate is large in size (2.6 cm x 2.5 cm) but has a regular shape with smooth external margins. The parenchyma is hyperechoic. No discrete focal lesions are present. The prostatic urethra appears normal with no evidence of irregularity, invasion, mass effect or calculi.

**AGE**

12/11/17

The left kidney has a normal shape and size (5.41 cm). Overall echogenicity is normal with adequate corticomedullary distinction and a typical 1:3 cortex:medulla ratio. There is no evidence of perinephric inflammation or effusion. There is no evidence of pyelectasia, nephroliths, infarcts or hydroureter. Renal vasculature is normal.

**WEIGHT**

20 Pounds

The right kidney has a normal shape and size (4.92 cm). Overall echogenicity is normal with adequate corticomedullary distinction and a typical 1:3 cortex:medulla ratio. There is no evidence of perinephric inflammation or effusion. There is no evidence of pyelectasia, nephroliths, infarcts or hydroureter. Renal vasculature is normal.

**INTERPRETED BY**

Kathleen Sennello DVM,  
 MS, Diplomate ACVIM  
 (Small Animal Internal  
 Medicine)

**Adrenal Glands**

The left adrenal gland is normal in size measuring 0.50 cm at the caudal pole. It is observed in its normal position cranial to the left renal artery. It is normal in appearance (uniformly hypoechoic) and shape with no evidence of a mass effect.

**IMAGING PERFORMED BY**

Rachel Brillhart RDMS

The right adrenal gland is normal in size measuring 0.56 cm at the caudal pole. It is observed in its normal position between the cranial aspect of the right kidney and the caudal vena cava. It is normal in appearance (uniformly hypoechoic) and shape with no evidence of a mass effect.

**HOSPITAL NAME**

Eldersburg VH

**REFERRING VET**

Dr. James

**Spleen**

The spleen is subjectively normal in size, echotexture is homogenous, and the splenic capsule is smooth with no irregularities. The blood flow through the hilus and splenic parenchyma appears normal. No focal parenchymal abnormalities are visualized.

**INVOICE**

37383

**Liver**

The liver is subjectively normal in size, and echogenicity with smooth peripheral margins. The parenchyma is homogenous echotexture. The visible portions of the vasculature and biliary tract appear normal. No focal nodules or cystic lesions are observed.

The gallbladder lumen is moderately distended. The wall of the gall bladder is not thickened and has a smooth mucosal surface. Luminal contents are primarily anechoic. The cystic and common bile ducts are normal/not visible.

### ***Gastrointestinal***

The stomach contains minimal luminal contents. It measures at a normal thickness of <0.7cm with some variability due to the presence of rugal folds. The distinction of the gastric wall layers is adequate and there is no impression of reduced peristaltic activity. No masses or focal lesions were observed.

The visualized areas of duodenum, jejunum and ileum have a relatively uniform diameter with minimal fluid distension. Wall thickness is normal. Bowel loops follow a curvilinear path with distinct wall layering maintaining the typical 1:3 muscularis:mucosa layer ratio. The duodenum measured as normal (between 0.3-0.5cm in wall thickness) and the jejunum measured as normal (between 0.2-0.47cm.) Visualized peristalsis appears appropriate. There were no focal lesions consistent with obstruction or a mass effect observed.

The ileocecal junction was visualized and exhibited normal intact wall layering and is subjectively of normal thickness. Sections of colon are visualized with formed fecal material and gas shadowing distally. There is no observed focal or generalized colon wall thickening or loss of layering.

### ***Pancreas***

The pancreas is normal and isoechoic to surrounding mesentery. There is no evidence of nodules or cystic lesions. There is no evidence of regional mesenteric inflammation or fluid.

### ***Free Abdomen***

Evaluation of the peritoneal cavity did not reveal any evidence of effusion, or subjective lymphadenomegaly. The Medial iliac nodes appear normal and there was no evidence of a caudal aortic thrombus at the bifurcation. The omentum is of normal uniform echogenicity.

### ***Other***

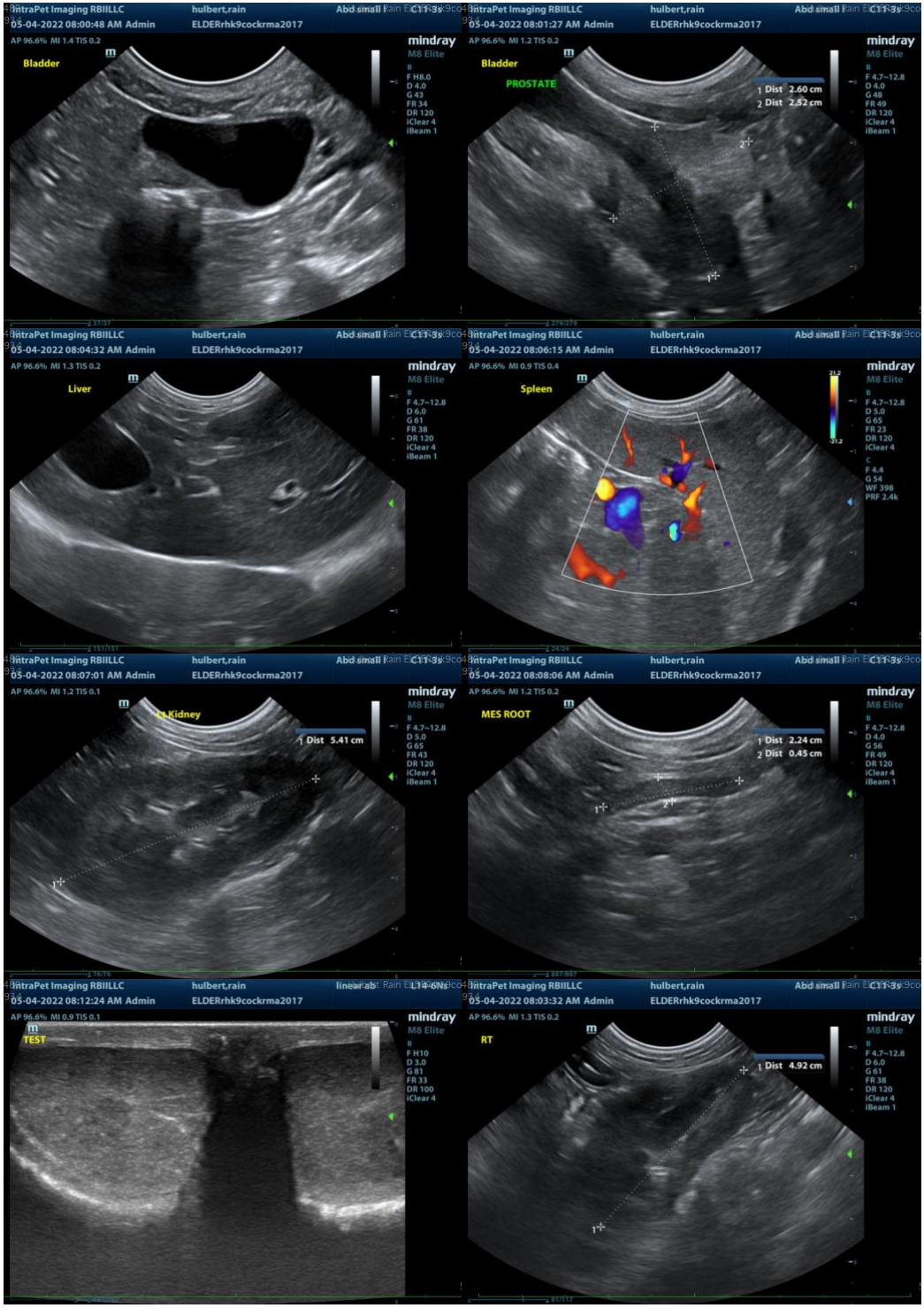
Both testicles were imaged and appear to be within normal limits.

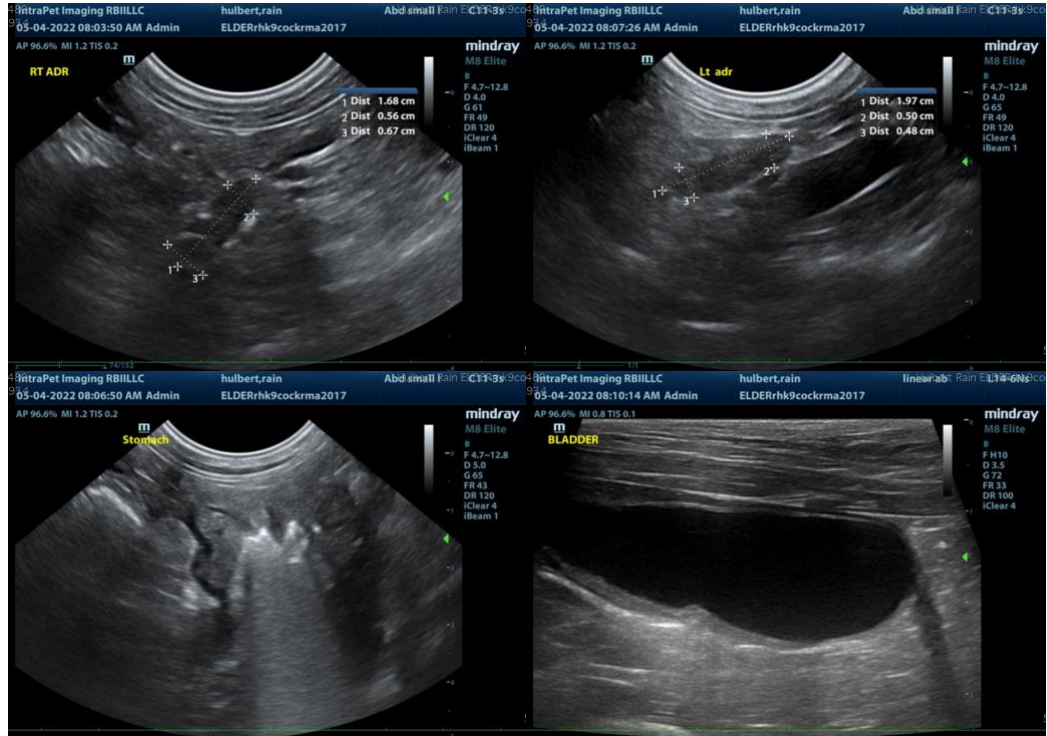
## **ULTRASONOGRAPHIC FINDINGS**

- Large, hyperechoic prostate – Prostatic changes are most consistent with benign prostatic hyperplasia. Other differentials include bacterial prostatitis and prostatic neoplasia. However, given the lack of lower urinary tract symptoms, these differentials are considered less likely in this patient.

## **INTERPRETATION OF THE FINDINGS & FURTHER RECOMMENDATIONS**

The prostate is large and hyperechoic. No focal lesions were visualized within the parenchyma. These findings are most consistent with benign prostatic hypertrophy +/- prostatitis. Recommend urinalysis and culture. The urinary bladder was not fully distended with urine, which makes evaluation of the wall less definitive. No focal mass lesions or irregularities were noted. Neutering is recommended to relieve the prostatic hypertrophy and prevent further pathology from developing.





The information and recommendations provided are based on the images presented by the referring veterinarian/sonographer. No evaluation can be communicated regarding pathology that was not visible in the image/video clips provided.

Thank you for this referral. If the clinical or image interpretation does not parallel your findings or if I can be of any further assistance please contact me.

Kathleen Sennello DVM,MS, Diplomate ACVIM (Small animal Internal Medicine)  
kathleen.sennello@sonopath.com