

IMAGING PERFORMED BY

IntraPet.com



**SonoPath**

Clinical Sonography & Telecytology

EDUCATIONAL TELECONSULTATION SERVICES™

1-800-838-4268 info@sonopath.com SonoPath.com

**DATE PRESENTING CLINICAL SIGNS**

5/31/22 Started vomiting on Thursday, saw RDVM, got a shot Still very weak, lethargic, not eating, vomiting.

**PATIENT** Current Medications: Cerenia, Protonix, Ampicillin, Buprenorphine, Vitamin B.

Riley Hunter Lab Results: See attached.  
Date of Previous IntraPet Ultrasound: No previous.  
Sedation: Not required to complete full diagnostic ultrasound.  
Stat Report: Not requested.

**SPECIES**

Canine

**ULTRASONOGRAPHIC EXAMINATION OF THE ABDOMEN**

**BREED** *Urinary System*

Miniature Poodle

The urinary bladder is moderately distended with anechoic urine. The Bladder wall, trigone, ureteral papillae and visible urethra (to a depth of 2cm) appear normal with no evidence of wall thickening, mucosal irregularities, masses or cystic calculi.

**SEX**

Neutered Male

The prostate is normal in size and shape for this neutered male dog. The parenchyma is homogenous and the external margins are smooth. The prostatic urethra appears normal with no evidence of irregularity, invasion, mass effect or calculi.

**AGE**

12/1/10

The left kidney has a normal shape and size (4.84 cm) with pyelectasia at 0.22 cm. Overall echogenicity is slightly hyperechoic with poor corticomedullary distinction and a typical 1:3 cortex:medulla ratio. There is evidence of surrounding perinephric inflammation and a small amount of effusion. There is no evidence of nephroliths, infarcts or hydroureter. Renal vasculature is normal.

**WEIGHT**

12.8 Pounds

The right kidney has a normal shape and size (5.07 cm) with mild pyelectasia at 0.24 cm. Overall echogenicity is slightly hyperechoic with poor corticomedullary distinction and a typical 1:3 cortex:medulla ratio. There is evidence of surrounding perinephric inflammation and a small amount of effusion. There is no evidence of nephroliths, infarcts or hydroureter. Renal vasculature is normal.

**INTERPRETED BY**

Kathleen Sennello DVM,  
MS, Diplomate ACVIM  
(Small Animal Internal  
Medicine)

**Adrenal Glands**

The left adrenal gland is normal in size measuring 0.51 cm at the caudal pole. It is observed in its normal position cranial to the left renal artery. It is normal in appearance (uniformly hypoechoic) and shape with no evidence of a mass effect.

**IMAGING PERFORMED BY**

Rachel Brillhart RDMS

The right adrenal gland is normal in size measuring 0.47 cm at the caudal pole. It is observed in its normal position between the cranial aspect of the right kidney and the caudal vena cava. It is normal in appearance (uniformly hypoechoic) and shape with no evidence of a mass effect.

**HOSPITAL NAME**

Animal Emergency  
Hospital

**Spleen**

The spleen is subjectively normal in size, echotexture is homogenous, and the splenic capsule is smooth with no irregularities. The blood flow through the hilus and splenic parenchyma appears normal. No focal parenchymal abnormalities are visualized.

**REFERRING VET**

Dr. King

**Liver**

The liver is subjectively normal in size, and echogenicity with smooth peripheral margins. The parenchyma is mildly heterogenous in echotexture with subtle, indistinct focal mottling. The visible portions of the vasculature and biliary tract appear normal. No focal nodules or cystic lesions are observed.

**INVOICE**

38104

The gall bladder lumen is moderately distended. The wall of the gall bladder is not thickened and has a smooth mucosal surface. There is a moderate amount of non-organized echogenic debris. The cystic and common bile ducts are normal/not visible.

### ***Gastrointestinal***

The stomach contains minimal luminal contents. It measures at a normal thickness of <0.7cm with some variability due to the presence of rugal folds. The distinction of the gastric wall layers is adequate and there is no impression of reduced peristaltic activity. No masses or focal lesions were observed.

The visualized areas of duodenum, jejunum and ileum have a relatively uniform diameter with minimal fluid distension. Wall thickness is normal. Bowel loops follow a curvilinear path with distinct wall layering maintaining the typical 1:3 muscularis:mucosa layer ratio. The duodenum measured as normal (between 0.3-0.5cm in wall thickness) and the jejunum measured as normal (between 0.2-0.47cm.) Visualized peristalsis appears appropriate. There were no focal lesions consistent with obstruction or a mass effect observed.

The ileocecal junction was visualized and appeared somewhat prominent with a thickened wall. I suspect this is due to proximity of the inflamed pancreas. The distal colon appears relatively normal.

### ***Pancreas***

The pancreas is large and hypoechoic to surrounding mesentery. There is no evidence of nodules or cystic lesions. There is evidence of regional mesenteric inflammation. Consistent with severe pancreatitis.

### ***Free Abdomen***

There is a small volume of free abdominal fluid. No lymphadenopathy is noted. There is severely hyperechoic omentum in the region of the pancreas and throughout the abdomen.

## **ULTRASONOGRAPHIC FINDINGS**

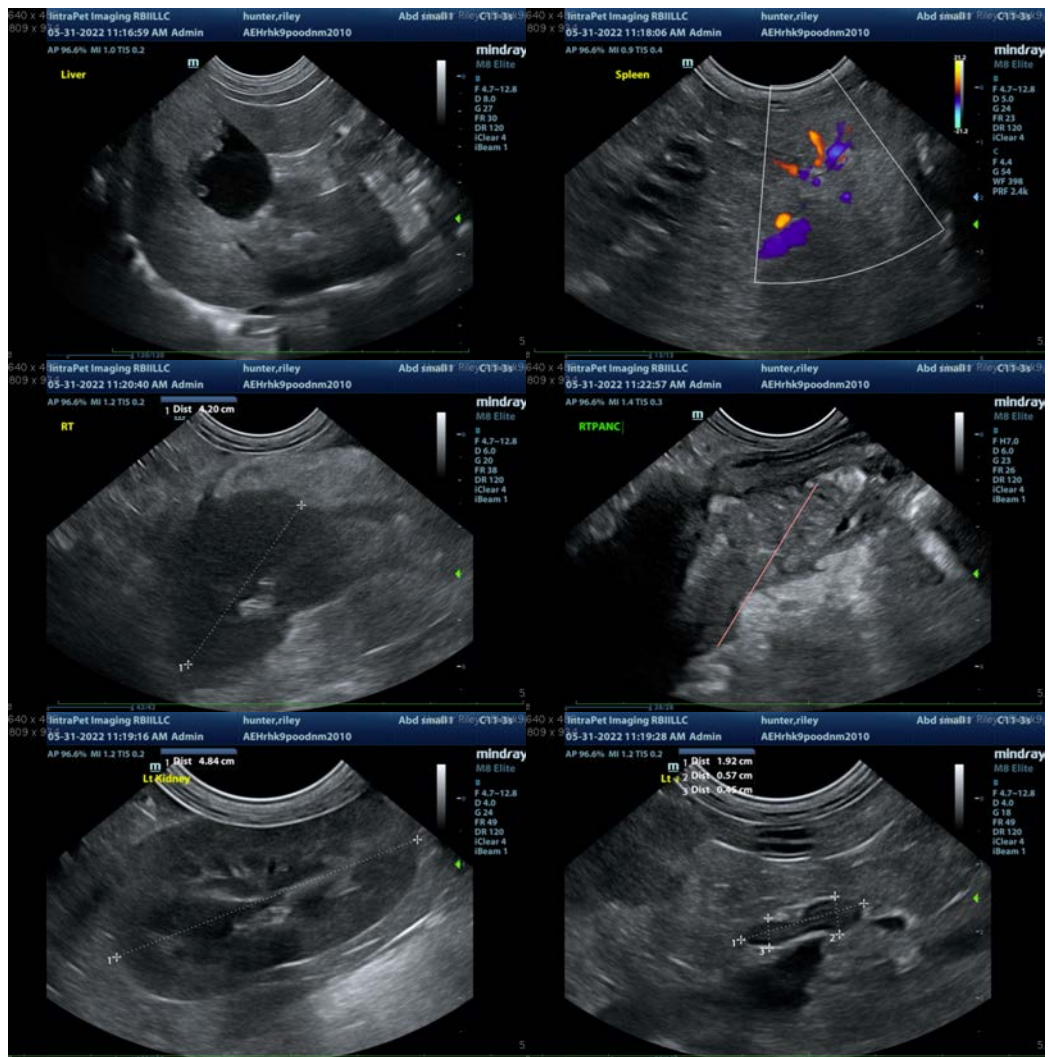
- Large, hypoechoic pancreas surrounded by severely hyperechoic mesentery and free fluid – The pancreatic changes are most consistent with severe pancreatitis/pancreatic inflammation. Recommend fPLI testing and continued monitoring for improvement or possible development of a pancreatic abscess. Consider fine needle aspirate if not improving.
- Decreased corticomedullary distinction in both kidneys with mild pyelectasia – Mild loss of corticomedullary distinction in both kidneys could be consistent with chronic degenerative disease or interstitial nephrosis. Pyelectasia of the left/right kidney could be consistent with pyelonephritis, chronic renal disease, secondary to PU/PD or fluid therapy (if applicable), other.
- Heterogeneous liver – The diffuse hepatic changes are non-specific and could be consistent with vacuolar hepatopathy, nodular hyperplasia, inflammatory/immune-mediated disease, fibrosis, extramedullary hematopoiesis, toxic hepatopathy (e.g., copper), infiltrative neoplasia (less likely) or other hepatopathy.
- Moderate gallbladder debris – The significance of the aggregated gallbladder sludge is unclear. This could represent an early mucocele, cholestasis, or may be secondary to fasting.
- Thickened ileocecal junction with surrounding hypoechoic mesentery – I suspect these changes are due to the surrounding inflamed pancreatic tissue. A primary lesion in this area cannot be excluded as a possibility. Recommend reevaluation when the pancreatic inflammation has improved.
- Small volume free abdominal fluid and severely inflamed mesentery – most consistent with sterile peritonitis secondary to the pancreatitis.

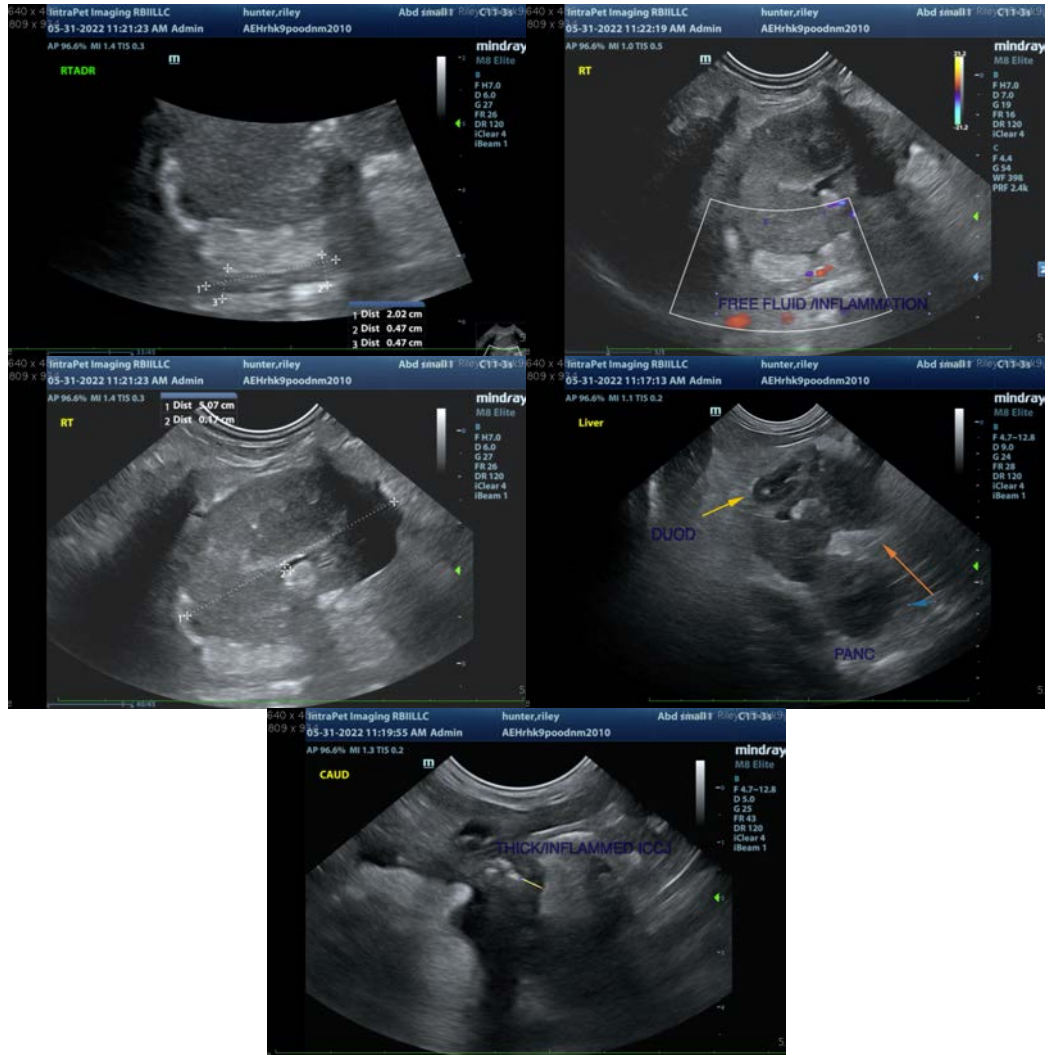## INTERPRETATION OF THE FINDINGS & FURTHER RECOMMENDATIONS

The pancreas is large and severely hypoechoic and irregular. It is surrounded by free fluid and hyperechoic mesentery, and many of the surrounding tissues appear to be secondarily inflamed (kidneys, small intestine, colon, etc.).

- Recommend intensive medical care for severe pancreatitis.
- Recommend close continued monitoring for the development of a pancreatic abscess.
- If the response to treatment is not optimal, then consider a fine needle aspirate of the pancreas.

There is reduced corticomedullary distinction in both kidneys, and mild pyelectasia. Consider a urinalysis and culture and blood pressure evaluation.





The information and recommendations provided are based on the images presented by the referring veterinarian/sonographer. No evaluation can be communicated regarding pathology that was not visible in the image/video clips provided.

Thank you for this referral. If the clinical or image interpretation does not parallel your findings or if I can be of any further assistance please contact me.

Kathleen Sennello DVM,MS, Diplomate ACVIM (Small animal Internal Medicine)  
 kathleen.sennello@sonopath.com