

**PATIENT**

Ozzie Spinozzi

SPECIES

Canine

BREED

American Eskimo Mix

SEX

Neutered male

AGE

13 years

WEIGHT

21 lbs

INTERPRETED BYKathleen Sennello
DVM, MS, Diplomate
ACVIM (Small Animal
Internal Medicine)**IMAGING PERFORMED BY**

Amy Mayhew LVT

HOSPITAL NAME

SVS Imaging Michigan

REFERRING VET

Union Lake VH

INVOICE**DATE**

5/31/22

PRESENTING CLINICAL SIGNS

History: no clinical signs, presented to have dental done history of pancreatitis but stable NSF on exam but elevated ALP and GGT **Please see attached BW

ULTRASONOGRAPHIC EXAMINATION OF THE ABDOMEN**Urinary System**

The urinary bladder is moderately distended with anechoic urine. The Bladder wall, trigone, ureteral papillae and visible urethra (to a depth of 2cm) appear normal with no evidence of wall thickening, mucosal irregularities, masses or cystic calculi.

The prostate is normal in size (1.06 cm) and shape for this neutered male dog. The parenchyma is homogenous and the external margins are smooth. The prostatic urethra appears normal with no evidence of irregularity, invasion, mass effect or calculi.

The left kidney has a normal shape and size (5.23 cm). Overall echogenicity is normal with adequate corticomedullary distinction and a typical 1:3 cortex:medulla ratio. There is no evidence of perinephric inflammation or effusion. Rare, non-obstructive nephroliths were noted. There is no evidence of pyelectasia, infarcts or hydroureter. Renal vasculature is normal.

The right kidney has a normal shape and size (5.09 cm). Overall echogenicity is normal with adequate corticomedullary distinction and a typical 1:3 cortex:medulla ratio. There is no evidence of perinephric inflammation or effusion. Rare, non-obstructive nephroliths were noted. There is no evidence of pyelectasia, infarcts or hydroureter. Renal vasculature is normal.

Adrenal Glands

The left adrenal gland is normal in size measuring 0.63 cm at the cranial pole, 0.57 cm at the caudal pole and 1.75 cm in length. It is observed in its normal position cranial to the left renal artery. It is somewhat irregular in appearance as there is a hyperechoic area on the cranial pole measuring 0.66 x 0.55 cm. This lesion does not appear to disrupt the shape of the adrenal gland and there are no vascular abnormalities.

The right adrenal gland is normal in size measuring 0.5 cm. It is observed in its normal position between the cranial aspect of the right kidney and the caudal vena cava. It is normal in appearance (uniformly hypoechoic) and shape with no evidence of a mass effect.

Spleen

The spleen is subjectively normal in size, echotexture is homogenous, and the splenic capsule is smooth with no irregularities. The blood flow through the hilus and splenic parenchyma appears normal. No focal parenchymal abnormalities are visualized.

Liver

The liver is subjectively normal in size, and echogenicity with smooth peripheral margins. The parenchyma is heterogenous in echotexture with subtle, indistinct focal mottling. The visible portions of the vasculature and biliary tract appear normal. No focal nodules or cystic lesions are observed. There

**PATIENT**

Ozzie Spinuzzi

SPECIES

Canine

BREED

American Eskimo Mix

SEX

Neutered male

AGE

13 years

WEIGHT

21 lbs

INTERPRETED BYKathleen Sennello
DVM, MS, Diplomate
ACVIM (Small Animal
Internal Medicine)**IMAGING
PERFORMED BY**

Amy Mayhew LVT

HOSPITAL NAME

SVS Imaging Michigan

REFERRING VET

Union Lake VH

INVOICE**DATE**

5/31/22

are several, ill-defined, hyperechoic nodules visualized. Two examples measure 1.26 cm and 1.84 cm in diameter. The gallbladder lumen is significantly distended. Some areas of the wall appear mildly thickened with adhered debris. Some areas have early mucosal stranding and organization of the debris into an early mucocele. There is a large amount of primarily, non-organized echogenic debris as well. There is no evidence of bile duct dilation. The cystic and common bile ducts are normal/not visible.

Gastrointestinal

The stomach contains minimal luminal contents. It measures at a normal thickness of <0.7cm with some variability due to the presence of rugal folds. The distinction of the gastric wall layers is adequate and there is no impression of reduced peristaltic activity. No masses or focal lesions were observed.

The visualized areas of duodenum, jejunum and ileum have a relatively uniform diameter with minimal fluid distension. Wall thickness is normal. Bowel loops follow a curvilinear path with distinct wall layering maintaining the typical 1:3 muscularis:mucosa layer ratio. The duodenum measured as normal (between 0.3-0.5cm in wall thickness) and the jejunum measured as normal (between 0.2-0.47cm.) Visualized peristalsis appears appropriate. There were no focal lesions consistent with obstruction or a mass effect observed.

The ileocecal junction was visualized and exhibited normal intact wall layering and is subjectively of normal thickness. Sections of colon are visualized with formed fecal material and gas shadowing distally. There is no observed focal or generalized colon wall thickening or loss of layering.

Pancreas

The pancreas is normal and isoechoic to surrounding mesentery. There is no evidence of nodules or cystic lesions. There is no evidence of regional mesenteric inflammation or fluid.

Free Abdomen

Evaluation of the peritoneal cavity did not reveal any evidence of effusion, or subjective lymphadenomegaly. The Medial iliac nodes appear normal and there was no evidence of a caudal aortic thrombus at the bifurcation. The omentum is of normal uniform echogenicity.

ULTRASONOGRAPHIC FINDINGS**PRIMARY FINDINGS:**

- Hyperechoic area on the cranial pole of the left adrenal gland. The findings are most consistent with a left adrenal nodule. This may represent an incidental finding or an early neoplastic lesion.
- Large, heterogenous liver with occasional hyperechoic nodules. The diffuse hepatic changes are non-specific and could be consistent with vacuolar hepatopathy, nodular hyperplasia, inflammatory/immune-mediated disease, fibrosis, extramedullary hematopoiesis, toxic hepatopathy (e.g., copper), infiltrative neoplasia (less likely) or other hepatopathy. The hyperechoic lymph nodes trend towards a benign appearance although a neoplastic process cannot be ruled out.
- Mild, organization of gallbladder contents. The findings are consistent with an early gallbladder



PATIENT

mucocele.

Ozzie Spinozzi

SPECIES

Canine

BREED

American Eskimo Mix

SEX

Neutered male

AGE

13 years

WEIGHT

21 lbs

INTERPRETED BY

Kathleen Sennello
DVM, MS, Diplomate
ACVIM (Small Animal
Internal Medicine)

IMAGING PERFORMED BY

Amy Mayhew LVT

HOSPITAL NAME

SVS Imaging Michigan

REFERRING VET

Union Lake VH

INVOICE

DATE

5/31/22

INTERPRETATION OF THE FINDINGS & FURTHER RECOMMENDATIONS

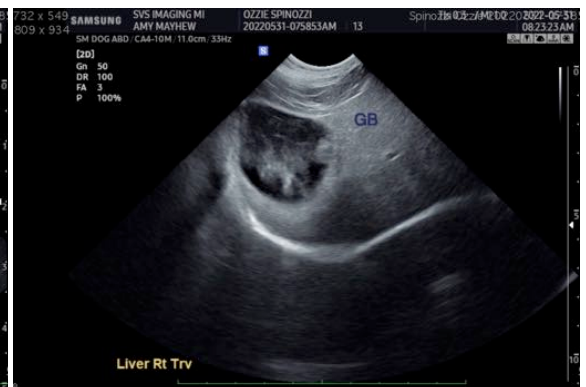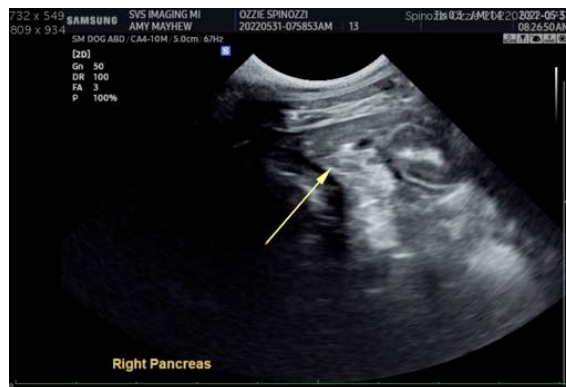The gallbladder changes are early and relatively mild, but they are consistent with early mucocele formation. Consider medical management including a course of antibiotics (possibly Clavamox if well tolerated) and Ursodiol with continued monitoring with ultrasound to look for evidence of progression of the lesion.

Additionally the liver is large and somewhat heterogenous with some ill-defined, hyperechoic nodules. This is not overly concerning but you can consider a liver function test to confirm that there is no dysfunction present and a FNA of the liver to help rule out an underlying neoplastic process (as long as coagulation parameters are normal).

Lastly there is a hyperechoic lesion on the left adrenal gland. This could be an incidental finding such as hyperplasia, etc., but unfortunately this could also represent an early neoplastic lesion or a benign hormone secreting lesion. Consider these recommendations:

- If signs of Cushing's are present, consider adrenal function testing. I prefer an ACTH stimulation test combined with an adrenal panel to the University of Tennessee's endocrine lab to look for atypical adrenal hormones as well as cortisol. (other testing can suffice)
- If adrenal dependent Cushing's is suspected and supported by adrenal function testing consider medical therapy with Lysodren or Trilostane or consider surgical removal (recommend referral to a board certified veterinary surgeon and possible pre op CT)
- Recommend blood pressure evaluation-if hypertensive consider testing catecholamine levels for a possible pheochromocytoma
- If no symptoms of Cushing's are present, consider either referral for surgery or continued monitoring with ultrasound (in 3-4 months).
- Many of these nodules can be benign and incidental in nature, unfortunately that is difficult to determine with a single ultrasound.

If there is some hormone secretion from this lesion it is possible that the ALP elevation is related to this process.



IMAGING PERFORMED BY

SVS Mobile Imaging MI 734-637-7711
svsimagingmi@gmail.com



PATIENT

Ozzie Spinozzi

SPECIES

Canine

BREED

American Eskimo Mix

SEX

Neutered male

AGE

13 years

WEIGHT

21 lbs

INTERPRETED BY

Kathleen Sennello
DVM, MS, Diplomate
ACVIM (Small Animal
Internal Medicine)

IMAGING PERFORMED BY

Amy Mayhew LVT

HOSPITAL NAME

SVS Imaging Michigan

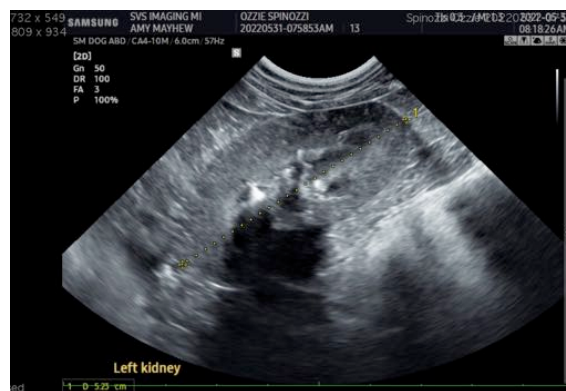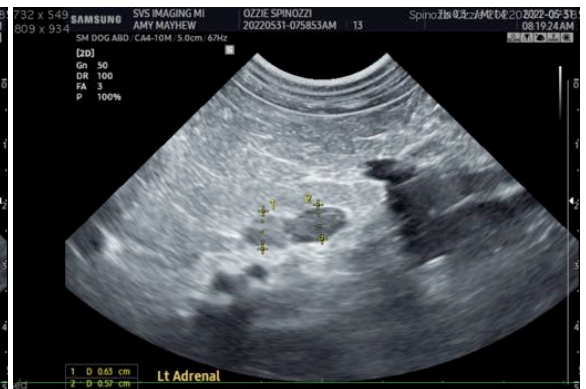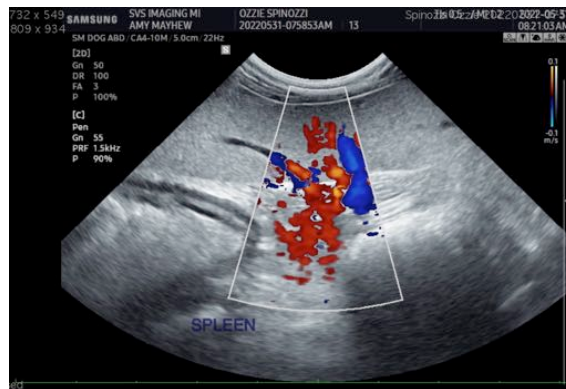
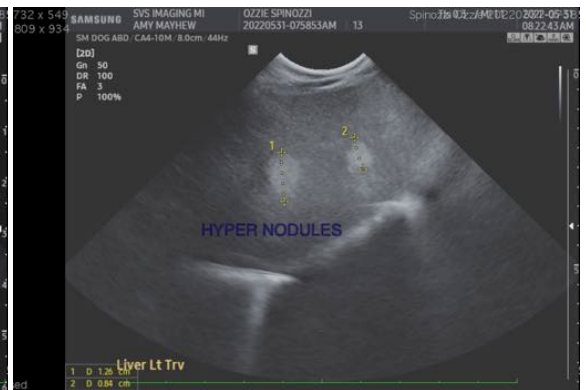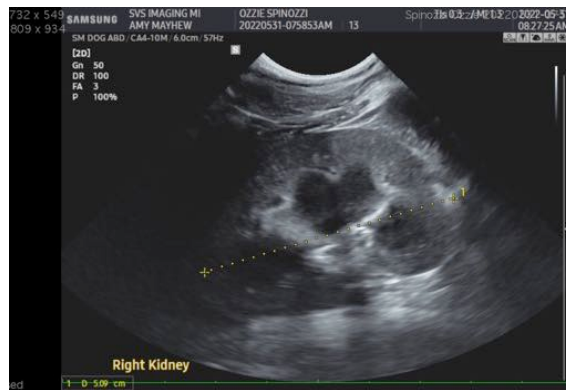
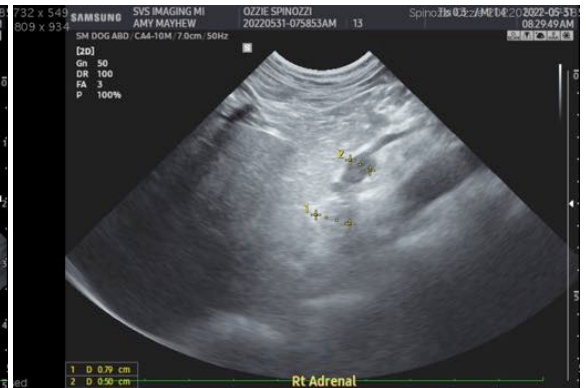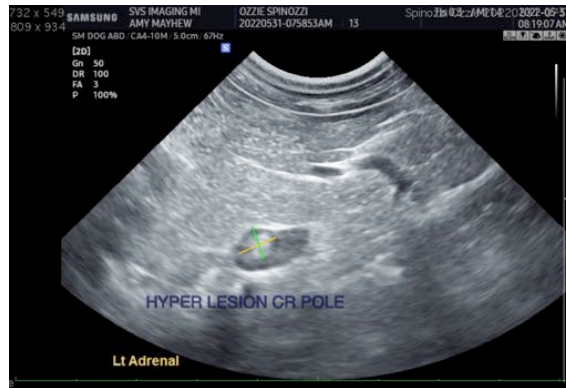REFERRING VET

Union Lake VH

INVOICE

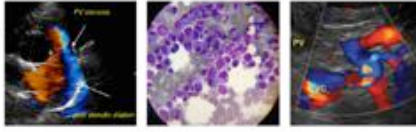
DATE

5/31/22



IMAGING PERFORMED BY

SVS Mobile Imaging MI 734-637-7711
svsimagingmi@gmail.com



PATIENT

Ozzie Spinozzi

The information and recommendations provided are based on the images presented by the referring veterinarian/sonographer. No evaluation can be communicated regarding pathology that was not visible in the image/video clips provided.

SPECIES

Canine

Thank you for this referral. If the clinical or image interpretation does not parallel your findings or if I can be of any further assistance please contact me.

BREED

American Eskimo Mix

Kathleen Sennello DVM,MS, Diplomate ACVIM (Small animal Internal Medicine)
kathleen.sennello@sonopath.com

SEX

Neutered male

AGE

13 years

WEIGHT

21 lbs

INTERPRETED BY

Kathleen Sennello
DVM, MS, Diplomate
ACVIM (Small Animal
Internal Medicine)

**IMAGING
PERFORMED BY**

Amy Mayhew LVT

HOSPITAL NAME

SVS Imaging Michigan

REFERRING VET

Union Lake VH

INVOICE

DATE

5/31/22