



**PATIENT**

Molly Francis

**PRESENTING CLINICAL SIGNS**

Bladder mass noted on in-house ultrasound. Hx of bladder stones which dissolved with diet. Current meds: Clavamox, Gabapentin

**SPECIES**

Canine

**ULTRASONOGRAPHIC EXAMINATION OF THE ABDOMEN**

**Urinary System**

**BREED**

Mix

The urinary bladder is moderately distended with anechoic urine. The Bladder wall, trigone, ureteral papillae and visible urethra (to a depth of 2cm) appear normal with no evidence of wall thickening, mucosal irregularities or cystic calculi. There is as large, rounded mass effect visible towards the apical portion of the urinary bladder measuring 4.44 cm x 3.44 cm. This lesion appears to have somewhat narrow attachment, and findings are most consistent with a bladder mass, although a benign polyp is also possible.

**SEX**

Spayed Female

The left kidney has a normal shape and size (6.42 cm). Overall echogenicity is normal with adequate corticomedullary distinction and a typical 1:3 cortex:medulla ratio. There is no evidence of perinephric inflammation or effusion. There is no evidence of pyelectasia, nephroliths, infarcts or hydroureter. Renal vasculature is normal.

**AGE**

5 Years 9 Months

The right kidney has a normal shape and size (6.13 cm). Overall echogenicity is normal with adequate corticomedullary distinction and a typical 1:3 cortex:medulla ratio. There is no evidence of perinephric inflammation or effusion. There is no evidence of pyelectasia, nephroliths, infarcts or hydroureter. Renal vasculature is normal.

**WEIGHT**

70.1 Pounds

**Adrenal Glands**

**INTERPRETED BY**

Kathleen Sennello DVM,  
MS, Diplomate ACVIM  
(Small Animal Internal  
Medicine)

The left adrenal gland is normal in size measuring 0.50 cm at the caudal pole. It is observed in its normal position cranial to the left renal artery. It is normal in appearance (uniformly hypoechoic) and shape with no evidence of a mass effect.

The right adrenal gland is normal in size measuring 0.60 cm at the caudal pole. It is observed in its normal position between the cranial aspect of the right kidney and the caudal vena cava. It is normal in appearance (uniformly hypoechoic) and shape with no evidence of a mass effect.

**IMAGING PERFORMED BY**

Shari Reffi, CVT

**Spleen**

The spleen is subjectively normal in size, echotexture is homogenous, and the splenic capsule is smooth with no irregularities. The blood flow through the hilus and splenic parenchyma appears normal. No focal parenchymal abnormalities are visualized.

**HOSPITAL NAME**

Tranquility VC

**Liver**

The liver is subjectively normal in size, and echogenicity with smooth peripheral margins. The parenchyma is homogenous echotexture. The visible portions of the vasculature and biliary tract appear normal. No focal nodules or cystic lesions are observed.

**REFERRING VET**

Dr. Blackman

The gallbladder lumen is moderately distended. The wall of the gall bladder is not thickened and has a smooth mucosal surface. Luminal contents are primarily anechoic. The cystic and common bile ducts are normal/not visible.

**INVOICE**

38110

**DATE**

5/31/22



**PATIENT**

**Gastrointestinal**

Molly Francis

The stomach contains minimal luminal contents. It measures at a normal thickness of <0.7cm with some variability due to the presence of rugal folds. The distinction of the gastric wall layers is adequate and there is no impression of reduced peristaltic activity. No masses or focal lesions were observed.

**SPECIES**

Canine

The visualized areas of duodenum, jejunum and ileum have a relatively uniform diameter with minimal fluid distension. Wall thickness is normal. Bowel loops follow a curvilinear path with distinct wall layering maintaining the typical 1:3 muscularis:mucosa layer ratio. The duodenum measured as normal (between 0.3-0.5cm in wall thickness) and the jejunum measured as normal (between 0.2-0.47cm.)

**BREED**

Mix

Visualized peristalsis appears appropriate. There were no focal lesions consistent with obstruction or a mass effect observed.

**SEX**

Spayed Female

The ileocecal junction was visualized and exhibited normal intact wall layering and is subjectively of normal thickness. Sections of colon are visualized with formed fecal material and gas shadowing distally. There is no observed focal or generalized colon wall thickening or loss of layering.

**Pancreas**

**AGE**

5 Years 9 Months

The pancreas is normal and isoechoic to surrounding mesentery. There is no evidence of nodules or cystic lesions. There is no evidence of regional mesenteric inflammation or fluid.

**Free Abdomen**

**WEIGHT**

70.1 Pounds

Evaluation of the peritoneal cavity did not reveal any evidence of effusion, or subjective lymphadenomegaly. The Medial iliac nodes appear normal and there was no evidence of a caudal aortic thrombus at the bifurcation. The omentum is of normal uniform echogenicity.

**ULTRASONOGRAPHIC FINDINGS**

- Large apical bladder mass – While concern is high for a possible transitional cell carcinoma, other mass lesions are possible (leiomyoma, polyp, etc.).

**INTERPRETATION OF THE FINDINGS & FURTHER RECOMMENDATIONS**

A large bladder mass is evident on today's scan. It is in a good position apically and is at low risk for causing an imminent obstruction. In a young dog like this, I would tend to be more aggressive in confirming that this is a true neoplasm rather than an atypical polyp or other mass, additionally considering an evaluation for possible surgical removal.

- If possible, recommend cystoscopy to biopsy this lesion and observe the attachment and to look for any other smaller sites of atypical tissue.
- With the above information, a consultation with a veterinary oncologist and surgeon could be considered to discuss options for surgery, chemotherapy, etc.
- If cystoscopy is not possible, then you could consider a traumatic catheterization for a cytologic diagnosis, or referral to a veterinary surgeon for biopsy/removal of the mass lesion and further evaluation of the urinary bladder (surgical removal is not thought to be curative for TCC, but may prolong survival times(?)).

**INVOICE**

38110

- Consider three view thoracic radiographs to rule out concurrent thoracic disease/involvement.

- Recommend urinalysis and culture (cystocentesis not recommended due to risk for tracking neoplastic cells).

**DATE**

5/31/22

**INTERPRETED BY**

Kathleen Sennello DVM,  
MS, Diplomate ACVIM  
(Small Animal Internal  
Medicine)

**IMAGING PERFORMED BY**

Shari Reffi, CVT

**HOSPITAL NAME**

Tranquility VC

**REFERRING VET**

Dr. Blackman



**PATIENT**

Molly Francis

**SPECIES**

Canine

**BREED**

Mix

**SEX**

Spayed Female

**AGE**

5 Years 9 Months

**WEIGHT**

70.1 Pounds

**INTERPRETED BY**

Kathleen Sennello DVM,  
MS, Diplomate ACVIM  
(Small Animal Internal  
Medicine)

**IMAGING  
PERFORMED BY**

Shari Reffi, CVT

**HOSPITAL NAME**

Tranquility VC

**REFERRING VET**

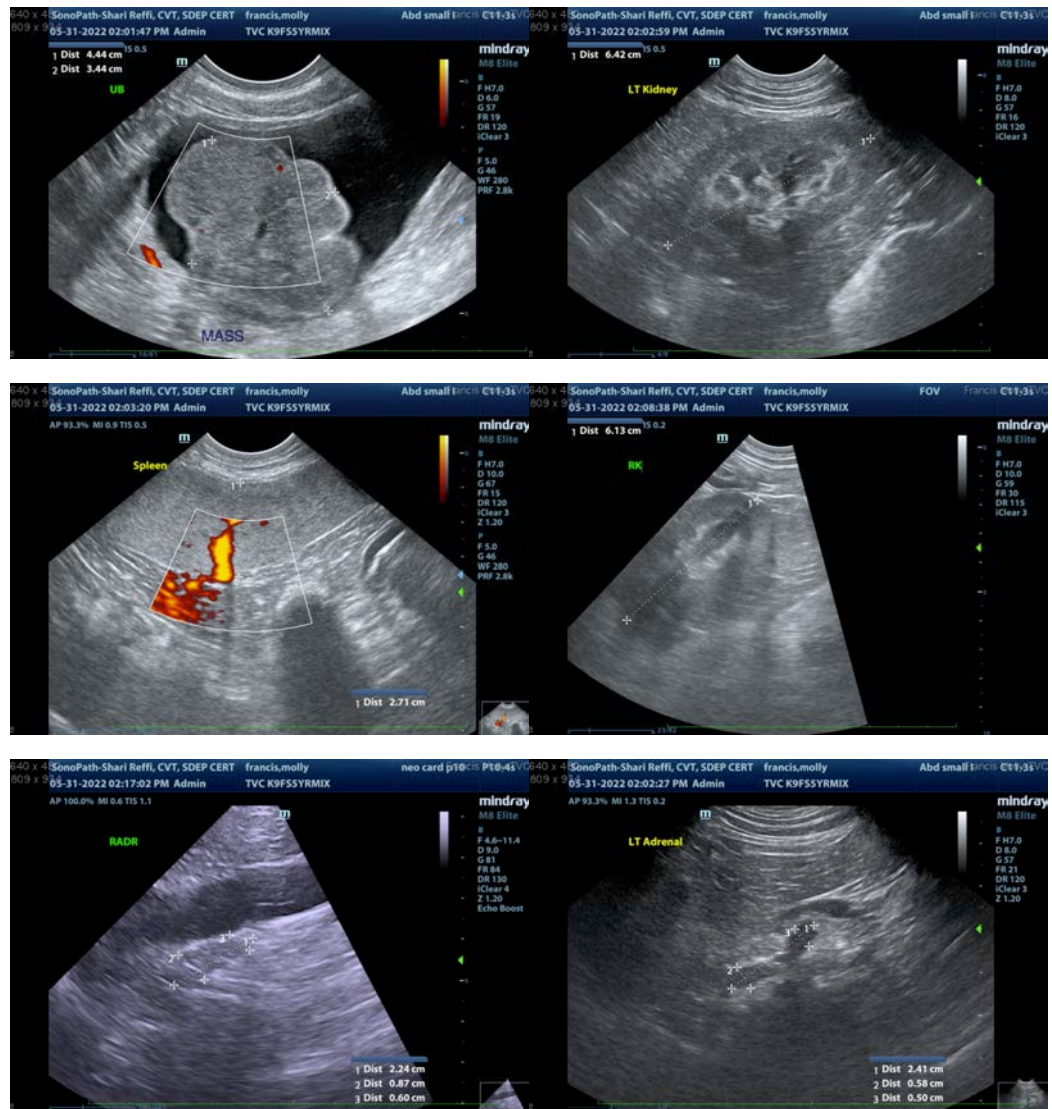
Dr. Blackman

**INVOICE**

38110

**DATE**

5/31/22



The information and recommendations provided are based on the images presented by the referring veterinarian/sonographer. No evaluation can be communicated regarding pathology that was not visible in the image/video clips provided.

Thank you for this referral. If the clinical or image interpretation does not parallel your findings or if I can be of any further assistance please contact me.

Kathleen Sennello DVM,MS, Diplomate ACVIM (Small animal Internal Medicine)

kathleen.sennello@sonopath.com