



DATE PRESENTING CLINICAL SIGNS

5/3/23 Repeatable Creat elevation with under concentrated urine. Creat between 2.4-3.0 and SDMA of 15.9.

PATIENT

Cameo Coopman
Current Medications: None listed.
Date of Previous IntraPet Ultrasound: No previous.
Sedation: Patient sedated with Torbugesic.
Stat Report: Not requested.
Imaging Performed By: Andi Parkinson, BS, RDMS.

SPECIES

Feline

ULTRASONOGRAPHIC EXAMINATION OF THE ABDOMEN

BREED

DSH

Urinary System

The urinary bladder is moderately distended with anechoic urine. The Bladder wall, trigone, ureteral papillae and visible urethra (to a depth of 2cm) appear normal with no evidence of wall thickening, mucosal irregularities, masses or cystic calculi.

SEX

Spayed Female

The left kidney is small (2.63 cm) and irregular with minimal architecture resembling a normal kidney, and some small shadowing non-obstructive nephroliths with pyelectasia at 0.54 cm. Findings are most consistent with a sclerotic kidney.

AGE

11/23/17

The right kidney is small (2.79 cm) and irregular with minimal architecture resembling a normal kidney, and some small shadowing non-obstructive nephroliths with pyelectasia at 0.54 cm. Findings are most consistent with a sclerotic kidney.

WEIGHT

12.69 Pounds

Adrenal Glands

The region of left adrenal (Cranial to left renal artery) is unremarkable but the adrenal is not distinctly visualized. No evidence of a mass effect is visualized.

INTERPRETED BY

Kathleen Sennello DVM,
MS, Diplomate ACVIM
(Small Animal Internal
Medicine)

The region of the right adrenal (between right cranial kidney and vena cava) is unremarkable, but the adrenal is not distinctly visualized. No evidence of a mass effect is visualized.

Spleen

The spleen is subjectively normal in size (0.77 cm), echotexture is homogenous, and the splenic capsule is smooth with no irregularities. The blood flow through the hilus and splenic parenchyma appears normal. No focal parenchymal abnormalities are visualized.

HOSPITAL NAME

Charm City VH

Liver

The liver is subjectively normal in size, and echogenicity with smooth peripheral margins. The parenchyma is homogenous echotexture. The visible portions of the vasculature and biliary tract appear normal. No focal nodules or cystic lesions are observed.

REFERRING VET

Dr. Hansen

INVOICE

47081

The gall bladder lumen is moderately distended. The wall of the gall bladder is not thickened and has a smooth mucosal surface. There is a moderate amount of non-organized echogenic debris. The cystic and common bile ducts are normal/not visible.

Gastrointestinal

The stomach contains minimal luminal contents. It measures at a normal thickness of <0.36cm with some variability due to the presence of rugal folds. The distinction of the gastric wall layers is adequate and there is no impression of reduced peristaltic activity. No masses or focal lesions were observed.

The visualized areas of duodenum, jejunum and ileum have a relatively uniform diameter with minimal fluid distension. Wall thickness is normal. Bowel loops follow a curvilinear path with distinct wall layering

maintaining the typical 1:3 muscularis:mucosa layer ratio. Jejunum wall measures 0.26 cm. Visualized peristalsis appears appropriate. There were no focal lesions consistent with obstruction or a mass effect observed.

The ileocecal junction was visualized and exhibited normal intact wall layering and is subjectively of normal thickness. Sections of colon are visualized with formed fecal material and gas shadowing distally. There is no observed focal or generalized colon wall thickening or loss of layering.

Pancreas

The area of the pancreas is normal and isoechoic to surrounding mesentery. There is no evidence of nodules or cystic lesions. There is no evidence of regional mesenteric inflammation or fluid.

Free Abdomen

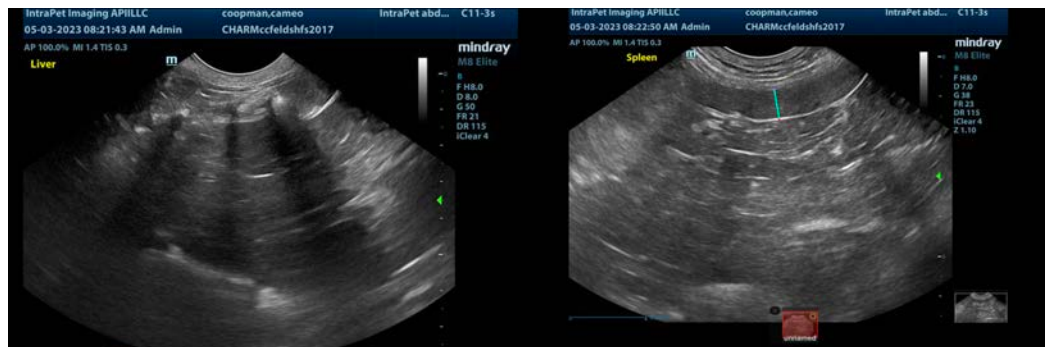
Evaluation of the peritoneal cavity did not reveal any evidence of effusion, or subjective lymphadenomegaly. The Medial iliac nodes appear normal and there was no evidence of a caudal aortic thrombus at the bifurcation. The omentum is of normal uniform echogenicity.

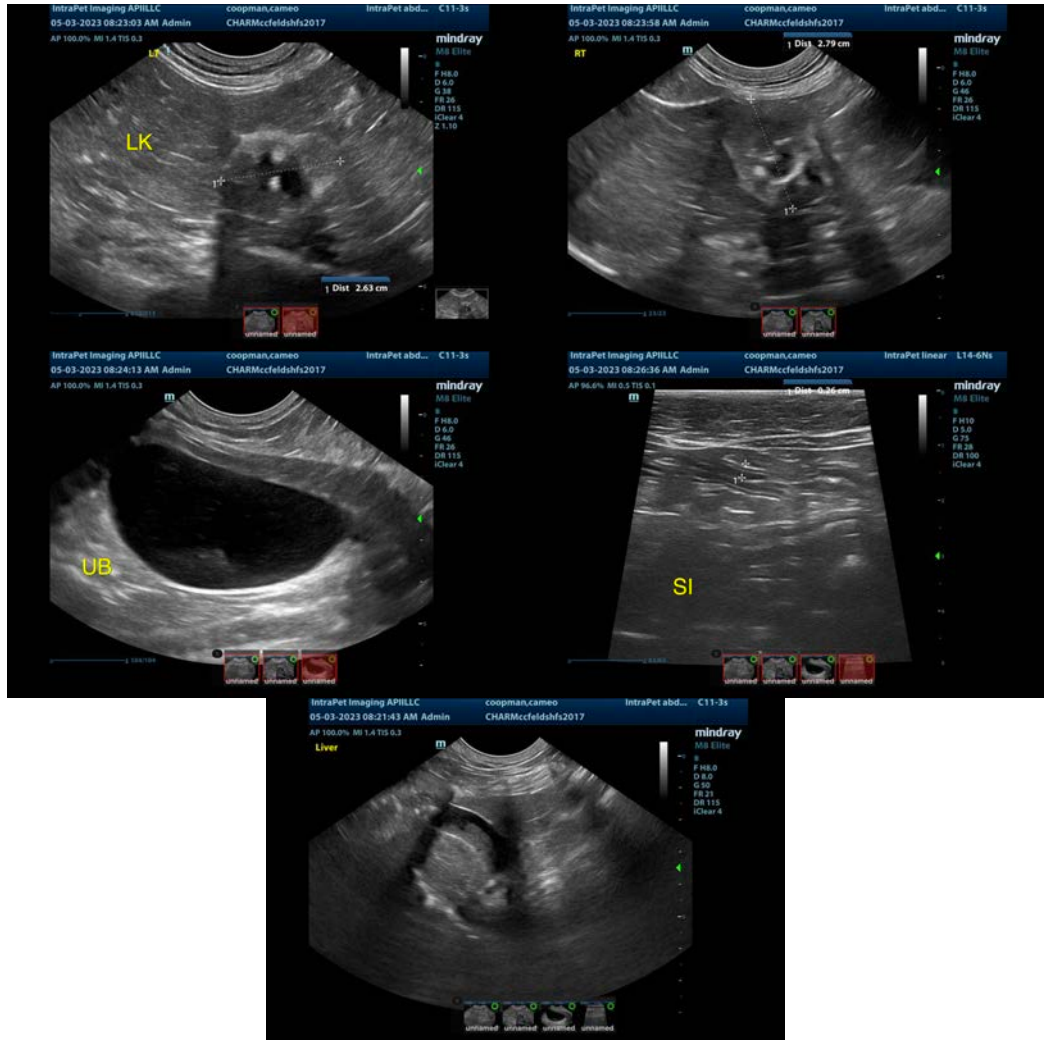ULTRASONOGRAPHIC FINDINGS

- Small, shrunken kidneys with no normal renal architecture, small non-obstructive nephroliths, and pyelectasia – Findings are most consistent with sclerotic kidneys.
- Moderate gallbladder debris – The significance of the aggregated gallbladder debris is unclear. This could represent an early mucocele, cholestasis, or may be secondary to fasting. Incidental gall bladder debris is less common in cats.

INTERPRETATION OF THE FINDINGS & FURTHER RECOMMENDATIONS

Both kidneys appear very small and irregular with minimal normal architecture. These findings could be consistent with renal dysplasia or with severe renal injury and resultant fibrosis (due to infection, toxic insult, etc.). Recommend a blood pressure evaluation, urinalysis and culture, and a renal diet with medical management to address any symptoms of uremia. Unfortunately, this is likely resultant in chronic progressive renal disease.





The information and recommendations provided are based on the images presented by the referring veterinarian/sonographer. No evaluation can be communicated regarding pathology that was not visible in the image/video clips provided.

Thank you for this referral. If the clinical or image interpretation does not parallel your findings or if I can be of any further assistance please contact me.

Kathleen Sennello DVM,MS, Diplomate ACVIM (Small animal Internal Medicine)
kathleen.sennello@sonopath.com