



PATIENT

Pepper Kim

SPECIES

Canine

BREED

Australian Cattle Dog x

SEX

Spayed Female

AGE

10 Years 4 Months

WEIGHT

47.6 lbs

INTERPRETED BY

Kathleen Sennello DVM,
 MS, Diplomate ACVIM
 (Small Animal Internal
 Medicine)

IMAGING PERFORMED BY

Kathleen Byrnes

HOSPITAL NAME

Vine Veterinary
 Hospital

REFERRING VET

Dr. Arble

INVOICE

75505

DATE

5/28/26

PRESENTING CLINICAL SIGNS

P presented for US to evaluate elevated ALKP, AND ALT, AND HYPERGLOBULINemia. P had perianal mass removed- carcinoma- clean but narrow margins. US to check for Mets and evaluate liver

ULTRASONOGRAPHIC EXAMINATION OF THE ABDOMEN

Urinary System

The urinary bladder is moderately distended with anechoic urine. The Bladder wall, trigone, ureteral papillae and visible urethra (to a depth of 2cm) appear normal with no evidence of wall thickening, mucosal irregularities, masses or cystic calculi.

The left kidney has a normal shape and size (6.01 cm). Overall echogenicity is normal with adequate corticomedullary distinction and a typical 1:3 cortex:medulla ratio. There is no evidence of focal perinephric inflammation or effusion. There is no evidence of pyelectasia, nephroliths, infarcts or hydroureter. Renal vasculature is normal.

The right kidney has a normal shape and size (6.49 cm). Overall echogenicity is normal with adequate corticomedullary distinction and a typical 1:3 cortex:medulla ratio. There is no evidence of focal perinephric inflammation or effusion. There is no evidence of pyelectasia, nephroliths, infarcts or hydroureter. Renal vasculature is normal.

Adrenal Glands

The left adrenal gland is normal in size measuring 0.48 cm at the cranial pole and 0.61 cm at the caudal pole. It is observed in its normal position cranial to the left renal artery. It is normal in appearance (uniformly hypoechoic) and shape with no evidence of a mass effect.

The right adrenal gland is normal in size measuring 0.57 cm at the cranial pole and 0.57 cm at the caudal pole. It is observed in its normal position between the cranial aspect of the right kidney and the caudal vena cava. It is normal in appearance (uniformly hypoechoic) and shape with no evidence of a mass effect.

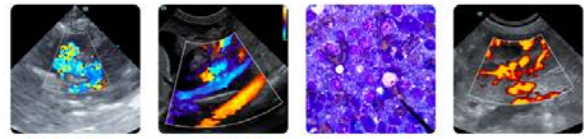
Spleen

The spleen is subjectively normal in size (1.82 cm), echotexture is homogenous, and the splenic capsule is smooth with no irregularities. The blood flow through the hilus and splenic parenchyma appears normal. No focal parenchymal abnormalities are visualized.

Liver

The liver is subjectively normal in size, and echogenicity with smooth peripheral margins. The parenchyma is homogenous echotexture. The visible portions of the vasculature and biliary tract appear normal. No focal nodules or cystic lesions are observed.

The gall bladder lumen is moderately distended. The wall of the gall bladder is not thickened and has a smooth mucosal surface. There is a moderate amount of non-organized echogenic debris. There is a focal soft shadowing hyperechoic focus in the gallbladder lumen most consistent with a cholelith or aggregate of debris measuring 2.0 cm. The cystic and common bile ducts are normal/not visible.



PATIENT

Pepper Kim

SPECIES

Canine

BREED

Australian Cattle Dog x

SEX

Spayed Female

AGE

10 Years 4 Months

WEIGHT

47.6 lbs

INTERPRETED BY

Kathleen Sennello DVM,
 MS, Diplomate ACVIM
 (Small Animal Internal
 Medicine)

IMAGING PERFORMED BY

Kathleen Byrnes

HOSPITAL NAME

Vine Veterinary
 Hospital

REFERRING VET

Dr. Arble

INVOICE

75505

DATE

5/28/26

Gastrointestinal

The stomach contains moderate fluid/ingesta. It measures at a normal thickness of <0.7cm with some variability due to the presence of rugal folds. The distinction of the gastric wall layers is adequate and there is no impression of reduced peristaltic activity. No masses or focal lesions were observed.

The visualized areas of duodenum, jejunum and ileum have a relatively uniform diameter with minimal fluid distension. Wall thickness is normal. Bowel loops follow a curvilinear path with distinct wall layering maintaining the typical 1:3 muscularis:mucosa layer ratio. Duodenum wall measures 0.40 cm. Jejunum wall measures 0.42 cm. Visualized peristalsis appears appropriate. There were no focal lesions consistent with obstruction or a mass effect observed.

Sections of colon are visualized with formed fecal material and gas shadowing distally. There is no observed focal or generalized colon wall thickening or loss of layering.

Pancreas

The pancreas is visible/hypoechoic. There is no evidence of nodules or cystic lesions. There is no evidence of regional mesenteric inflammation or fluid.

Free Abdomen

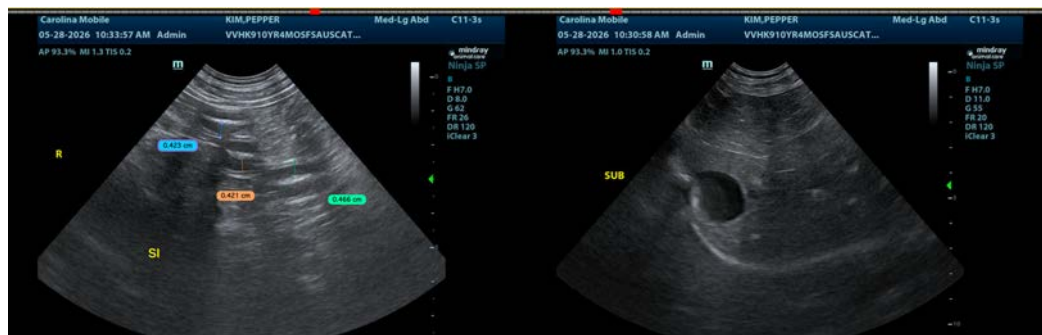
Evaluation of the peritoneal cavity did not reveal any evidence of effusion, or subjective lymphadenomegaly. The Medial iliac nodes appear normal and there was no evidence of a caudal aortic thrombus at the bifurcation. The omentum is of normal uniform echogenicity.

ULTRASONOGRAPHIC FINDINGS

- Pancreatic changes consistent with mild pancreatic remodeling.
- Hyperechoic cholelith/debris visualized in the gallbladder – This is likely incidental at this time. Recommend continued monitoring.

INTERPRETATION OF THE FINDINGS & FURTHER RECOMMENDATIONS

There is no evidence of iliac lymph node enlargement or other evidence of metastatic disease on today's exam. The liver appears relatively normal with no focal lesions observed. Depending on the severity of the liver enzyme elevations, a liver function test could be considered +/- fine needle aspirate. Ultimately, if liver enzymes are significant and persistent, biopsies of the liver may be necessary for further evaluation (histopath, culture and copper level).





PATIENT

Pepper Kim

SPECIES

Canine

BREED

Australian Cattle Dog x

SEX

Spayed Female

AGE

10 Years 4 Months

WEIGHT

47.6 lbs

INTERPRETED BY

Kathleen Sennello DVM,
 MS, Diplomate ACVIM
 (Small Animal Internal
 Medicine)

IMAGING PERFORMED BY

Kathleen Byrnes

HOSPITAL NAME

Vine Veterinary
 Hospital

REFERRING VET

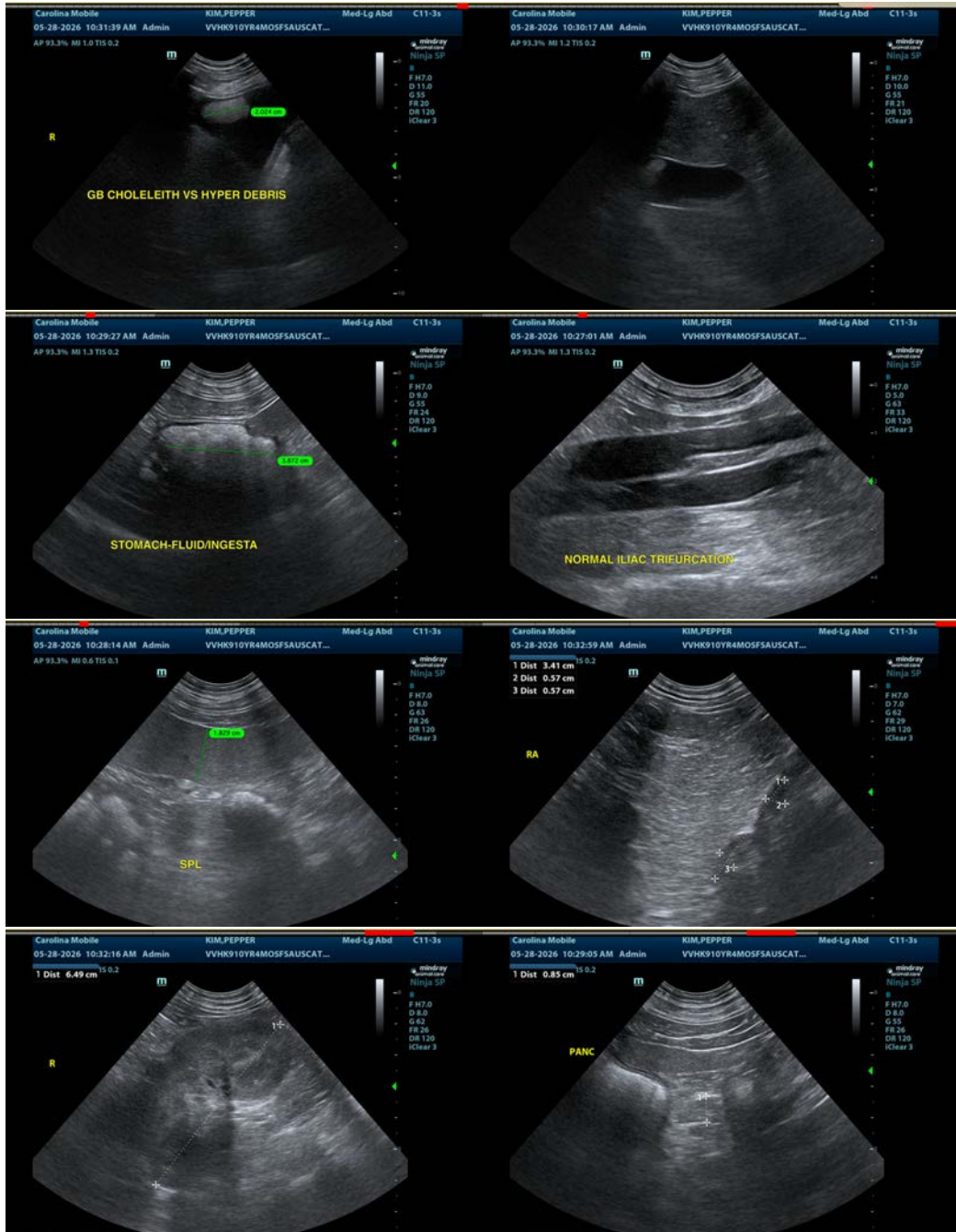
Dr. Arble

INVOICE

75505

DATE

5/28/26





PATIENT

Pepper Kim

SPECIES

Canine

BREED

Australian Cattle Dog x

SEX

Spayed Female

AGE

10 Years 4 Months

WEIGHT

47.6 lbs

INTERPRETED BY

Kathleen Sennello DVM,
MS, Diplomate ACVIM
(Small Animal Internal
Medicine)

IMAGING PERFORMED BY

Kathleen Byrnes

HOSPITAL NAME

Vine Veterinary
Hospital

REFERRING VET

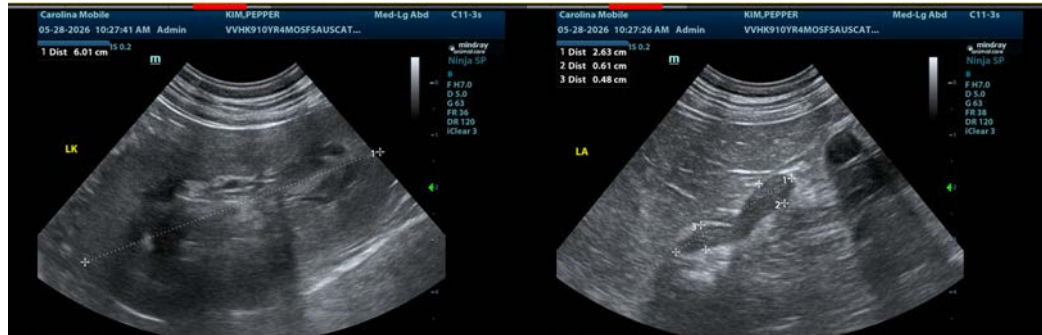
Dr. Arble

INVOICE

75505

DATE

5/28/26



The information and recommendations provided are based on the images presented by the referring veterinarian/sonographer. No evaluation can be communicated regarding pathology that was not visible in the image/video clips provided.

Thank you for this referral. If the clinical or image interpretation does not parallel your findings or if I can be of any further assistance please contact me.

Kathleen Sennello DVM,MS, Diplomate ACVIM (Small animal Internal Medicine)

info@sonopath.com