



PATIENT

Luna Mendoza

SPECIES

Canine

BREED

Boston Terrier

SEX

Spayed Female

AGE

8 Years

WEIGHT

26.2 lbs

INTERPRETED BY

Kathleen Sennello DVM,
MS, Diplomate ACVIM
(Small Animal Internal
Medicine)

IMAGING PERFORMED BY

Dr. Casper

HOSPITAL NAME

Hometown Animal
Hospital (Florida)

REFERRING VET

Dr. AJ Basta

INVOICE

75484

DATE

5/27/26

PRESENTING CLINICAL SIGNS

Recent rads show diffuse hepatopathy. ALP increased 1486, was 1018 Jan 2026 and 783 Aug 2025 cholesterol elevated. Thyroid NSF, 4dx neg. Liver FNA pending.

ULTRASONOGRAPHIC EXAMINATION OF THE ABDOMEN

Urinary System

The urinary bladder is moderately distended with anechoic urine. The Bladder wall, trigone, ureteral papillae and visible urethra (to a depth of 2cm) appear normal with no evidence of wall thickening, mucosal irregularities, masses or cystic calculi.

The left kidney has a normal shape and size (4.83 cm). Overall echogenicity is normal with adequate corticomedullary distinction and a typical 1:3 cortex:medulla ratio. There is no evidence of focal perinephric inflammation or effusion. There is no evidence of pyelectasia, nephroliths, infarcts or hydroureter. Renal vasculature is normal.

The right kidney has a normal shape and size (5.23 cm). Overall echogenicity is normal with adequate corticomedullary distinction and a typical 1:3 cortex:medulla ratio. There is no evidence of focal perinephric inflammation or effusion. There is no evidence of pyelectasia, nephroliths, infarcts or hydroureter. Renal vasculature is normal.

Adrenal Glands

The left adrenal gland is normal in size measuring 0.52 cm at the cranial pole and 0.61 cm at the caudal pole. It is observed in its normal position cranial to the left renal artery. It is normal in appearance (uniformly hypoechoic) and shape with no evidence of a mass effect.

The right adrenal gland is normal in size measuring 0.92 cm at the cranial pole and 0.65 cm at the caudal pole. It is observed in its normal position between the cranial aspect of the right kidney and the caudal vena cava. It is normal in appearance (uniformly hypoechoic) and shape with no evidence of a mass effect.

Spleen

The spleen is subjectively normal in size (1.36 cm), echotexture is homogenous, and the splenic capsule is smooth with no irregularities. The blood flow through the hilus and splenic parenchyma appears normal. No focal parenchymal abnormalities are visualized.

Liver

The liver is large with mildly rounded margins. The parenchyma is heterogenous in echotexture with subtle, indistinct focal mottling. The visible portions of the vasculature and biliary tract appear normal. No focal nodules or cystic lesions are observed.

The gall bladder lumen is moderately distended. The wall of the gall bladder is not thickened and has a smooth mucosal surface. There is a moderate amount of non-organized echogenic debris. The cystic and common bile ducts are normal/not visible.



PATIENT

Luna Mendoza

SPECIES

Canine

BREED

Boston Terrier

SEX

Spayed Female

AGE

8 Years

WEIGHT

26.2 lbs

INTERPRETED BY

Kathleen Sennello DVM,
MS, Diplomate ACVIM
(Small Animal Internal
Medicine)

IMAGING PERFORMED BY

Dr. Casper

HOSPITAL NAME

Hometown Animal
Hospital (Florida)

REFERRING VET

Dr. AJ Basta

INVOICE

75484

DATE

5/27/26

Gastrointestinal

The stomach contains minimal luminal contents. It measures at a normal thickness of <0.7cm with some variability due to the presence of rugal folds. The distinction of the gastric wall layers is adequate and there is no impression of reduced peristaltic activity. No masses or focal lesions were observed.

The visualized areas of duodenum, jejunum and ileum have a relatively uniform diameter with minimal fluid distension. Wall thickness is normal. Bowel loops follow a curvilinear path with distinct wall layering maintaining the typical 1:3 muscularis:mucosa layer ratio. Jejunum wall measures 0.32 cm. Duodenum wall measures 0.41 cm. Visualized peristalsis appears appropriate. There were no focal lesions consistent with obstruction or a mass effect observed.

Sections of colon are visualized with formed fecal material and gas shadowing distally. There is no observed focal or generalized colon wall thickening or loss of layering.

Pancreas

The area of the pancreas is normal and isoechoic to surrounding mesentery. There is no evidence of nodules or cystic lesions. There is no evidence of regional mesenteric inflammation or fluid.

Free Abdomen

Evaluation of the peritoneal cavity did not reveal any evidence of effusion, or subjective lymphadenomegaly. The Medial iliac nodes appear normal and there was no evidence of a caudal aortic thrombus at the bifurcation. The omentum is of normal uniform echogenicity.

ULTRASONOGRAPHIC FINDINGS

- Subjectively large, mildly heterogeneous liver – The diffuse hepatic changes are non-specific and could be consistent with vacuolar hepatopathy, nodular hyperplasia, inflammatory/immune-mediated disease, fibrosis, extramedullary hematopoiesis, toxic hepatopathy (e.g., copper), infiltrative neoplasia (less likely) or other hepatopathy.
- Moderate gallbladder debris – The significance of the aggregated gallbladder debris is unclear. This could represent an early mucocele, cholestasis, or may be secondary to fasting but seems unlikely to be causing a current issue. Recommend continued monitoring.

INTERPRETATION OF THE FINDINGS & FURTHER RECOMMENDATIONS

No focal lesions are visualized associated with the liver to explain the elevation in liver enzymes reported. The liver itself appears subjectively large with a generalized mildly heterogeneous pattern, possibly consistent with a vacuolar hepatopathy or other primary hepatopathy. If further evaluation is desired, you could consider pre- and post-prandial bile acids to assess liver function and a fine needle aspirate (I believe this is currently pending).

These changes could be consistent with a primary hepatopathy or a hepatopathy secondary to metabolic disease. If signs of Cushing's are present, you could consider adrenal function testing despite relatively normal appearing adrenal glands. Additionally, further treatment/evaluation for the elevation in cholesterol could be considered.

There is a moderate amount of debris visualized in the gallbladder but no evidence of wall thickening or surrounding inflammation. Options would include continued monitoring +/- chronic Ursodiol therapy.



PATIENT

Luna Mendoza

SPECIES

Canine

BREED

Boston Terrier

SEX

Spayed Female

AGE

8 Years

WEIGHT

26.2 lbs

INTERPRETED BY

Kathleen Sennello DVM,
MS, Diplomate ACVIM
(Small Animal Internal
Medicine)

**IMAGING
PERFORMED BY**

Dr. Casper

HOSPITAL NAME

Hometown Animal
Hospital (Florida)

REFERRING VET

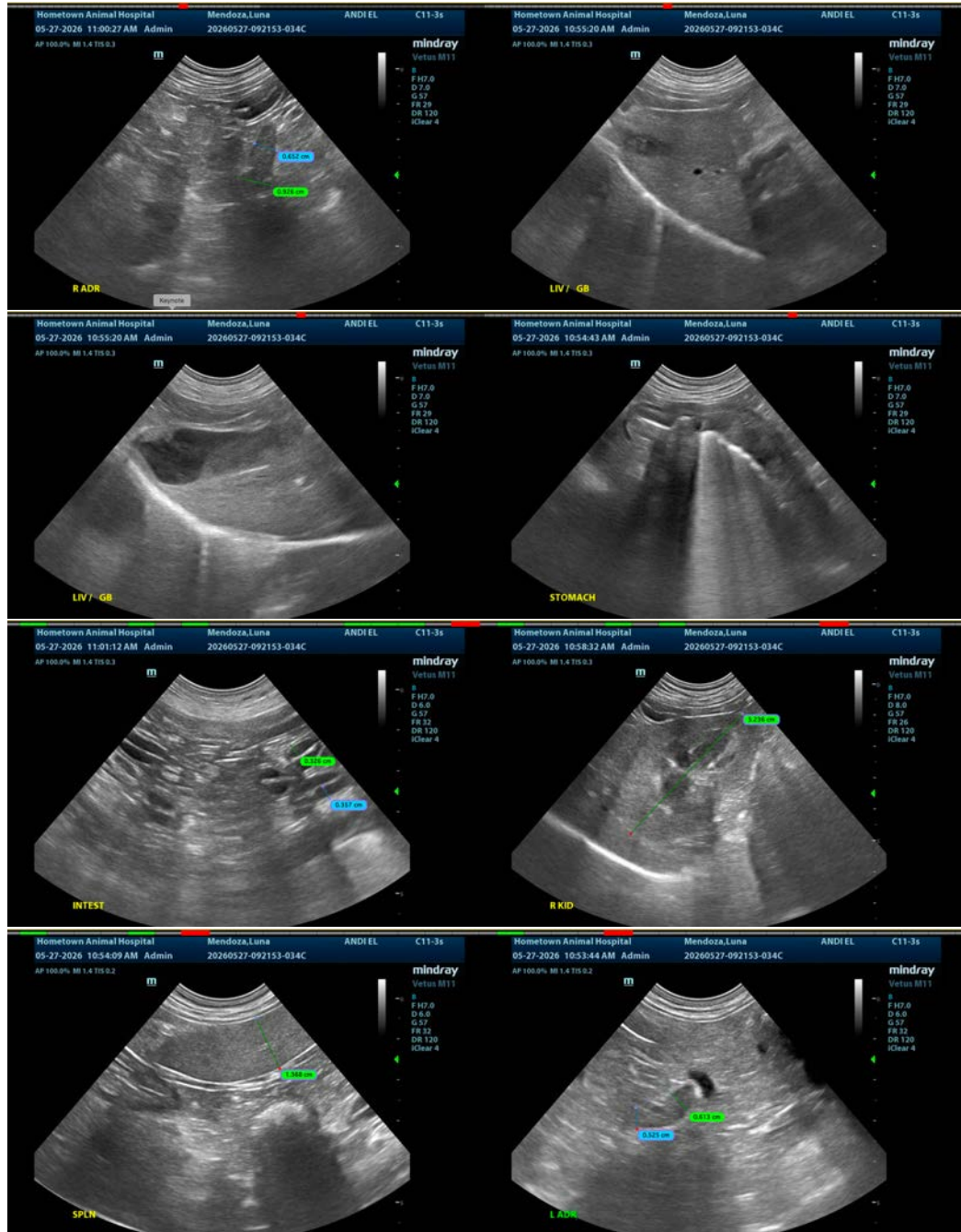
Dr. AJ Basta

INVOICE

75484

DATE

5/27/26





PATIENT

Luna Mendoza

SPECIES

Canine

BREED

Boston Terrier

SEX

Spayed Female

AGE

8 Years

WEIGHT

26.2 lbs

INTERPRETED BY

Kathleen Sennello DVM,
MS, Diplomate ACVIM
(Small Animal Internal
Medicine)

IMAGING PERFORMED BY

Dr. Casper

HOSPITAL NAME

Hometown Animal
Hospital (Florida)

REFERRING VET

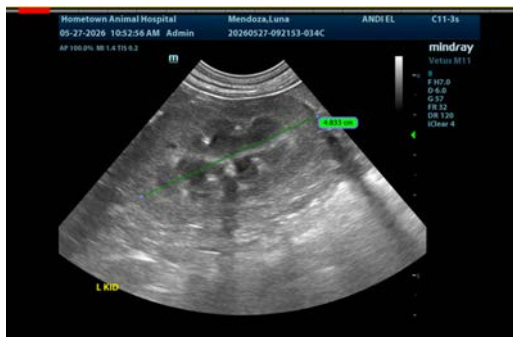Dr. AJ Basta

INVOICE

75484

DATE

5/27/26



The information and recommendations provided are based on the images presented by the referring veterinarian/sonographer. No evaluation can be communicated regarding pathology that was not visible in the image/video clips provided.

Thank you for this referral. If the clinical or image interpretation does not parallel your findings or if I can be of any further assistance please contact me.

Kathleen Sennello DVM,MS, Diplomate ACVIM (Small animal Internal Medicine)

info@sonopath.com