



PATIENT

Luigi Pietrzck

SPECIES

Feline

BREED

DMH

SEX

Neutered Male

AGE

6 Years

WEIGHT

10.9 lbs

INTERPRETED BY

Kathleen Sennello DVM,
MS, Diplomate ACVIM
(Small Animal Internal
Medicine)

IMAGING PERFORMED BY

Rebecca Hamilton

HOSPITAL NAME

Newburgh Veterinary
Hospital

REFERRING VET

Dr. Harlec

INVOICE

75468

DATE

5/27/26

PRESENTING CLINICAL SIGNS

Inappetence, vomiting, weight loss- about 1 week duration gas/fluid in intestinal tract dehydrated. Little response to Cerenia, Reglan, mirtaz at home. Hx of foreign body surgery 2023. Hospitalized 5/26- Cerenia, Famotidine, B12, IV Fluid, Buprenex, one inj. of dexamethasone.

Abnormal PE/Chem/CBC/UA Results: Lab work WNL, USG 1.065

ULTRASONOGRAPHIC EXAMINATION OF THE ABDOMEN

Urinary System

The urinary bladder is moderately distended with anechoic urine. The Bladder wall, trigone, ureteral papillae and visible urethra (to a depth of 2cm) appear normal with no evidence of wall thickening, mucosal irregularities, masses or cystic calculi.

The left kidney has a normal shape and size (3.86 cm). Overall echogenicity is normal with adequate corticomedullary distinction and a typical 1:3 cortex:medulla ratio. There is no evidence of focal perinephric inflammation or effusion. There is no evidence of pyelectasia, nephroliths, infarcts or hydroureter. Renal vasculature is normal.

The right kidney has a normal shape and size (4.01 cm). Overall echogenicity is normal with adequate corticomedullary distinction and a typical 1:3 cortex:medulla ratio. There is no evidence of focal perinephric inflammation or effusion. There is no evidence of pyelectasia, nephroliths, infarcts or hydroureter. Renal vasculature is normal.

Adrenal Glands

The left adrenal gland is normal in size measuring 0.21 cm at the caudal pole. It is observed in its normal position cranial to the left renal artery. It is normal in appearance (uniformly hypoechoic) and shape with no evidence of a mass effect.

The right adrenal gland is normal in size measuring 0.29 cm at the caudal pole. It is observed in its normal position between the cranial aspect of the right kidney and the caudal vena cava. It is normal in appearance (uniformly hypoechoic) and shape with no evidence of a mass effect.

Spleen

The spleen is subjectively normal in size (0.82 cm), echotexture is homogenous, and the splenic capsule is smooth with no irregularities. The blood flow through the hilus and splenic parenchyma appears normal. No focal parenchymal abnormalities are visualized.

Liver

The liver is subjectively normal in size, and echogenicity with smooth peripheral margins. The parenchyma is homogenous echotexture. The visible portions of the vasculature and biliary tract appear normal. No focal nodules or cystic lesions are observed.

The gall bladder lumen is minimally distended. The wall of the gall bladder is not thickened and has a smooth mucosal surface. Luminal contents are mild and likely incidental at this time. Visualization and evaluation of the gallbladder is difficult due to lack of distention. The bile duct is not clearly visualized.



PATIENT

Luigi Pietrzck

SPECIES

Feline

BREED

DMH

SEX

Neutered Male

AGE

6 Years

WEIGHT

10.9 lbs

INTERPRETED BY

Kathleen Sennello DVM,
MS, Diplomate ACVIM
(Small Animal Internal
Medicine)

IMAGING PERFORMED BY

Rebecca Hamilton

HOSPITAL NAME

Newburgh Veterinary
Hospital

REFERRING VET

Dr. Harlec

INVOICE

75468

DATE

5/27/26

Gastrointestinal

The stomach contains moderate fluid, gas, and shadowing ingesta. It measures at a normal thickness of 0.17 cm with some variability due to the presence of rugal folds. The distinction of the gastric wall layers is adequate and there is no impression of reduced peristaltic activity. No masses or focal lesions were observed. Additionally, the proximal duodenum/pylorus is mildly distended with fluid and soft shadowing material (likely ingesta).

The majority of the visualized areas of duodenum, jejunum and ileum have a relatively uniform diameter with mild to moderate fluid/ingesta distension. Wall thickness is normal. Duodenum wall measures 0.19 cm. Jejunum wall measures 0.19 cm. Some areas have poorly defined shadowing intraluminal shadowing ingesta and fluid without evidence of a focal obstruction (likely ingesta), and there is an extensive section of bowel that appears severely corrugated, without a significant obstructive pattern. Correlate with feeding history. Findings are most consistent with severe enteritis/ileus-a small focal partial obstruction(s) are possible but less likely.

Sections of colon are visualized with formed fecal material and gas shadowing distally. There is no observed focal or generalized colon wall thickening or loss of layering.

Pancreas

The left limb of the pancreas is prominent and hypoechoic as compared to the surrounding isoechoic mesentery. There is no evidence of nodules or cystic lesions.

Free Abdomen

Evaluation of the peritoneal cavity did not reveal any evidence of effusion. There is no significant lymphadenopathy. A prominent lymph node is visualized in the cranial abdomen measuring 0.56 cm x 0.66 cm. The omentum is mildly diffusely hyperechoic.

ULTRASONOGRAPHIC FINDINGS

- Fluid, gas, and ingesta distended stomach – Correlate with feeding history. If the patient was adequately fasted, this could represent ingested foreign material, hair, etc. The pyloric region/proximal duodenum is distended with fluid, gas and soft shadowing material. Findings are suggestive of gastric ileus. A definitive obstruction is not visualized.
- Fluid and gas distended small intestine with some areas of shadowing intraluminal material and severe corrugation – Findings are most consistent with a severe enteritis type pattern, but given some focal areas of shadowing and corrugation, partially obstructive lesions cannot be ruled out but are less likely.
- Prominent, hypoechoic left limb of the pancreas – Findings could be consistent with mild pancreatitis -correlate with fPLI

INTERPRETATION OF THE FINDINGS & FURTHER RECOMMENDATIONS

The stomach is significantly distended with fluid, gas, and soft shadowing material (most consistent with ingesta). Correlate with the most recent feeding time to determine if this is a post-prandial patient versus significant gastric ileus or ingested foreign material, hair ball, etc. Some of this material appears



PATIENT

Luigi Pietrzck

SPECIES

Feline

BREED

DMH

SEX

Neutered Male

AGE

6 Years

WEIGHT

10.9 lbs

INTERPRETED BY

Kathleen Sennello DVM,
 MS, Diplomate ACVIM
 (Small Animal Internal
 Medicine)

**IMAGING
 PERFORMED BY**

Rebecca Hamilton

HOSPITAL NAME

Newburgh Veterinary
 Hospital

REFERRING VET

Dr. Harlec

INVOICE

75468

DATE

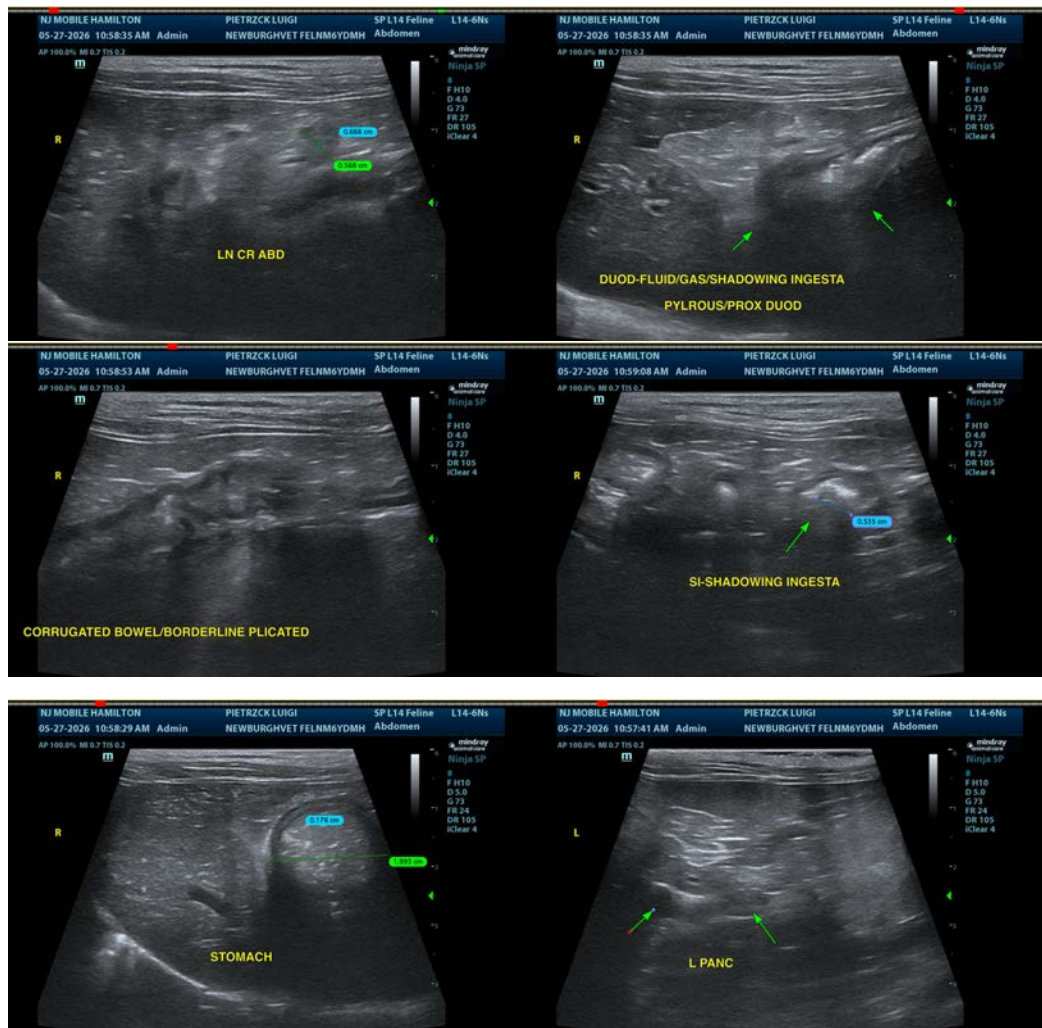
5/27/26

to extend into the pylorus/proximal duodenum, although a definitive obstruction is not visualized.

The small intestine is characterized by loops of fluid and gas distended bowel with some focal areas of what appears to be non-obstructive foreign material/ingesta. Additionally, there is a significant segment of bowel that appears severely corrugated/almost plicated-most consistent with focal severe enteritis.

If the patient has been fasted for a significant amount of time, these findings are concerning. Recommend in-hospital hydration, supportive care and NPO, with reevaluation in 12-24 hours (radiographs +/- ultrasound) to determine if material is passing. If there is no significant improvement consider surgical explore with the intent to further evaluate, biopsy and evaluate for ingested foreign material. Evaluation of the previous surgical area is recommended. (stricture etc..)

Consider further evaluation for causes of enteritis (viral, parasitic, inflammatory, allergic). If a chronic condition is suspected consider a hydrolyzed protein diet, a GI panel to Texas A&M (fPLI, TLI, cobalamine, folate) to evaluate for chronic pancreatitis and a chronic enteropathy.





PATIENT

Luigi Pietrzck

SPECIES

Feline

BREED

DMH

SEX

Neutered Male

AGE

6 Years

WEIGHT

10.9 lbs

INTERPRETED BY

Kathleen Sennello DVM,
 MS, Diplomate ACVIM
 (Small Animal Internal
 Medicine)

**IMAGING
 PERFORMED BY**

Rebecca Hamilton

HOSPITAL NAME

Newburgh Veterinary
 Hospital

REFERRING VET

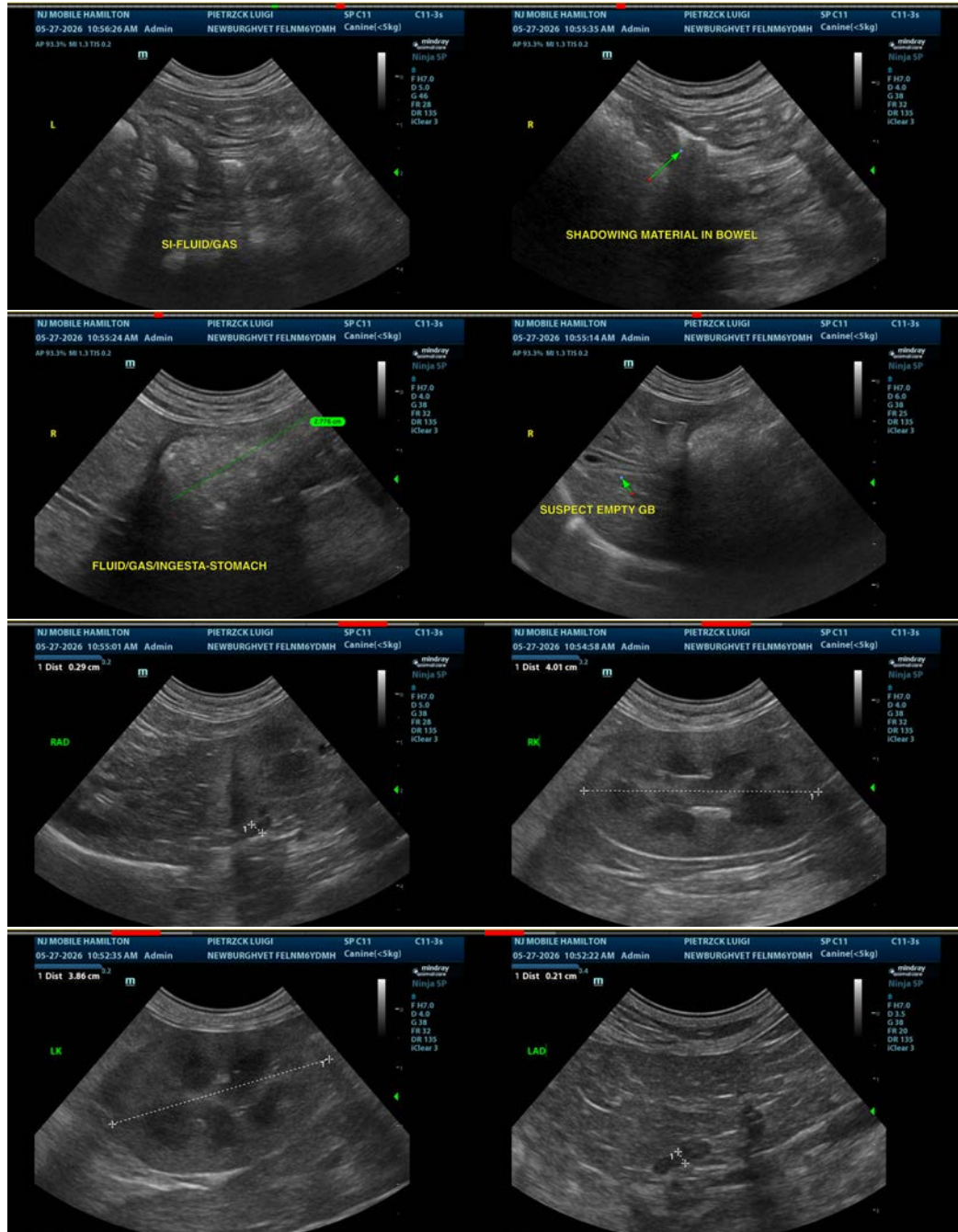
Dr. Harlec

INVOICE

75468

DATE

5/27/26





PATIENT

Luigi Pietrzck

The information and recommendations provided are based on the images presented by the referring veterinarian/sonographer. No evaluation can be communicated regarding pathology that was not visible in the image/video clips provided.

SPECIES

Feline

Thank you for this referral. If the clinical or image interpretation does not parallel your findings or if I can be of any further assistance please contact me.

Kathleen Sennello DVM,MS, Diplomate ACVIM (Small animal Internal Medicine)

BREED

DMH

info@sonopath.com

SEX

Neutered Male

AGE

6 Years

WEIGHT

10.9 lbs

INTERPRETED BY

Kathleen Sennello DVM,
MS, Diplomate ACVIM
(Small Animal Internal
Medicine)

**IMAGING
PERFORMED BY**

Rebecca Hamilton

HOSPITAL NAME

Newburgh Veterinary
Hospital

REFERRING VET

Dr. Harlec

INVOICE

75468

DATE

5/27/26