



PATIENT

Cassie Engel

SPECIES

Canine

BREED

Fox Wire Terrier

SEX

Spayed Female

AGE

4 Years 2 Months

WEIGHT

21.8 lbs

INTERPRETED BY

Kathleen Sennello DVM,
MS, Diplomate ACVIM
(Small Animal Internal
Medicine)

IMAGING PERFORMED BY

Mary Kermendy, CVT

HOSPITAL NAME

Wauwatosa Veterinary
Clinic

REFERRING VET

Dr. Kicker

INVOICE

75489

DATE

5/27/26

PRESENTING CLINICAL SIGNS

2 week history of waxing and waning appetite change, vomiting, and diarrhea. Short term response to probiotic 7 days ago and then relapse of diarrhea and vomiting, loss of appetite. No known hx of dietary indiscretion.

Abnormal PE/Chem/CBC/UA Results: ABNORMAL EXAM/LAB RESULTS: _Normal PE with mild dehydration, soft stool in rectum, and fecal staining on perineum.

ULTRASONOGRAPHIC EXAMINATION OF THE ABDOMEN

Urinary System

The urinary bladder is moderately distended with anechoic urine. The Bladder wall, trigone, ureteral papillae and visible urethra (to a depth of 2cm) appear normal with no evidence of wall thickening, mucosal irregularities, masses or cystic calculi.

The left kidney has a normal shape and size (4.36 cm). Overall echogenicity is normal with adequate corticomedullary distinction and a typical 1:3 cortex:medulla ratio. There is no evidence of focal perinephric inflammation or effusion. There is no evidence of pyelectasia, nephroliths, infarcts or hydroureter. Renal vasculature is normal.

The right kidney has a normal shape and size (4.43 cm). Overall echogenicity is normal with adequate corticomedullary distinction and a typical 1:3 cortex:medulla ratio. There is no evidence of focal perinephric inflammation or effusion. There is no evidence of pyelectasia, nephroliths, infarcts or hydroureter. Renal vasculature is normal.

Adrenal Glands

The region of left adrenal (Cranial to left renal artery) is unremarkable but the adrenal is not distinctly visualized. No evidence of a mass effect is visualized.

The region of the right adrenal (between right cranial kidney and vena cava) is unremarkable, but the adrenal is not distinctly visualized. No evidence of a mass effect is visualized.

Spleen

The spleen is subjectively normal in size (1.9 cm), echotexture is homogenous, and the splenic capsule is smooth with no irregularities. The blood flow through the hilus and splenic parenchyma appears normal. No focal parenchymal abnormalities are visualized.

Liver

The liver is subjectively normal in size, and echogenicity with smooth peripheral margins. The parenchyma is homogenous echotexture. The visible portions of the vasculature and biliary tract appear normal. No focal nodules or cystic lesions are observed.

The gall bladder lumen is moderately distended. The wall of the gall bladder is not thickened and has a smooth mucosal surface. There is a moderate amount of non-organized echogenic debris. The cystic and common bile ducts are normal/not visible.



PATIENT

Cassie Engel

SPECIES

Canine

BREED

Fox Wire Terrier

SEX

Spayed Female

AGE

4 Years 2 Months

WEIGHT

21.8 lbs

INTERPRETED BY

Kathleen Sennello DVM,
MS, Diplomate ACVIM
(Small Animal Internal
Medicine)

IMAGING PERFORMED BY

Mary Kermendy, CVT

HOSPITAL NAME

Wauwatosa Veterinary
Clinic

REFERRING VET

Dr. Kicker

INVOICE

75489

DATE

5/27/26

Gastrointestinal

The stomach contains minimal luminal contents. It measures at a normal thickness of <0.7cm with some variability due to the presence of rugal folds. The distinction of the gastric wall layers is adequate and there is no impression of reduced peristaltic activity. No masses or focal lesions were observed.

The visualized areas of duodenum, jejunum and ileum have a relatively uniform diameter with minimal fluid distension. Wall thickness is normal. Bowel loops follow a curvilinear path with distinct wall layering maintaining the typical 1:3 muscularis:mucosa layer ratio. Jejunum wall measures 0.24 cm. Visualized peristalsis appears appropriate. There were no focal lesions consistent with obstruction or a mass effect observed.

Sections of colon are visualized with formed fecal material and gas shadowing distally. There is no observed focal or generalized colon wall thickening or loss of layering.

Pancreas

The area of the pancreas is normal and isoechoic to surrounding mesentery. There is no evidence of nodules or cystic lesions. There is no evidence of regional mesenteric inflammation or fluid.

Free Abdomen

Evaluation of the peritoneal cavity did not reveal any evidence of effusion, or subjective lymphadenomegaly. The Medial iliac nodes appear normal and there was no evidence of a caudal aortic thrombus at the bifurcation. The omentum is of normal uniform echogenicity.

ULTRASONOGRAPHIC FINDINGS

- Moderate gallbladder debris – The significance of the aggregated gallbladder debris is unclear. This could represent an early mucocele, cholestasis, or may be secondary to fasting but seems unlikely to be causing a current issue. Recommend continued monitoring.

INTERPRETATION OF THE FINDINGS & FURTHER RECOMMENDATIONS

Today's scan appears relatively normal. No focal lesions were visualized associated with the GI tract to explain the symptoms reported. Unfortunately, this does not rule out the possibility of gastroenteritis/mild pancreatitis or even a primary enteropathy. If there is any concern for a focal lesion/obstructive lesion, repeat imaging could be considered in the future, looking for more pronounced change. Consider the following:

- If not already done, recommend full biochemical evaluation including urinalysis, CBC, and baseline cortisol to screen for atypical Addison's.
- Recommend parasite screening and empirical deworming.
- Consider screening for infectious causes of acute gastrointestinal symptoms.
- If symptoms are more chronic in nature, you could consider a diet trial with a hydrolyzed protein prescription diet.
- Consider a GI panel to Texas A&M for evaluation of B12 levels, folate, PLI/TLI etc.. to further evaluate for pancreatic/small intestinal disease.



PATIENT

Cassie Engel

SPECIES

Canine

BREED

Fox Wire Terrier

SEX

Spayed Female

AGE

4 Years 2 Months

WEIGHT

21.8 lbs

INTERPRETED BY

Kathleen Sennello DVM,
MS, Diplomate ACVIM
(Small Animal Internal
Medicine)

**IMAGING
PERFORMED BY**

Mary Kermendy, CVT

HOSPITAL NAME

Wauwatosa Veterinary
Clinic

REFERRING VET

Dr. Kicker

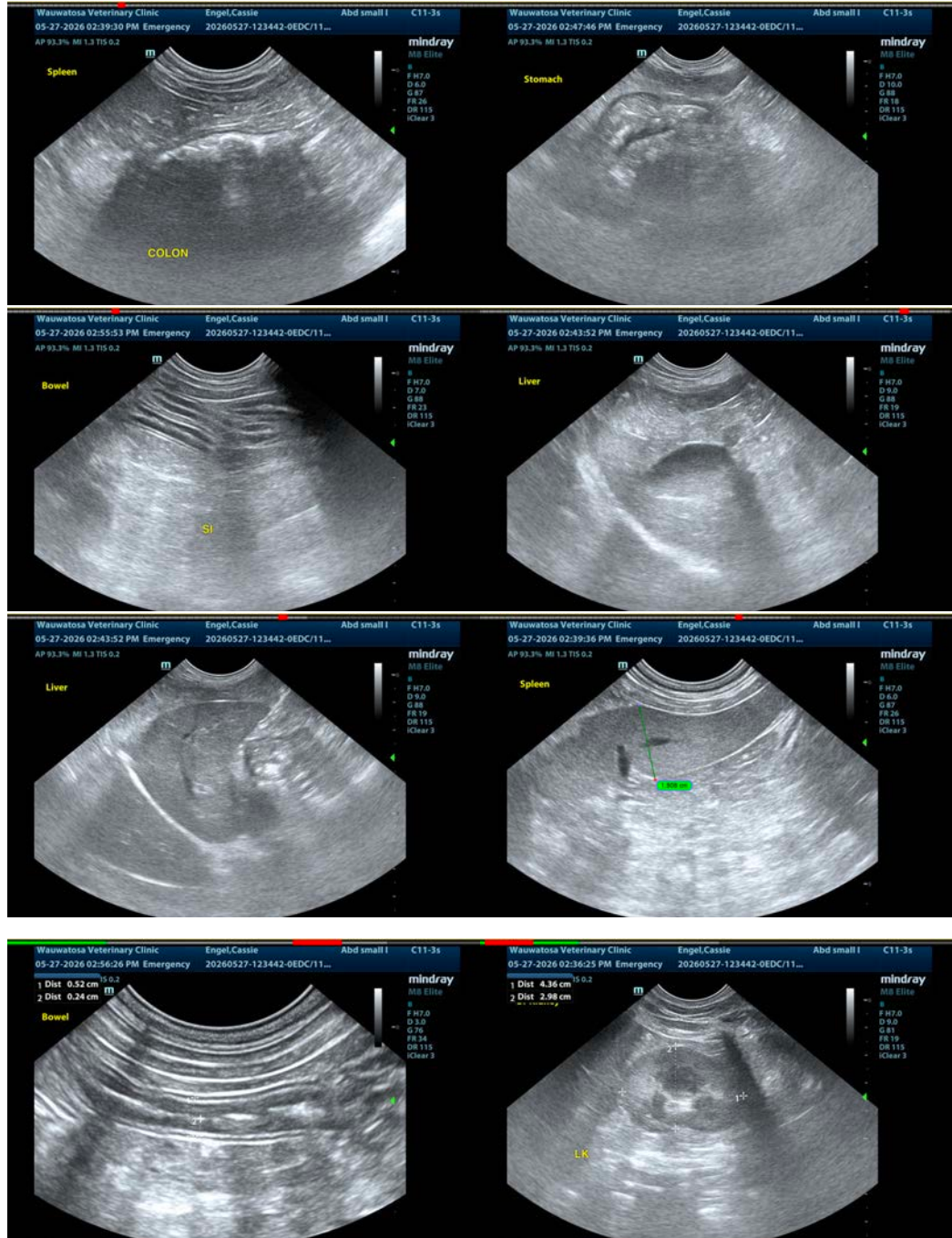
INVOICE

75489

DATE

5/27/26

If symptoms are persistent despite appropriate therapy, ultimately biopsies of the GI tract may be warranted. If symptoms are severe and acute and persistent, repeat imaging could be considered, looking for a more focal lesion.





PATIENT

Cassie Engel

SPECIES

Canine

BREED

Fox Wire Terrier

SEX

Spayed Female

AGE

4 Years 2 Months

WEIGHT

21.8 lbs

INTERPRETED BY

Kathleen Sennello DVM,
MS, Diplomate ACVIM
(Small Animal Internal
Medicine)

IMAGING PERFORMED BY

Mary Kermendy, CVT

HOSPITAL NAME

Wauwatosa Veterinary
Clinic

REFERRING VET

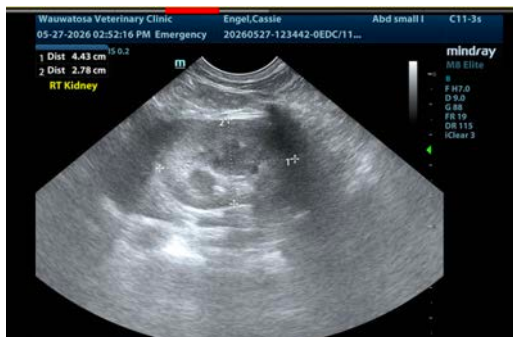Dr. Kicker

INVOICE

75489

DATE

5/27/26



The information and recommendations provided are based on the images presented by the referring veterinarian/sonographer. No evaluation can be communicated regarding pathology that was not visible in the image/video clips provided.

Thank you for this referral. If the clinical or image interpretation does not parallel your findings or if I can be of any further assistance please contact me.

Kathleen Sennello DVM,MS, Diplomate ACVIM (Small animal Internal Medicine)

info@sonopath.com