

IMAGING PERFORMED BY

IntraPet.com



SonoPath

Clinical Sonography & Telecytology

EDUCATIONAL TELECONSULTATION SERVICES™

1-800-838-4268 info@sonopath.com SonoPath.com

DATE PRESENTING CLINICAL SIGNS

5/26/22 Hx of chronic vomiting, diarrhea. Currently managed with cerenia, prednisone, tylosin. Weight loss despite management. Previous u/s in december concerning for GI neoplasia vs IBD

PATIENT

Roxy Barry Current Medications: None listed.
Date of Previous IntraPet Ultrasound: 12/23/21. See attached.
Sedation: Not required to complete full diagnostic ultrasound.
Stat Report: Declined.

SPECIES

Canine

ULTRASONOGRAPHIC EXAMINATION OF THE ABDOMEN

BREED

Jack Russell

SEX

Spayed Female

AGE

1/31/14

WEIGHT

12.6 Pounds

INTERPRETED BY

Kathleen Sennello DVM,
MS, Diplomate ACVIM
(Small Animal Internal
Medicine)

IMAGING PERFORMED BY

Stephanie Pearce
RDMS, RVT

HOSPITAL NAME

Bayside AMC

REFERRING VET

Dr. Buchanan

INVOICE

38012

Urinary System

The urinary bladder is moderately distended with anechoic urine. The Bladder wall is significantly irregular and thickened, particularly in the apical region of the urinary bladder with numerous focal mass like lesions, one of which measures 1.4 cm x 1.09 cm .The area of the trigone, ureteral papillae and visible urethra (to a depth of 2cm) appear free of any significant lesions, calculi, or mucosal irregularities. Findings are most concerning for a focal bladder mass, but a polyp or severe cystitis are possible.

The left kidney has a normal shape and size (4.08 cm). Overall echogenicity is normal with adequate corticomedullary distinction and a typical 1:3 cortex:medulla ratio. There is no evidence of perinephric inflammation or effusion. There is no evidence of pyelectasia, nephroliths, infarcts or hydroureter. Renal vasculature is normal.

The right kidney has a normal shape and size (4.3 cm). Overall echogenicity is normal with adequate corticomedullary distinction and a typical 1:3 cortex:medulla ratio. There is no evidence of perinephric inflammation or effusion. There is no evidence of pyelectasia, nephroliths, infarcts or hydroureter. Renal vasculature is normal.

Adrenal Glands

The left adrenal gland is normal in size measuring 0.30 cm at the caudal pole. It is observed in its normal position cranial to the left renal artery. It is normal in appearance (uniformly hypoechoic) and shape with no evidence of a mass effect.

The right adrenal gland is normal in size measuring 0.45 cm at the caudal pole. It is observed in its normal position between the cranial aspect of the right kidney and the caudal vena cava. It is normal in appearance (uniformly hypoechoic) and shape with no evidence of a mass effect.

Spleen

The spleen is subjectively normal in size, echotexture is homogenous, and the splenic capsule is smooth with no irregularities. The blood flow through the hilus and splenic parenchyma appears normal. No focal parenchymal abnormalities are visualized.

Liver

The liver is subjectively normal in size, and echogenicity with smooth peripheral margins. The parenchyma is homogenous echotexture. The visible portions of the vasculature and biliary tract appear normal. No focal nodules or cystic lesions are observed.

The gallbladder lumen is moderately distended. The wall of the gall bladder is not thickened and has a smooth mucosal surface. Luminal contents are primarily anechoic. The cystic and common bile ducts are normal/not visible.

Gastrointestinal

The stomach is moderately dilated with fluid and irregular shadowing material most consistent with normal ingesta and gas. It measures at a normal thickness of <0.7cm with some variability due to the presence of rugal folds. The distinction of the gastric wall layering is adequate and there is no impression of reduced peristaltic activity. No masses or focal lesions were observed.

Some of the visualized areas of jejunum and ileum have a uniform diameter with minimal fluid distension. Wall appears subjectively, moderately increased. Bowel loops follow a typical curvilinear path with distinct wall layering. Jejunum wall measured 0.30 cm. Visualized peristalsis appears appropriate. The proximal duodenum is severely focally thickened with a complete loss of layering and hypoechoic wall. In this region, the duodenal wall measures at approximately 1.3 cm, and the abnormal area extends for over 8.8 cm in length. These findings are most consistent with a focal duodenal mass (this lesion shows progression from the previous ultrasound performed 12/20/22, at that time duodenal wall measured 0.66 cm).

The ileocecal junction was visualized and exhibited normal intact wall layering and is subjectively of normal thickness. Sections of colon are visualized with formed fecal material and gas shadowing distally. There is no observed focal or generalized colon wall thickening or loss of layering.

Pancreas

The pancreas is normal and isoechoic to surrounding mesentery. There is no evidence of nodules or cystic lesions. There is no evidence of regional mesenteric inflammation or fluid.

Free Abdomen

There is a small amount of free fluid. There is a significant mesenteric lymphadenopathy with a mesenteric lymph node visualized measuring 2.0 cm, 1.7 cm, and 2.3 cm. The omentum is diffusely hyperechoic (there is significant progression of the lymphadenopathy since the last scan).

ULTRASONOGRAPHIC FINDINGS

- Large focal section of duodenum with severe wall thickening and complete loss of layering – findings are concerning for primary bowel mass. Primary differentials would be round cell neoplasia or carcinoma. Other possibilities exist.
- Focal bladder wall irregularities – most consistent with mass lesions. Other rule outs would include inflammatory polyps, etc.
- Moderate to severe mesenteric lymphadenopathy – The moderate mesenteric lymphadenopathy could be concerning for a neoplastic process, although you can see significant lymphadenopathy in some cases of autoimmune/inflammatory disease, infectious disease (tick born disease-such as bartonella, fungal infections, FIP (cats)) etc. A fine needle aspirate with cytology is recommended for further evaluation.

INTERPRETATION OF THE FINDINGS & FURTHER RECOMMENDATIONS

The previously described focal duodenal thickening and loss of layering has progressed. It is larger on today's scan, and the wall thickness has increased. These findings are more definitive for a mass lesion. Recommend a fine needle aspirate of the duodenal wall. Additionally, the surrounding lymphadenopathy is more severe with surrounding inflamed mesentery. Recommend a fine needle aspirate of a mesenteric lymph node.

Additionally, on today's scan there is focal irregularity in the urinary bladder wall. The focal mass in the bladder has the characteristics most consistent with a neoplastic lesion, but polyps and inflammatory lesions can sometimes have a similar appearance. A definitive diagnosis cannot be determined by ultrasound alone.

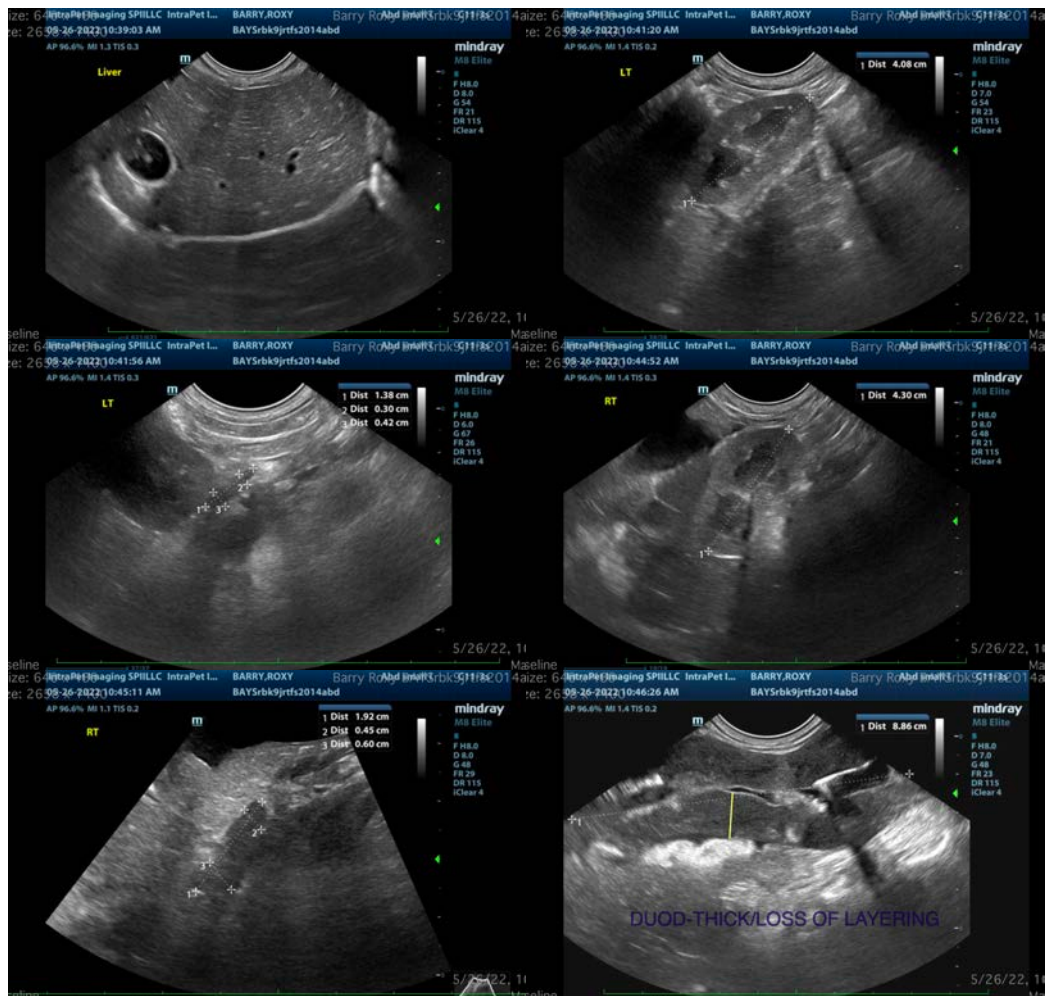
-Recommend urine evaluation for BRAF mutation seen in patients with transitional cell carcinomas. A positive test is diagnostic, a negative test is inconclusive and will need further diagnostics.

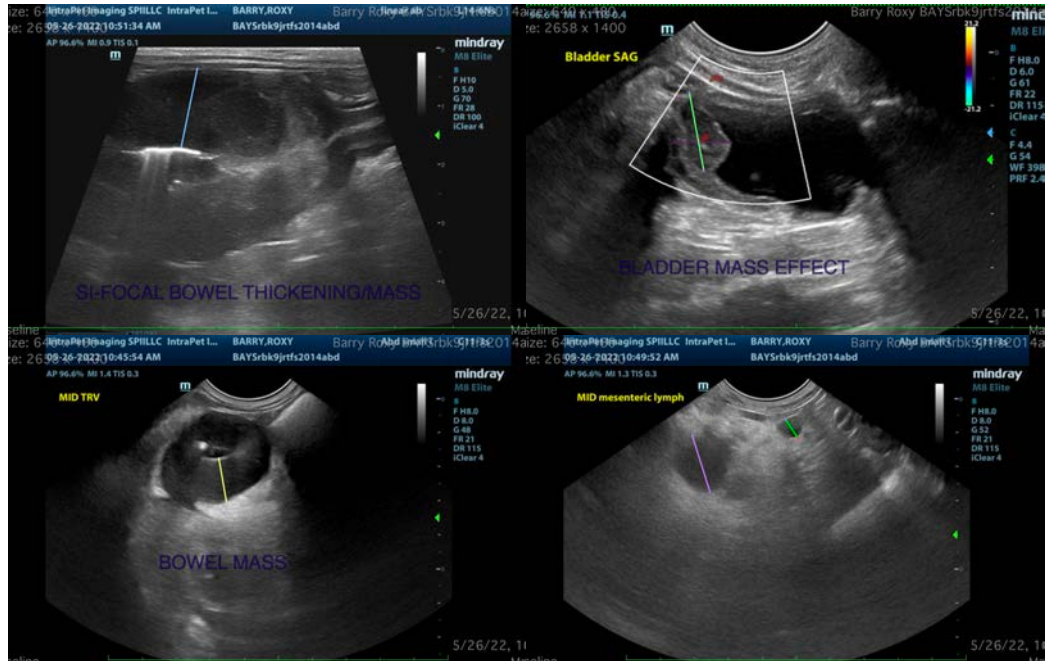
-If negative or non-diagnostic BRAF consider traumatic catheterization to obtain representative cells for cytology, or biopsy sampling via either cystoscopy (if a female) or surgery.

-Patients with bladder pathology should always have urinalysis and culture performed. Ideally cystocentesis should be avoided in patients with suspected bladder masses to try and prevent tracking of tumor cells along the needle path.

-If TCC is confirmed consider referral to/consultation with a board certified. Veterinary oncologist for recommendations regarding treatment options and prognosis.

Consider three view thoracic radiographs to rule out concurrent thoracic disease/involvement.





The information and recommendations provided are based on the images presented by the referring veterinarian/sonographer. No evaluation can be communicated regarding pathology that was not visible in the image/video clips provided.

Thank you for this referral. If the clinical or image interpretation does not parallel your findings or if I can be of any further assistance please contact me.

Kathleen Sennello DVM,MS, Diplomate ACVIM (Small animal Internal Medicine)
kathleen.sennello@sonopath.com