



PATIENT PRESENTING CLINICAL SIGNS

Molly Seviak History: recurrent GI issues(vomiting +/- diarrhea), currently also very lethargic and dehydrated

SPECIES

Abnormal PE/Chem/CBC/UA Results: please see attached BW, UPC normal. U/A: usg 1.013, bl 3+, gluc 2+, otherwise NAF

Feline

BREED

ULTRASONOGRAPHIC EXAMINATION OF THE ABDOMEN

Exotic Shorthair

Urinary System

The urinary bladder is moderately distended with anechoic urine. The Bladder wall, trigone, ureteral papillae and visible urethra (to a depth of 2cm) appear normal with no evidence of wall thickening, mucosal irregularities, masses or cystic calculi.

SEX

FS

The left kidney has a normal shape and size. Overall echogenicity is normal with decreased corticomedullary distinction and a typical 1:3 cortex:medulla ratio. There is no evidence of perinephric inflammation or effusion. There is no evidence of nephroliths, infarcts or hydroureter. An area of pyelectasia was present measuring 0.27 cm. Renal vasculature is normal. The left kidney measured 3.8 cm in length.

AGE

11 yr

WEIGHT

2.87 kg

The right kidney has a normal shape and size. Overall echogenicity is normal with decreased corticomedullary distinction and a typical 1:3 cortex:medulla ratio. There is no evidence of perinephric inflammation or effusion. There is no evidence of nephroliths, infarcts or hydroureter. An area of pyelectasia was present measuring 0.29 cm. Renal vasculature is normal. The right kidney measured 3.6 cm in length.

INTERPRETED BY

Kathleen Sennello DVM,
MS, Diplomate ACVIM
(Small Animal Internal
Medicine)

Adrenal Glands

The left adrenal gland is normal in size measuring 0.38 cm at the caudal pole. It is observed in its normal position cranial to the left renal artery. It is normal in appearance (uniformly hypoechoic) and shape with no evidence of a mass effect.

IMAGING PERFORMED BY

Kelly Reschny

The right adrenal gland is normal in size measuring 0.32 cm at the caudal pole. It is observed in its normal position between the cranial aspect of the right kidney and the caudal vena cava. It is normal in appearance (uniformly hypoechoic) and shape with no evidence of a mass effect.

HOSPITAL NAME

Sixteen Mile VC

Spleen

The spleen is subjectively normal in size, echotexture is homogenous, and the splenic capsule is smooth with no irregularities. The blood flow through the hilus and splenic parenchyma appears normal. No focal parenchymal abnormalities are visualized. The spleen measured 0.73 cm in height at the level of the hilus.

REFERRING VET

Dr. Gibbs

Liver

The liver is subjectively normal in size, and echogenicity with smooth peripheral margins. The parenchyma is homogenous echotexture. The visible portions of the vasculature and biliary tract appear normal. No focal nodules or cystic lesions are observed.

INVOICE

10682ag

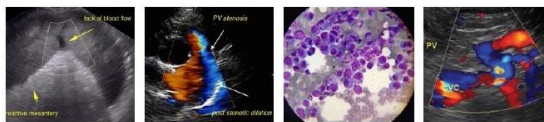
The gallbladder lumen is moderately distended. The wall of the gall bladder is not thickened and has a smooth mucosal surface. Luminal contents are primarily anechoic. The cystic and common bile ducts are normal/not visible.

DATE

05/26/2022

Gastrointestinal

The stomach contains minimal luminal contents. It measures at a normal thickness of <0.7cm with some variability due to the presence of rugal folds. The distinction of the gastric wall layers is



PATIENT

Molly Seviak

adequate and there is no impression of reduced peristaltic activity. No masses or focal lesions were observed.

SPECIES

Feline

The visualized areas of duodenum, jejunum and ileum have a relatively uniform diameter with minimal fluid distension. Wall thickness is normal. Bowel loops follow a curvilinear path with distinct wall layering maintaining the typical 1:3 muscularis:mucosa layer ratio. The duodenum measured as normal (between 0.3-0.5cm in wall thickness) and the jejunum measured as normal (between 0.2-0.47cm.) Visualized peristalsis appears appropriate. There were no focal lesions consistent with obstruction or a mass effect observed.

BREED

Exotic Shorthair

The ileocecal junction was visualized and exhibited normal intact wall layering and is subjectively of normal thickness. Sections of colon are visualized with formed fecal material and gas shadowing distally. There is no observed focal or generalized colon wall thickening or loss of layering.

SEX

FS

Pancreas

The pancreas is normal and isoechoic to surrounding mesentery. There is no evidence of nodules or cystic lesions. There is no evidence of regional mesenteric inflammation or fluid.

AGE

11 yr

Free Abdomen

Evaluation of the peritoneal cavity did not reveal any evidence of effusion, or subjective lymphadenomegaly. The Medial iliac nodes appear normal and there was no evidence of a caudal aortic thrombus at the bifurcation. The omentum is of normal uniform echogenicity.

WEIGHT

2.87 kg

ULTRASONOGRAPHIC FINDINGS

- Decreased medullary distinction in both kidneys with bilateral pyelectasia. Mild loss of corticomedullary distinction in both kidneys could be consistent with chronic degenerative disease or interstitial nephrosis. Pyelectasia of the left/right kidney could be consistent with pyelonephritis, chronic renal disease, secondary to PU/PD or fluid therapy (if applicable), other.

INTERPRETED BY

Kathleen Sennello DVM,
MS, Diplomate ACVIM
(Small Animal Internal
Medicine)

INTERPRETATION OF THE FINDINGS & FURTHER RECOMMENDATIONS

IMAGING PERFORMED BY

Kelly Reschny

The changes observed in the kidneys are most consistent with chronic renal disease although there is bilateral pyelectasia. Recommend BP evaluation, UA and C/S to look for evidence of active pyelonephritis or a possible acute on chronic episode.

HOSPITAL NAME

Sixteen Mile VC

Based on the blood work provided the elevated renal values could be responsible for the current GI signs although much of this could be pre-renal? No focal GI lesions were observed on today's scan although there are many causes of vomiting and diarrhea which cannot be diagnosed by ultrasound alone. Recommend rehydration and further evaluation of the kidneys. If there is concern for underlying GI disease, then:

REFERRING VET

Dr. Gibbs

- Recommend a hydrolyzed/novel protein diet
- Consider GI panel to Texas A&M for a qualitative fPLI/TLI/Cobalamin/Folate to further evaluate the pancreas and small intestine
- Consider chronic probiotic therapy
- If symptoms persist and renal disease is not a significant factor, consider containing GI biopsies
- Recommend three view thoracic radiographs

INVOICE

10682ag

DATE

05/26/2022



PATIENT

Molly Seviak

SPECIES

Feline

BREED

Exotic Shorthair

SEX

FS

AGE

11 yr

WEIGHT

2.87 kg

INTERPRETED BY

Kathleen Sennello DVM,
MS, Diplomate ACVIM
(Small Animal Internal
Medicine)

**IMAGING
PERFORMED BY**

Kelly Reschny

HOSPITAL NAME

Sixteen Mile VC

REFERRING VET

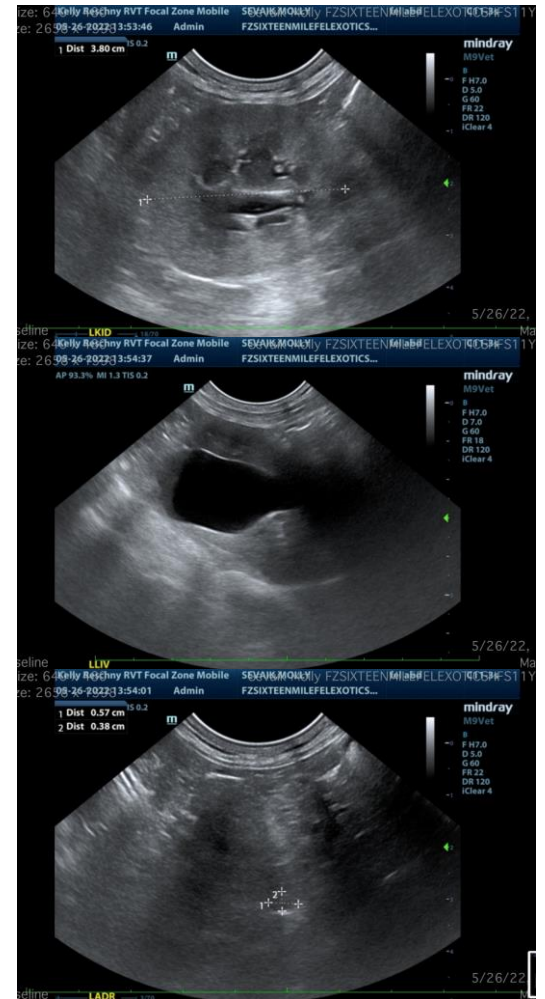
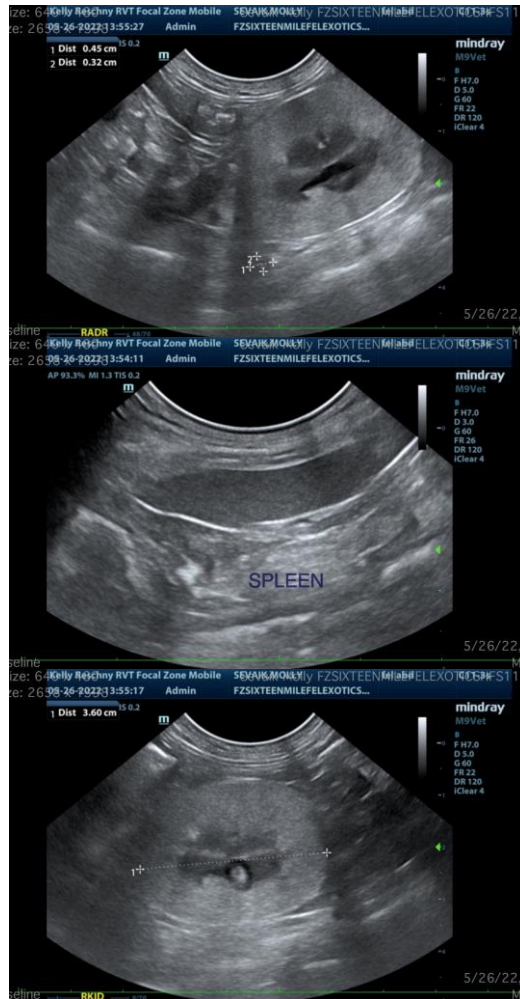Dr. Gibbs

INVOICE

10682ag

DATE

05/26/2022



The information and recommendations provided are based on the images presented by the referring veterinarian/sonographer. No evaluation can be communicated regarding pathology that was not visible in the image/video clips provided.

Thank you for this referral. If the clinical or image interpretation does not parallel your findings or if I can be of any further assistance please contact me.

Kathleen Sennello DVM,MS, Diplomate ACVIM (Small animal Internal Medicine)
kathleen.sennello@sonopath.com