



**PATIENT**

Mikey McNichol

**SPECIES**

Canine

**BREED**

Cockapoo

**SEX**

Neutered Male

**AGE**

7.5 Years

**WEIGHT**

36.6 Pounds

**INTERPRETED BY**

Kathleen Sennello DVM,  
MS, Diplomate ACVIM  
(Small Animal Internal  
Medicine)

**IMAGING  
PERFORMED BY**

Dr. Tam Mengine

**HOSPITAL NAME**

Stoney Creek VH

**REFERRING VET**

Dr. Tam Mengine

**INVOICE**

38003

**DATE**

5/26/22

**PRESENTING CLINICAL SIGNS**

Had AUS elsewhere in 12/19 - 1.6 x 2cm splenic mass noted in head of spleen, kidneys were described as "cortices bilaterally echogenic and patchy with mild pyelectasia"

Abnormal PE/Chem/CBC/UA Results: Newly diagnosed azotemia (BUN 36, Creat 2.3, SDMA 21), U/A unremarkable except SpGr 1.009. Normotensive

**ULTRASONOGRAPHIC EXAMINATION OF THE ABDOMEN**

**Urinary System**

The urinary bladder is moderately distended with anechoic urine. The Bladder wall, trigone, ureteral papillae and visible urethra (to a depth of 2cm) appear normal with no evidence of wall thickening, mucosal irregularities, masses or cystic calculi.

The prostate is large, measuring 1.6 cm in height in the sagittal view. It is slightly irregular and heterogeneous. The prostatic urethra appears normal with no evidence of irregularity, invasion, mass effect, or calculi. There is a focal hypoechoic region within the parenchyma measuring 0.41 cm x 0.61 cm. This could be consistent with a slightly echogenic cyst, abscess, or small nodule.

The left kidney has a normal shape and size (4.05 cm) with pyelectasia at 0.25 cm. Overall echogenicity is slightly hyperechoic with poor corticomedullary distinction and a typical 1:3 cortex:medulla ratio. There is no evidence of perinephric inflammation or effusion. There is no evidence of nephroliths, infarcts or hydronephrosis. Renal vasculature is normal.

The right kidney has a normal shape and size (4.71 cm) with mild pyelectasia at 0.21 cm. Overall echogenicity is slightly hyperechoic with poor corticomedullary distinction and a typical 1:3 cortex:medulla ratio. There is no evidence of perinephric inflammation or effusion. There is no evidence of nephroliths, infarcts or hydronephrosis. Renal vasculature is normal.

**Adrenal Glands**

The left adrenal gland is normal/borderline small at 0.33 cm at the caudal pole. It is observed in its normal position cranial to the left renal artery. It is normal in appearance (uniformly hypoechoic) and shape with no evidence of a mass effect.

The right adrenal gland is normal in size measuring 0.40 cm at the caudal pole. It is observed in its normal position between the cranial aspect of the right kidney and the caudal vena cava. It is normal in appearance (uniformly hypoechoic) and shape with no evidence of a mass effect.

**Spleen**

The spleen is subjectively normal in size, echotexture is homogenous, and the splenic capsule is smooth with no irregularities. The blood flow through the hilus and splenic parenchyma appears normal. There is a mixed echogenic, ill-defined mass effect near the head of the spleen, measuring 1.69 cm x 1.7 cm (previous measurement of 1.6 cm x 2.0 cm on 12/2019).

**Liver**

The liver is subjectively normal in size, and echogenicity with smooth peripheral margins. The parenchyma is homogenous echotexture. The visible portions of the vasculature and biliary tract appear normal. No focal nodules or cystic lesions are observed.

The gallbladder lumen is moderately distended. The wall of the gall bladder is not thickened and has a smooth mucosal surface. Luminal contents are primarily anechoic. The cystic and common bile ducts are normal/not visible.



**PATIENT**

Mikey McNichol

**Gastrointestinal**

The stomach contains minimal luminal contents. It measures at a normal thickness of <0.7cm with some variability due to the presence of rugal folds. The distinction of the gastric wall layers is adequate and there is no impression of reduced peristaltic activity. No masses or focal lesions were observed.

**SPECIES**

Canine

The visualized areas of duodenum, jejunum and ileum have a relatively uniform diameter with minimal fluid distension. Wall thickness is normal. Bowel loops follow a curvilinear path with distinct wall layering maintaining the typical 1:3 muscularis:mucosa layer ratio. Duodenum wall measured 0.49 cm. Jejunum wall measured 0.35, 0.37 cm. Visualized peristalsis appears appropriate. There were no focal lesions consistent with obstruction or a mass effect observed.

**BREED**

Cockapoo

The ileocecal junction was visualized and exhibited normal intact wall layering and is subjectively of normal thickness. Sections of colon are visualized with formed fecal material and gas shadowing distally. There is no observed focal or generalized colon wall thickening or loss of layering.

**SEX**

Neutered Male

**Pancreas**

The pancreas is normal and isoechoic to surrounding mesentery. There is no evidence of nodules or cystic lesions. There is no evidence of regional mesenteric inflammation or fluid.

**AGE**

7.5 Years

**Free Abdomen**

Evaluation of the peritoneal cavity did not reveal any evidence of effusion, or subjective lymphadenomegaly. The Medial iliac nodes appear normal and there was no evidence of a caudal aortic thrombus at the bifurcation. The omentum is of normal uniform echogenicity.

**WEIGHT**

36.6 Pounds

**ULTRASONOGRAPHIC FINDINGS**

**INTERPRETED BY**

Kathleen Sennello DVM,  
MS, Diplomate ACVIM  
(Small Animal Internal  
Medicine)

- Decreased corticomedullary distinction in both kidneys with mild pyelectasia – Poor corticomedullary distinction in both kidneys could be consistent with chronic degenerative disease or interstitial nephrosis. Pyelectasia of the left/right kidney could be consistent with pyelonephritis, chronic renal disease, secondary to PU/PD or fluid therapy (if applicable), other.
- Mixed echogenic mass effect near the head of the spleen – This lesion has been stable since the last scan over two years ago, so this is likely incidental. Recommend continued monitoring.
- Large, slightly irregular, heterogeneous prostate with focal hypoechoic lesion – Correlate with the age of neutering. If this patient was an adult, this could represent an involuted prostate. If this patient was neutered prior to puberty, recommend a fine needle aspirate, urinalysis and culture.

**IMAGING PERFORMED BY**

Dr. Tam Mengine

**HOSPITAL NAME**

Stoney Creek VH

**INTERPRETATION OF THE FINDINGS & FURTHER RECOMMENDATIONS**

**REFERRING VET**

Dr. Tam Mengine

The changes described in the kidneys are consistent with chronic progressive renal disease. Consider a urinalysis, culture and blood pressure evaluation as well as urine protein and creatinine ratio to obtain a baseline and to evaluate for evidence of pyelonephritis.

**INVOICE**

38003

The prostate is large and irregular for a neutered dog. This can be seen in some adults when a dog is neutered after puberty, and the prostate has involuted, but if this dog was neutered at a young age, then current prostatic disease is possible. Recommend a urinalysis and culture and continued monitoring of the hypoechoic region of the prostate. If there is concern for prostatic disease, a fine needle aspirate could be considered.

**DATE**

5/26/22

The previously described splenic lesion appears stable. Recommend continued monitoring.



**PATIENT**

Mikey McNichol

**SPECIES**

Canine

**BREED**

Cockapoo

**SEX**

Neutered Male

**AGE**

7.5 Years

**WEIGHT**

36.6 Pounds

**INTERPRETED BY**

Kathleen Sennello DVM,  
MS, Diplomate ACVIM  
(Small Animal Internal  
Medicine)

**IMAGING  
PERFORMED BY**

Dr. Tam Mengine

**HOSPITAL NAME**

Stoney Creek VH

**REFERRING VET**

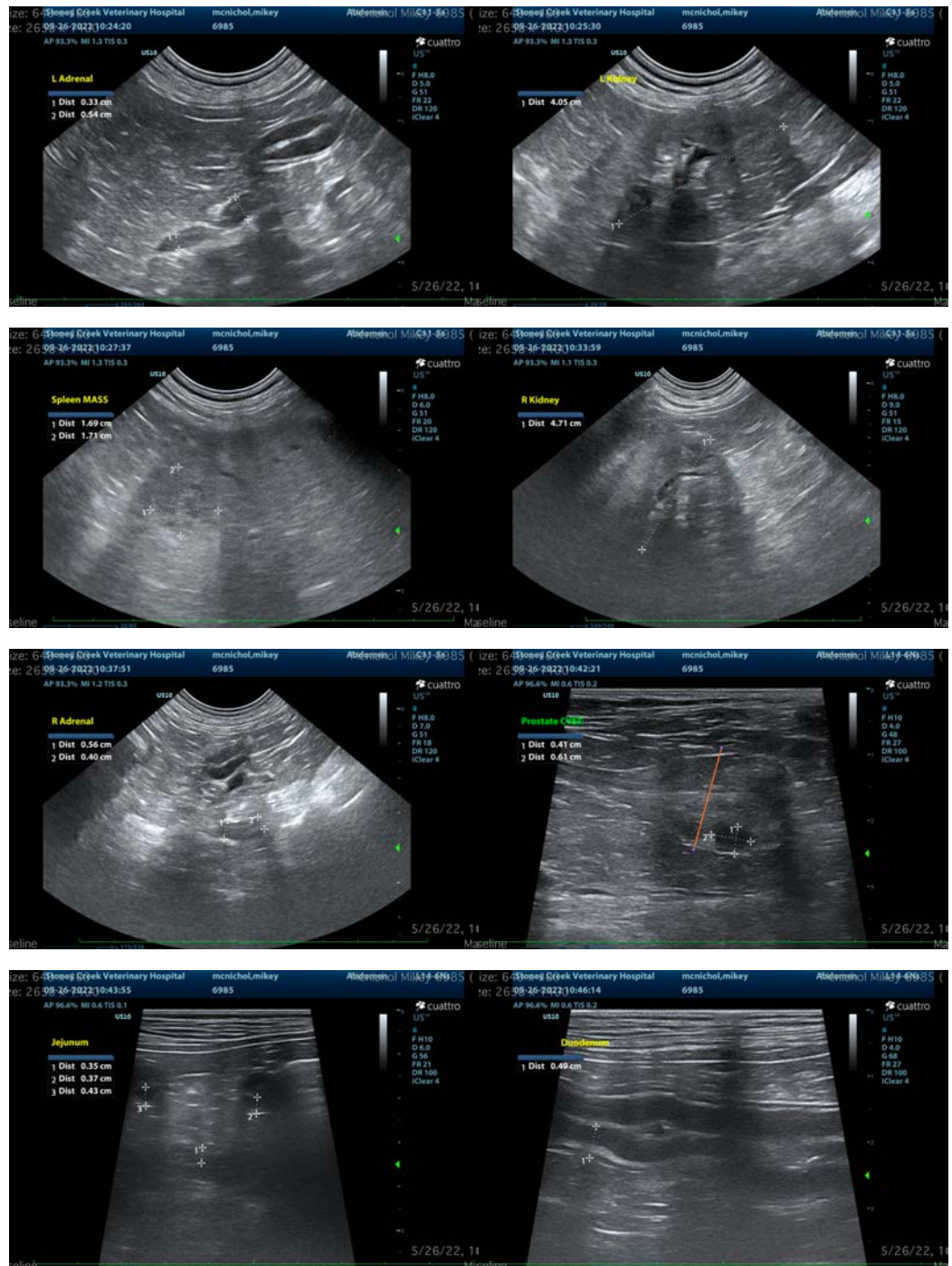
Dr. Tam Mengine

**INVOICE**

38003

**DATE**

5/26/22





**PATIENT**

Mikey McNichol

**SPECIES**

Canine

**BREED**

Cockapoo

**SEX**

Neutered Male

**AGE**

7.5 Years

**WEIGHT**

36.6 Pounds

**INTERPRETED BY**

Kathleen Sennello DVM,  
MS, Diplomate ACVIM  
(Small Animal Internal  
Medicine)

**IMAGING  
PERFORMED BY**

Dr. Tam Mengine

**HOSPITAL NAME**

Stoney Creek VH

**REFERRING VET**

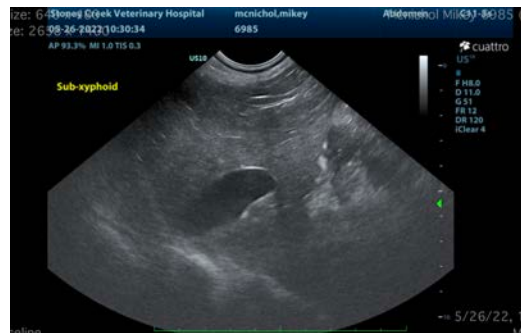Dr. Tam Mengine

**INVOICE**

38003

**DATE**

5/26/22



The information and recommendations provided are based on the images presented by the referring veterinarian/sonographer. No evaluation can be communicated regarding pathology that was not visible in the image/video clips provided.

Thank you for this referral. If the clinical or image interpretation does not parallel your findings or if I can be of any further assistance please contact me.

Kathleen Sennello DVM,MS, Diplomate ACVIM (Small animal Internal Medicine)

kathleen.sennello@sonopath.com