



**PATIENT**

Bosco Richardson

**SPECIES**

Canine

**BREED**

Lab

**SEX**

Neutered Male

**AGE**

10 Years

**WEIGHT**

115 Pounds

**INTERPRETED BY**

Kathleen Sennello DVM,  
MS, Diplomate ACVIM  
(Small Animal Internal  
Medicine)

**IMAGING  
PERFORMED BY**

Dr. Adrienne Waffle

**HOSPITAL NAME**

Torch Lake VC

**REFERRING VET**

Dr. Adrienne Waffle

**INVOICE**

38008

**DATE**

5/26/22

**PRESENTING CLINICAL SIGNS**

Pendulous abdomen noted on PE

Abnormal PE/Chem/CBC/UA Results: HCT 20 % SDMA - 16 BUN 33 ALP - 851 AMYL - 1846 K - 6.2 TT4 - 0.7

**ULTRASONOGRAPHIC EXAMINATION OF THE ABDOMEN**

**Urinary System**

The urinary bladder is moderately distended with anechoic urine. The Bladder wall, trigone, ureteral papillae and visible urethra (to a depth of 2cm) appear normal with no evidence of wall thickening, mucosal irregularities, masses or cystic calculi.

The visualized areas of prostate and surrounding tissue appear normal. Unfortunately, the prostate is not fully visualized likely due to its intrapelvic location. Correlate with rectal exam findings.

The left kidney has a normal shape and size (7.8 cm). Overall echogenicity is slightly hyperechoic with poor corticomedullary distinction and a typical 1:3 cortex:medulla ratio. There is no evidence of perinephric inflammation or effusion. There is no evidence of pyelectasia, nephroliths, infarcts or hydroureter. Renal vasculature is normal.

The right kidney has a normal shape and size (7.69 cm). Overall echogenicity is slightly hyperechoic with poor corticomedullary distinction and a typical 1:3 cortex:medulla ratio. There is no evidence of perinephric inflammation or effusion. There is no evidence of pyelectasia, nephroliths, infarcts or hydroureter. Renal vasculature is normal.

**Adrenal Glands**

The left adrenal gland was obscured by the large abdominal mass.

The right adrenal gland was obscured by the large abdominal mass.

**Spleen**

The spleen is large and irregular. The spleen echotexture is heterogenous and mottled. The blood flow through the hilus and splenic parenchyma appears normal. The spleen is visible extending beyond the urinary bladder. It is large, meaty, and irregular with hypoechoic nodules. One such nodule is visualized at 2.58 cm. There is a very large mixed echogenic, partially cavitated mass effect in the mid caudal abdomen measuring >18 cm x 19 cm. This mass lesion contacts the spleen and I suspect it originates from the spleen, but a direct vascular connection is not confirmed.

**Liver**

The liver is subjectively normal in size, and echogenicity with smooth peripheral margins. The parenchyma is heterogenous in echotexture with subtle, indistinct focal mottling. The visible portions of the vasculature and biliary tract appear normal. A hyperechoic mass effect is visualized within the parenchyma measuring 4.0 cm. The large abdominal mass touches the liver, but a direct connection is not observed.

The gallbladder lumen is moderately distended. The wall of the gall bladder is not thickened and has a smooth mucosal surface. Luminal contents are primarily anechoic. The cystic and common bile ducts are normal/not visible.

**Gastrointestinal**

The stomach was obscured by the large abdominal mass.



**PATIENT**

Bosco Richardson

The visualized areas of duodenum, jejunum and ileum have a relatively uniform diameter with minimal fluid distension. Wall thickness is normal. Bowel loops follow a curvilinear path with distinct wall layering maintaining the typical 1:3 muscularis:mucosa layer ratio. The duodenum measured as normal (between 0.3-0.5cm in wall thickness) and the jejunum measured as normal (between 0.2-0.47cm.) Visualized peristalsis appears appropriate. There were no focal lesions consistent with obstruction or a mass effect observed.

**SPECIES**

Canine

The ileocecal junction was visualized and exhibited normal intact wall layering and is subjectively of normal thickness. Sections of colon are visualized with formed fecal material and gas shadowing distally. There is no observed focal or generalized colon wall thickening or loss of layering.

**BREED**

Lab

**Pancreas**

The pancreas was obscured by the large abdominal mass.

**SEX**

Neutered Male

**Free Abdomen**

There is a small amount of free abdominal fluid. No lymphadenopathy is noted. The omentum is generally of increased echogenicity.

**AGE**

10 Years

**ULTRASONOGRAPHIC FINDINGS**

**WEIGHT**

115 Pounds

- Very large, mixed echogenic, partially cavitated mid abdominal mass – Based on the large, irregular appearance of the spleen, I suspect this mass effect is splenic in origin, but this cannot be confirmed.
- Heterogeneous liver with hyperechoic mass lesion – The diffuse hepatic changes are non-specific and could be consistent with vacuolar hepatopathy, nodular hyperplasia, inflammatory/immune-mediated disease, fibrosis, extramedullary hematopoiesis, toxic hepatopathy (e.g., copper), infiltrative neoplasia (less likely) or other hepatopathy.
- Decreased corticomedullary distinction in both kidneys – The bilateral renal findings are consistent with age-related change.

**INTERPRETED BY**

Kathleen Sennello DVM,  
MS, Diplomate ACVIM  
(Small Animal Internal  
Medicine)

**INTERPRETATION OF THE FINDINGS & FURTHER RECOMMENDATIONS**

**IMAGING PERFORMED BY**

Dr. Adrienne Waffle

There is a very large, partially cavitated mid abdominal mass that is obscuring visualization of much of the abdominal structures. Based on the large abnormal areas of spleen visualized, I suspect this is originating from the spleen, but a direct connection cannot be identified. Alternately, this could be of hepatic origin or some other mid abdominal structure. Concern for a neoplastic process is high based on the abnormal appearance of the visible spleen.

**HOSPITAL NAME**

Torch Lake VC

Options moving forward include referral to a veterinary surgeon for exploratory and attempt at removal of the mass lesion, or a contrast CT scan to further evaluate prior to surgery.

**REFERRING VET**

Dr. Adrienne Waffle

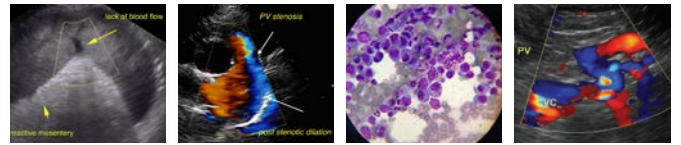
Consider three view thoracic radiographs to rule out concurrent thoracic disease/involvement.

**INVOICE**

38008

**DATE**

5/26/22



**PATIENT**

Bosco Richardson

**SPECIES**

Canine

**BREED**

Lab

**SEX**

Neutered Male

**AGE**

10 Years

**WEIGHT**

115 Pounds

**INTERPRETED BY**

Kathleen Sennello DVM,  
MS, Diplomate ACVIM  
(Small Animal Internal  
Medicine)

**IMAGING  
PERFORMED BY**

Dr. Adrienne Waffle

**HOSPITAL NAME**

Torch Lake VC

**REFERRING VET**

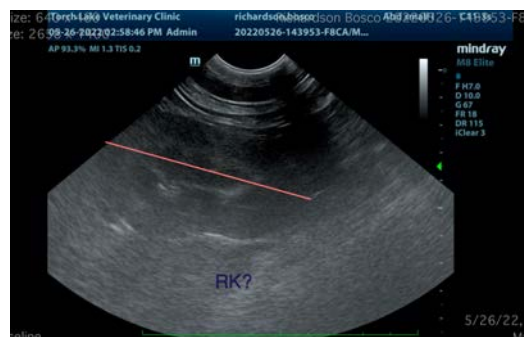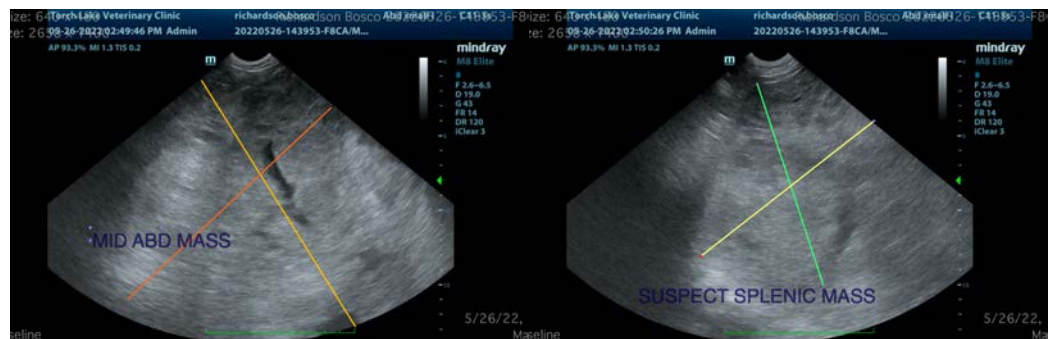
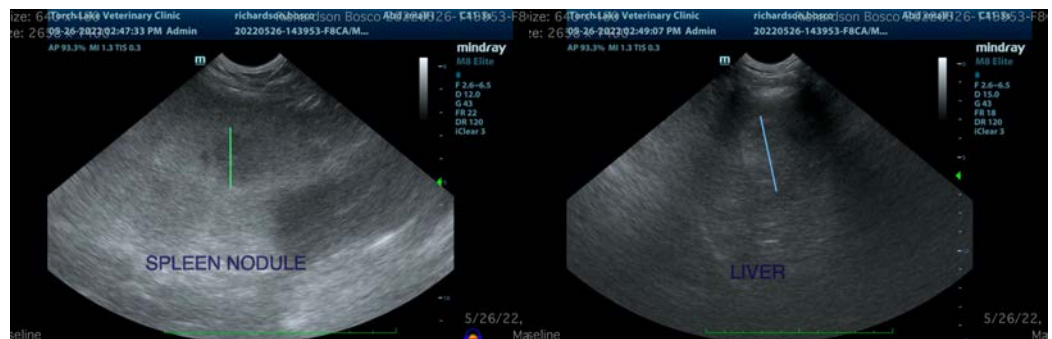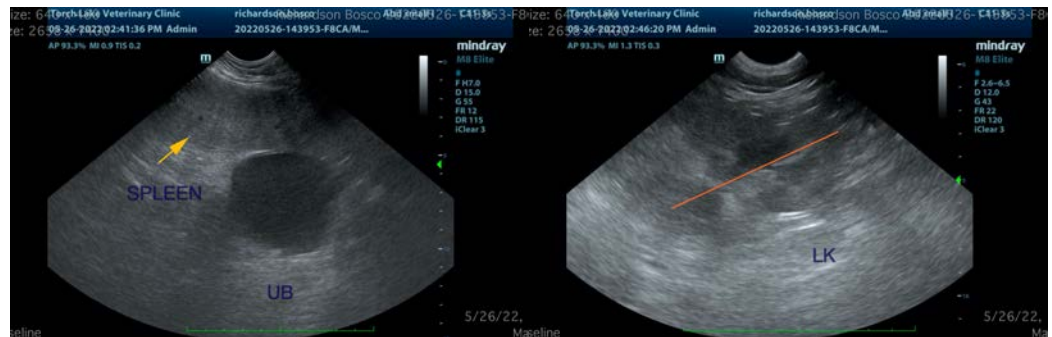Dr. Adrienne Waffle

**INVOICE**

38008

**DATE**

5/26/22



The information and recommendations provided are based on the images presented by the referring veterinarian/sonographer. No evaluation can be communicated regarding pathology that was not visible in the image/video clips provided.

Thank you for this referral. If the clinical or image interpretation does not parallel your findings or if I can be of any further assistance please contact me.

Kathleen Sennello DVM,MS, Diplomate ACVIM (Small animal Internal Medicine)

kathleen.sennello@sonopath.com