



**PATIENT**

Hana El Semman

**SPECIES**

Feline

**BREED**

Japanese Bobtail

**SEX**

Spayed Female

**AGE**

11 years

**WEIGHT**

4 lbs

**INTERPRETED BY**

Kathleen Sennello  
DVM, MS, Diplomate  
ACVIM (Small Animal  
Internal Medicine)

**IMAGING PERFORMED BY**

Dr. Sorbo

**HOSPITAL NAME**

Back Bay VC

**REFERRING VET**

Dr. Sorbo

**INVOICE**

30589

**DATE**

5/20/22

**PRESENTING CLINICAL SIGNS**

History: Not seen for years. Severe weight loss, but unknown recent previous weight, but was >8lbs in 2016. 4.4lbs now. Appetite is reportedly normal and water intake normal. Today: 3-view CXR, AUS -- > SonoPath, BP, GI panel with TLI.

Abnormal PE/Chem/CBC/UA Results: Emaciated, dental disease is moderate. Microcytic hypochromic non-regenerative anemia of 17.7% PCV, elevated band neuts, alb 2.1g/dL. UPC 0.4. T4 normal at 1.2. USFG 1.035. Fecal normal. BP = 100-110mmHg systolic. FF in abdomen = clear, likely transudate. Total solids = 1g/dL.

**ULTRASONOGRAPHIC EXAMINATION OF THE ABDOMEN**

**Urinary System**

The urinary bladder is moderately distended with anechoic urine. The Bladder wall, trigone, ureteral papillae and visible urethra (to a depth of 2cm) appear normal with no evidence of wall thickening, mucosal irregularities, masses or cystic calculi.

The left kidney has a normal shape and size (3.5 cm). Overall echogenicity is normal with adequate corticomedullary distinction and a typical 1:3 cortex:medulla ratio. There is no evidence of perinephric inflammation or effusion. There is no evidence of pyelectasia, nephroliths, infarcts or hydroureter. Renal vasculature is normal.

The right kidney has a normal shape and size (3.8 cm). Overall echogenicity is normal with adequate corticomedullary distinction and a typical 1:3 cortex:medulla ratio. There is no evidence of perinephric inflammation or effusion. There is no evidence of pyelectasia, nephroliths, infarcts or hydroureter. Renal vasculature is normal.

**Adrenal Glands**

The left adrenal gland is normal in size measuring 0.32 cm at the caudal pole It is observed in its normal position cranial to the left renal artery. It is normal in appearance (uniformly hypoechoic) and shape with no evidence of a mass effect.

The region of the right adrenal (between right cranial kidney and vena cava) is unremarkable, but the adrenal is not distinctly visualized. No evidence of a mass effect.

**Spleen**

The spleen is subjectively normal in size, echotexture is homogenous, and the splenic capsule is smooth with no irregularities. The blood flow through the hilus and splenic parenchyma appears normal. No focal parenchymal abnormalities are visualized.

**Liver**

The liver is subjectively normal in size, and echogenicity with smooth peripheral margins. The parenchyma is heterogenous in echotexture with subtle, indistinct focal mottling. The visible portions of the vasculature and biliary tract appear normal. No focal nodules or cystic lesions are observed. The gallbladder lumen is moderately distended. The wall of the gallbladder is not thickened and has a



**PATIENT**

Hana El Semman

smooth mucosal surface. Luminal contents are primarily anechoic. The cystic and common bile ducts are normal/not visible.

**SPECIES**

Feline

**Gastrointestinal**

The stomach contains minimal luminal contents. It measures at a normal thickness of <0.7cm with some variability due to the presence of rugal folds. The distinction of the gastric wall layers is adequate and there is no impression of reduced peristaltic activity. No masses or focal lesions were observed.

**BREED**

Japanese Bobtail

The visualized areas of duodenum, jejunum and ileum have a relatively uniform diameter with minimal fluid distension. Wall thickness is normal. Bowel loops follow a curvilinear path with distinct wall layering maintaining the typical 1:3 muscularis:mucosa layer ratio. The jejunum measured 0.24 cm. Visualized peristalsis appears appropriate. There were no focal lesions consistent with obstruction or a mass effect observed.

**SEX**

Spayed Female

The ileocecal junction was visualized and exhibited normal intact wall layering and is subjectively of normal thickness. Sections of colon are visualized with formed fecal material and gas shadowing distally. There is no observed focal or generalized colon wall thickening or loss of layering.

**AGE**

11 years

**Pancreas**

**WEIGHT**

4 lbs

There is some irregular, hypoechoic tissue that is visualized cranial to the left kidney measuring 1.02 cm in diameter. This could be consistent with a lymph node/irregular pancreatic tissue.

**INTERPRETED BY**

Kathleen Sennello  
DVM, MS, Diplomate  
ACVIM (Small Animal  
Internal Medicine)

**Free Abdomen**

There is a moderate amount of free abdominal fluid. There is a round, hypoechoic structure that is visualized cranial to the right kidney. This may be consistent with a lymph node and measured 0.67 cm. The omentum is generally hyperechoic compared to the hypoechoic fluid in the abdomen.

**IMAGING PERFORMED BY**

Dr. Sorbo

**ULTRASONOGRAPHIC FINDINGS**

**HOSPITAL NAME**

Back Bay VC

**PRIMARY FINDINGS:**

- Possible, irregular tissue cranial to the left kidney. Differentials include abnormal pancreas, lymphatic tissue, omental nodules, etc.
- Heterogenous liver. The diffuse hepatic changes are non-specific and could be consistent with vacuolar hepatopathy, nodular hyperplasia, inflammatory/immune-mediated disease, fibrosis, extramedullary hematopoiesis, toxic hepatopathy (e.g., copper), infiltrative neoplasia (less likely) or other hepatopathy.
- Round, hypoechoic structure cranial to the right kidney. This lesion is most consistent with a prominent lymph node.
- The prominent abdominal lymph nodes are most consistent with reactive lymphadenitis or lymphoid hyperplasia. Neoplastic infiltration is considered less likely.
- Moderate amount of free abdominal fluid.

**REFERRING VET**

Dr. Sorbo

**INVOICE**

30589

**DATE**

5/20/22



**PATIENT**

Hana El Semman

**SPECIES**

Feline

**BREED**

Japanese Bobtail

**SEX**

Spayed Female

**AGE**

11 years

**WEIGHT**

4 lbs

**INTERPRETED BY**

Kathleen Sennello  
DVM, MS, Diplomate  
ACVIM (Small Animal  
Internal Medicine)

**IMAGING PERFORMED BY**

Dr. Sorbo

**HOSPITAL NAME**

Back Bay VC

**REFERRING VET**

Dr. Sorbo

**INVOICE**

30589

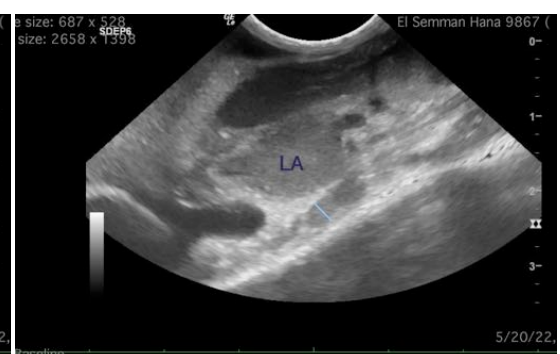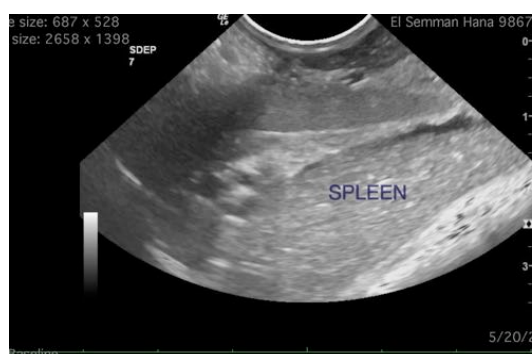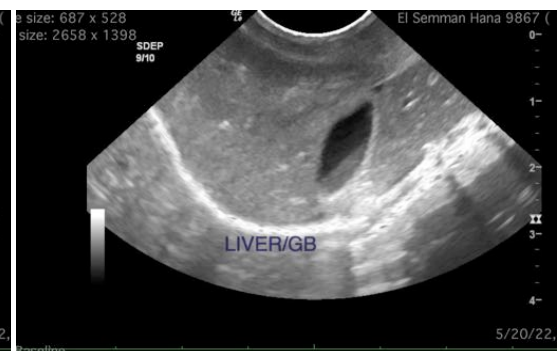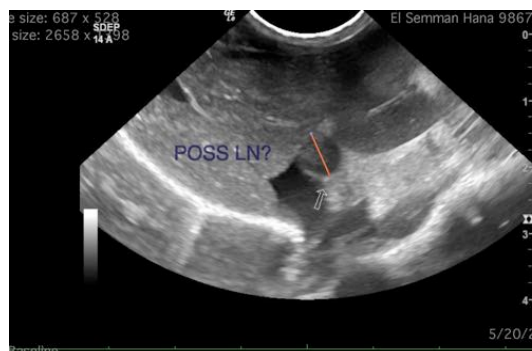**DATE**

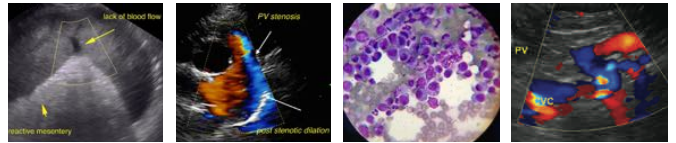
5/20/22

**INTERPRETATION OF THE FINDINGS & FURTHER RECOMMENDATIONS**

There is a moderate amount of free abdominal fluid in the abdomen. No large, focal mass effect is visualized. There is some irregular tissue visualized cranial to the left kidney and a prominent lymph node cranial to the right kidney, but these structures are non-specific and somewhat irregular in shape making determination of the origin difficult.

- Consider fluid sample for fluid analysis and cytology.
- Consider cardiac ultrasound.
- Consider liver function test and urine protein to creatinine ratio to look for a cause of the reported hypoalbuminemia.
- If there is no evidence of renal disease or liver disease and the cytology is not helpful then consider a GI panel for a qualitative fPLI, TLI, cobalamin and folate to look for evidence of protein losing enteropathy.
- Evaluate the stool for evidence of melena as cause for the anemia and hypoalbuminemia.
- Consider three view thoracic radiographs to rule out concurrent thoracic disease/involvement.
- Hopefully with this further evaluation a source for the abdominal fluid is identified. If this is not the case then consider advanced imaging for possible neoplastic lesion.





**PATIENT**

Hana El Semman

**SPECIES**

Feline

**BREED**

Japanese Bobtail

**SEX**

Spayed Female

**AGE**

11 years

**WEIGHT**

4 lbs

**INTERPRETED BY**

Kathleen Sennello  
DVM, MS, Diplomate  
ACVIM (Small Animal  
Internal Medicine)

**IMAGING  
PERFORMED BY**

Dr. Sorbo

**HOSPITAL NAME**

Back Bay VC

**REFERRING VET**

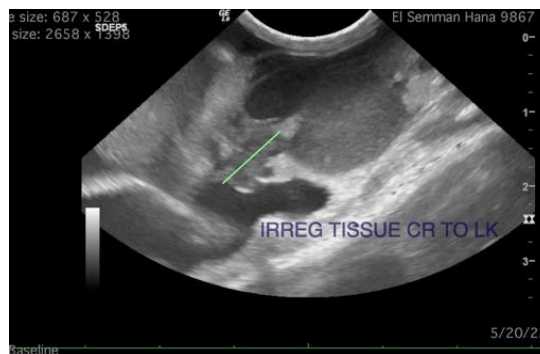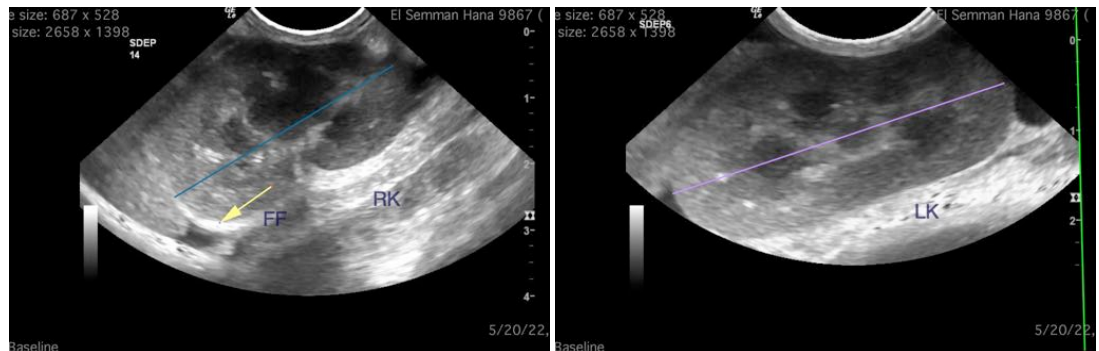
Dr. Sorbo

**INVOICE**

30589

**DATE**

5/20/22



The information and recommendations provided are based on the images presented by the referring veterinarian/sonographer. No evaluation can be communicated regarding pathology that was not visible in the image/video clips provided.

Thank you for this referral. If the clinical or image interpretation does not parallel your findings or if I can be of any further assistance please contact me.

Kathleen Sennello DVM,MS, Diplomate ACVIM (Small animal Internal Medicine)  
kathleen.sennello@sonopath.com