

**DATE PRESENTING CLINICAL SIGNS**

5/2/23 Was not grooming well. Has a history of mild elevation of BUN. High normal Creatinine. Elevated precision PSL.

**PATIENT**

Logan Brulinski

Current Medications: None listed.

Lab Results: See attached.

Date of Previous IntraPet Ultrasound: No previous.

Sedation: Not required to complete full diagnostic ultrasound.

Stat Report: Not requested.

Imaging Performed By: Rachel Brillhart, RDMS.

**SPECIES**

Feline

**BREED**

DSH

**SEX**

Neutered Male

**AGE**

2/9/08

**WEIGHT**

11.6 Pounds

**INTERPRETED BY**

Kathleen Sennello DVM,  
MS, Diplomate ACVIM  
(Small Animal Internal  
Medicine)

**HOSPITAL NAME**

Festival Vet Clinic

**REFERRING VET**

Dr. Cianelli

**INVOICE**

47058

**ULTRASONOGRAPHIC EXAMINATION OF THE ABDOMEN****Urinary System**

The urinary bladder is moderately distended with anechoic urine. The Bladder wall, trigone, ureteral papillae and visible urethra (to a depth of 2cm) appear normal with no evidence of wall thickening, mucosal irregularities, masses or cystic calculi.

The left kidney has a normal shape and size (3.78 cm) with mild pyelectasia at 0.24 cm. Overall echogenicity is normal with mildly reduced corticomedullary distinction and a typical 1:3 cortex:medulla ratio. There is no evidence of focal perinephric inflammation or effusion. There is no evidence of nephroliths, infarcts or hydroureter. Renal vasculature is normal.

The right kidney has a normal shape and size (3.77 cm). Overall echogenicity is normal with mildly reduced corticomedullary distinction and a typical 1:3 cortex:medulla ratio. There is no evidence of focal perinephric inflammation or effusion. There is no evidence of pyelectasia, nephroliths, infarcts or hydroureter. Renal vasculature is normal.

**Adrenal Glands**

The left adrenal gland is normal in size measuring 0.34 cm at the caudal pole. It is observed in its normal position cranial to the left renal artery. It is normal in appearance (uniformly hypoechoic) and shape with no evidence of a mass effect.

The right adrenal gland is normal in size measuring 0.48 cm at the caudal pole. It is observed in its normal position between the cranial aspect of the right kidney and the caudal vena cava. It is normal in appearance (uniformly hypoechoic) and shape with no evidence of a mass effect.

**Spleen**

The spleen is subjectively normal in size (1.0 cm), echotexture is homogenous, and the splenic capsule is smooth with no irregularities. The blood flow through the hilus and splenic parenchyma appears normal. No focal parenchymal abnormalities are visualized.

**Liver**

The liver is subjectively normal in size, and echogenicity with smooth peripheral margins. The parenchyma is homogenous echotexture. The visible portions of the vasculature and biliary tract appear normal. No focal nodules or cystic lesions are observed.

The gallbladder lumen is moderately distended. The wall of the gall bladder is not thickened and has a smooth mucosal surface. Luminal contents are mild and primarily anechoic. The cystic and common bile ducts are normal/not visible.

### ***Gastrointestinal***

The stomach contains minimal luminal contents. It measures at a normal thickness of <0.36cm with some variability due to the presence of rugal folds. The distinction of the gastric wall layers is adequate and there is no impression of reduced peristaltic activity. No masses or focal lesions were observed.

The visualized areas of duodenum, jejunum and ileum have a uniform diameter with minimal fluid distension. Wall thickness is normal to slightly increased. Bowel loops follow a typical curvilinear path with distinct wall layering, but some areas display a prominent muscularis layer which does not display the typical 1:3 muscularis:mucosa layer ratio. Jejunum wall measures 0.29 cm. Visualized peristalsis appears appropriate. There were no focal lesions consistent with obstruction or a mass effect observed.

The ileocecal junction was visualized and exhibited normal intact wall layering and is subjectively of normal thickness. Sections of colon are visualized with formed fecal material and gas shadowing distally. There is no observed focal or generalized colon wall thickening or loss of layering.

### ***Pancreas***

The left limb of the pancreas is prominent and hyperechoic. The right limb of the pancreas is prominent and mottled. Prominent pancreatic duct noted. There is no evidence of nodules or cystic lesions. There is no evidence of regional mesenteric inflammation or fluid.

### ***Free Abdomen***

Evaluation of the peritoneal cavity did not reveal any evidence of effusion, or subjective lymphadenomegaly. The Medial iliac nodes appear normal and there was no evidence of a caudal aortic thrombus at the bifurcation. The omentum is of normal uniform echogenicity.

## **ULTRASONOGRAPHIC FINDINGS**

- Mildly reduced corticomedullary distinction in both kidneys with mild left-sided pyelectasia – Mild loss of corticomedullary distinction in both kidneys could be consistent with chronic degenerative disease or interstitial nephrosis. Pyelectasia of the kidney(s) could be consistent with pyelonephritis, chronic renal disease, secondary to PU/PD or fluid therapy (if applicable), other.
- Prominent, hyperechoic left limb of the pancreas with prominent pancreatic duct and a mildly mottled right limb of the pancreas – Findings are concerning for mild pancreatic inflammation/mild pancreatitis, although resolving pancreatitis is also possible.
- Prominent muscularis layer to the small intestine – The small intestinal wall changes could be consistent with an underlying inflammatory process. These types of changes can sometimes be seen in normal older cats. Correlate with clinical signs.

## **INTERPRETATION OF THE FINDINGS & FURTHER RECOMMENDATIONS**

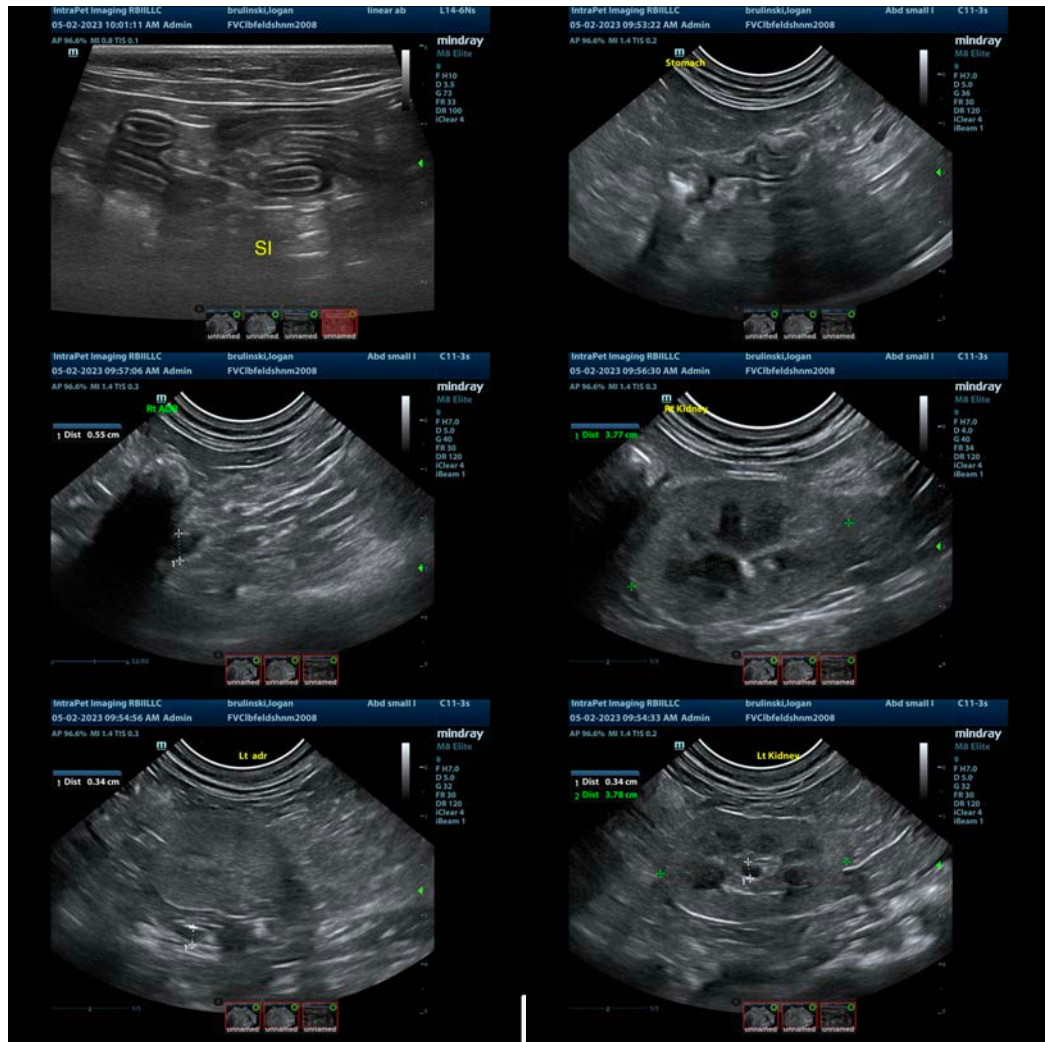
The left limb of the pancreas appears very hyperechoic and prominent. These changes could be consistent with mild active pancreatitis. Recommend empirical treatment for pancreatitis. Additionally, there is the possibility for underlying gastrointestinal disease. The small bowel appears somewhat “ropey” with intact wall layering. Consider a GI panel to Texas A&M for a qualitative fPLI, TLI, cobalamin and folate to further evaluate the pancreas and small intestine. If symptoms persist, you could consider:

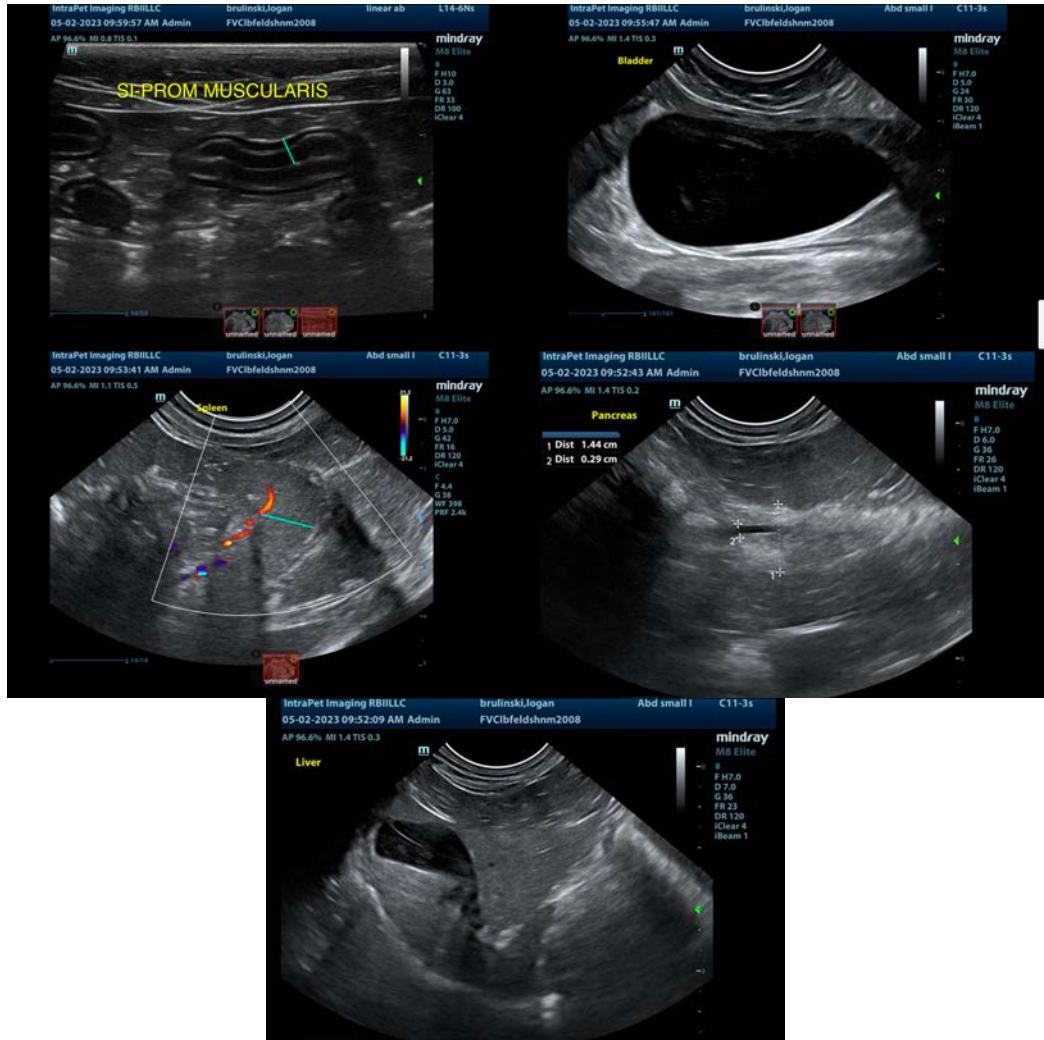
- Consider a novel protein/hydrolyzed protein diet (exclusively at least 4-6 weeks)
- Consider chronic probiotic therapy.
- If symptoms and diagnostics are pointing to primary gastrointestinal disease and symptoms are persisting, you could consider obtaining GI biopsies.

Recommend three view thoracic radiographs to evaluate for possible concurrent thoracic disease/involvement.

The changes observed in the kidneys are mild and could be consistent with early kidney disease. Consider a urinalysis and culture and a baseline blood pressure.

Recommend three view thoracic radiographs to evaluate for possible concurrent thoracic disease/involvement.





The information and recommendations provided are based on the images presented by the referring veterinarian/sonographer. No evaluation can be communicated regarding pathology that was not visible in the image/video clips provided.

Thank you for this referral. If the clinical or image interpretation does not parallel your findings or if I can be of any further assistance please contact me.

Kathleen Sennello DVM,MS, Diplomate ACVIM (Small animal Internal Medicine)  
 kathleen.sennello@sonopath.com