



PATIENT

Klint Jimenez

PRESENTING CLINICAL SIGNS

Elevated kidney values, inappetence
Abnormal PE/Chem/CBC/UA Results: BUN 75, Crea 6.8, Na/K ratio 30, neutrophils 9559

SPECIES

Feline

ULTRASONOGRAPHIC EXAMINATION OF THE ABDOMEN

Urinary System

BREED

DSH

The urinary bladder is moderately distended with anechoic urine. The Bladder wall, trigone, ureteral papillae and visible urethra (to a depth of 2cm) appear normal with no evidence of wall thickening, mucosal irregularities, masses or cystic calculi.

SEX

Neutered Male

The left kidney has a normal shape and size (4.12 cm) with pyelectasia at 0.48 cm and hyperechoic cortices. Small, non-obstructive nephroliths are present. Overall echogenicity is slightly hyperechoic with poor corticomedullary distinction and a typical 1:3 cortex:medulla ratio. There is no evidence of perinephric inflammation or effusion. There is no evidence of infarcts or hydroureter. Renal vasculature is normal. There is an approximately 1.11 cm hypoechoic cyst visualized towards the caudal aspect of the left kidney. This cystic structure appears to have a connection with the renal pelvis and extends somewhat irregularly, with this area having ill-defined borders. These findings could be consistent with an irregular benign cyst, an infected cyst, or less likely a mass effect.

AGE

9 Years

The right kidney has a normal shape and size (5.68 cm) with pyelectasia at 0.82 cm and small non-obstructive nephroliths. Overall echogenicity is slightly hyperechoic with poor corticomedullary distinction and a typical 1:3 cortex:medulla ratio. There is no evidence of perinephric inflammation or effusion. There is no evidence of infarcts or hydroureter. Renal vasculature is normal.

WEIGHT

16.8 Pounds

Adrenal Glands

INTERPRETED BY

Kathleen Sennello DVM,
MS, Diplomate ACVIM
(Small Animal Internal
Medicine)

The left adrenal gland is normal in size measuring 0.36 cm at the caudal pole. It is observed in its normal position cranial to the left renal artery. It is normal in appearance (uniformly hypoechoic) and shape with no evidence of a mass effect.

The right adrenal gland is normal in size measuring 0.44 cm at the caudal pole. It is observed in its normal position between the cranial aspect of the right kidney and the caudal vena cava. It is normal in appearance (uniformly hypoechoic) and shape with no evidence of a mass effect.

IMAGING PERFORMED BY

Jessica Miller

Spleen

The spleen is subjectively normal in size, echotexture is homogenous, and the splenic capsule is smooth with no irregularities. The blood flow through the hilus and splenic parenchyma appears normal. No focal parenchymal abnormalities are visualized.

HOSPITAL NAME

AH of Roxbury

Liver

REFERRING VET

Dr. Elia

The liver is subjectively normal in size, and echogenicity with smooth peripheral margins. The parenchyma is homogenous echotexture. The visible portions of the vasculature and biliary tract appear normal. No focal nodules or cystic lesions are observed.

INVOICE

37745

The gallbladder lumen is moderately distended. The wall of the gall bladder is not thickened and has a smooth mucosal surface. Luminal contents are primarily anechoic. The cystic and common bile ducts are normal/not visible.

DATE

5/18/22



PATIENT

Gastrointestinal

Klint Jimenez

The stomach contains minimal luminal contents. It measures at a normal thickness of <0.36cm with some variability due to the presence of rugal folds. The distinction of the gastric wall layers is adequate and there is no impression of reduced peristaltic activity. No masses or focal lesions were observed.

SPECIES

Feline

The visualized areas of duodenum, jejunum and ileum have a relatively uniform diameter with minimal fluid distension. Wall thickness is normal. Bowel loops follow a curvilinear path with distinct wall layering maintaining the typical 1:3 muscularis:mucosa layer ratio. The duodenum measured as normal (between 0.13-0.38cm in wall thickness) and the jejunum measured as normal (between 0.15-0.36cm.) Visualized peristalsis appears appropriate. There were no focal lesions consistent with obstruction or a mass effect observed.

BREED

DSH

SEX

Neutered Male

The ileocecal junction was visualized and exhibited normal intact wall layering and is subjectively of normal thickness. Sections of colon are visualized with formed fecal material and gas shadowing distally. There is no observed focal or generalized colon wall thickening or loss of layering.

AGE

9 Years

Pancreas

The pancreas is prominent and hypoechoic as compared to the surrounding isoechoic mesentery. There is no evidence of nodules or cystic lesions. There is no evidence of regional mesenteric inflammation or fluid. Prominent pancreatic duct noted at 0.31 cm.

WEIGHT

16.8 Pounds

Free Abdomen

Evaluation of the peritoneal cavity did not reveal any evidence of effusion, or subjective lymphadenomegaly. The Medial iliac nodes appear normal and there was no evidence of a caudal aortic thrombus at the bifurcation. The omentum is of normal uniform echogenicity.

INTERPRETED BY

Kathleen Sennello DVM,
MS, Diplomate ACVIM
(Small Animal Internal
Medicine)

ULTRASONOGRAPHIC FINDINGS

- Decreased corticomedullary distinction in both kidneys with bilateral pyelectasia and small nephroliths – Mild loss of corticomedullary distinction in both kidneys could be consistent with chronic degenerative disease or interstitial nephrosis. Both kidneys have pyelectasia and small nephroliths. None of these stones appear to obviously be causing an obstruction, but partial obstructions are possible and can be transient with movement. Additionally, there is some irregularity with cystic structure visualized in the left kidney.
- Hypoechoic, prominent pancreas – The pancreatic changes are most consistent with age-related parenchymal remodeling, potentially secondary to a prior inflammatory episode, early fibrosis or chronic pancreatitis.

IMAGING PERFORMED BY

Jessica Miller

HOSPITAL NAME

AH of Roxbury

REFERRING VET

Dr. Elia

INTERPRETATION OF THE FINDINGS & FURTHER RECOMMENDATIONS

There is bilateral pyelectasia, nephroliths, and irregular cystic structure visualized in the left kidney. It is likely that some of the changes observed are chronic and progressive changes, but if there has been a recent rise in the renal values, there could be infection and/or partial obstruction present.

INVOICE

37745

DATE

5/18/22

- Recommend urinalysis and culture.
- Recommend radiographs to see if any of the observed mineralizations are large enough to be visualized and additionally to look for evidence of ureteral stones.
- Recommend continued monitoring of both kidneys for progressive dilation and changes



PATIENT

Klint Jimenez

associated with the cystic structure in the left kidney.

SPECIES

Feline

- Recommend blood pressure evaluation.
- Recommend diuresis, pain medications, and antibiotics while waiting for culture results.
- If renal pelvic dilation progresses, or the cystic structure in the left kidney is changing, consider a contrast CT scan to allow for better detail and following of urine flow through the ureters.

BREED

DSH

SEX

Neutered Male

AGE

9 Years

WEIGHT

16.8 Pounds

INTERPRETED BY

Kathleen Sennello DVM, MS, Diplomate ACVIM (Small Animal Internal Medicine)

IMAGING PERFORMED BY

Jessica Miller

HOSPITAL NAME

AH of Roxbury

REFERRING VET

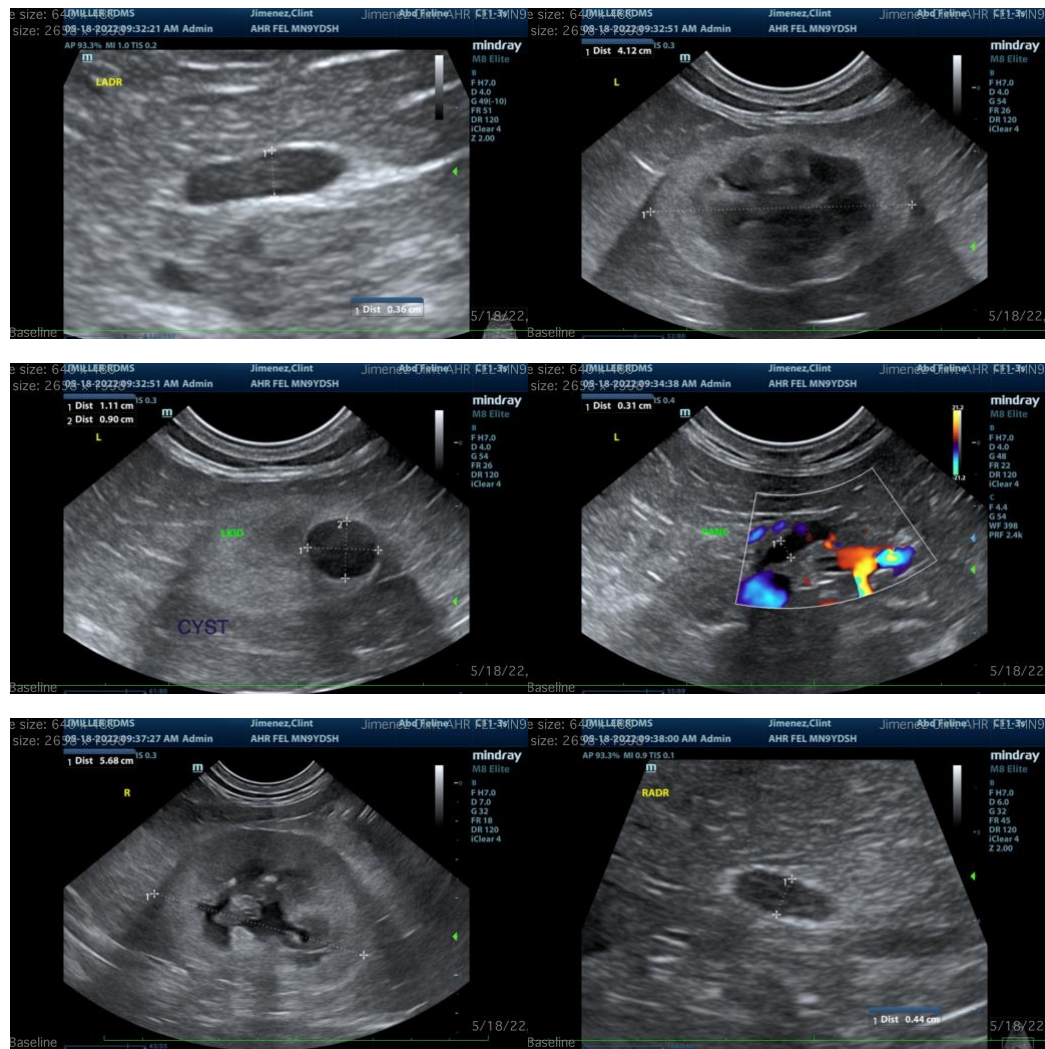
Dr. Elia

INVOICE

37745

DATE

5/18/22





PATIENT

Klint Jimenez

SPECIES

Feline

BREED

DSH

SEX

Neutered Male

AGE

9 Years

WEIGHT

16.8 Pounds

INTERPRETED BY

Kathleen Sennello DVM,
MS, Diplomate ACVIM
(Small Animal Internal
Medicine)

**IMAGING
PERFORMED BY**

Jessica Miller

HOSPITAL NAME

AH of Roxbury

REFERRING VET

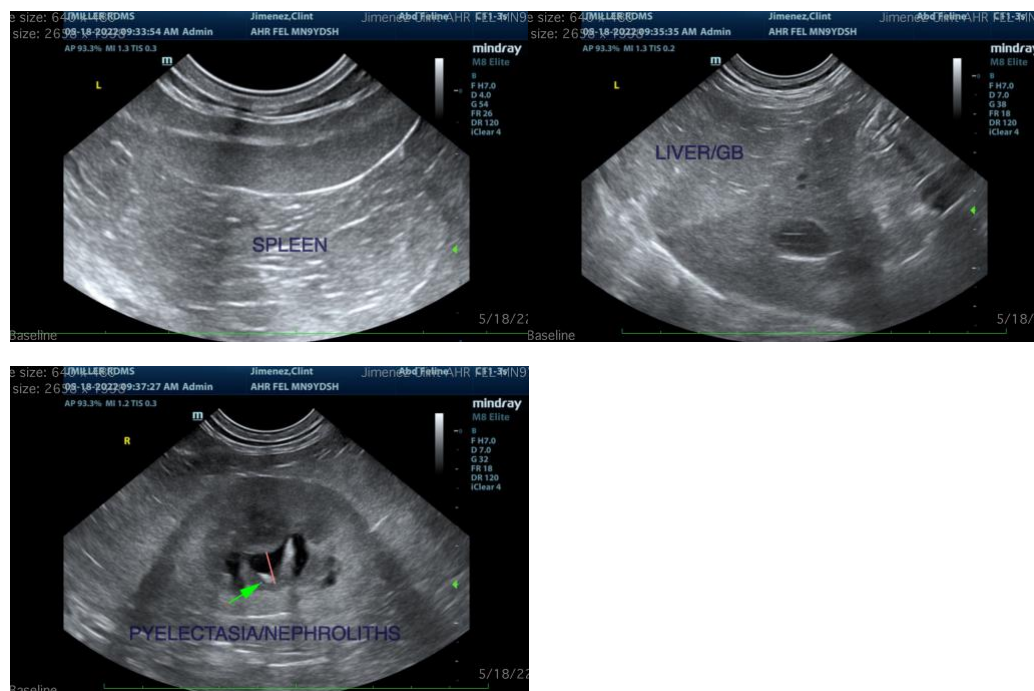
Dr. Elia

INVOICE

37745

DATE

5/18/22



The information and recommendations provided are based on the images presented by the referring veterinarian/sonographer. No evaluation can be communicated regarding pathology that was not visible in the image/video clips provided.

Thank you for this referral. If the clinical or image interpretation does not parallel your findings or if I can be of any further assistance please contact me.

Kathleen Sennello DVM,MS, Diplomate ACVIM (Small animal Internal Medicine)

kathleen.sennello@sonopath.com