



PATIENT

Peaches Maliniak

PRESENTING CLINICAL SIGNS

SPECIES

Canine

Bile Acids (02/11/2022): Pre- High (64) Post- Normal (20.1) A: Potentially some liver dysfunction, however post is normal showing liver can still function normally. P: Recommend continue on renal and liver protectants as directed. Recheck CBC/Chem/UA in 3-4 months and recheck abdominal ultrasound with in 3-4 months, sooner if not doing well, consider hepatic/renal FNA/Cytology vs. Bx/histopathology (would need pre-procedure coagulation panel) at same time if indicated.

BREED

Chihuahua

Abnormal PE/Chem/CBC/UA Results: Lab Results (01/10/2022): CBC- HCT High (57.7), Platelets High (481), All Else WNL. Chemistry Panel- ALT High (163), ALP High (164), All Else WNL. Hemolysis 3+ (In absence of anemia likely due to collection method) Lipemia 1+ (R/O Post prandial vs. Pathologic) Total T4- (2.5). A: Mildly elevated ALP and ALT, lower than historically have been- R/O Hepatopathy, Cholestasis, Neoplasia, Other. Thyroid level great.

SEX

Spayed Female

ULTRASONOGRAPHIC EXAMINATION OF THE ABDOMEN

AGE

14 Years

Urinary System

The urinary bladder is moderately distended with anechoic urine. The Bladder wall, trigone, ureteral papillae and visible urethra (to a depth of 2cm) appear normal with no evidence of wall thickening, mucosal irregularities, masses or cystic calculi.

WEIGHT

10 Pounds

The left kidney has a normal shape and size (3.65 cm) with numerous cortical cysts. Overall echogenicity is slightly hyperechoic with poor corticomedullary distinction and a typical 1:3 cortex:medulla ratio. There is no evidence of perinephric inflammation or effusion. There is no evidence of pyelectasia, nephroliths, infarcts or hydroureter. Renal vasculature is normal.

INTERPRETED BY

Kathleen Sennello DVM,
MS, Diplomate ACVIM
(Small Animal Internal
Medicine)

The right kidney has a normal shape and size (3.99 cm). Overall echogenicity is normal with adequate corticomedullary distinction and a typical 1:3 cortex:medulla ratio. There is no evidence of perinephric inflammation or effusion. There is no evidence of pyelectasia, nephroliths, infarcts or hydroureter. Renal vasculature is normal.

Adrenal Glands

The left adrenal gland is large in size measuring 1.0 cm at the cranial pole, 0.81 cm at the caudal pole, and 2.09 cm in length. It is observed in its normal position cranial to the left renal artery. It is somewhat abnormal in appearance in that there are ill-defined, hyperechoic nodules/mottling, which do not appear to deviate the margins of the adrenal gland. There is no obvious evidence of vascular invasion.

IMAGING BY

Loetitia Saint-Jacques,
LVT

HOSPITAL NAME

Monte Vista AH

The right adrenal gland is normal in size measuring 0.56 cm at the caudal pole. It is observed in its normal position between the cranial aspect of the right kidney and the caudal vena cava. It is somewhat abnormal in appearance in that the parenchyma is heterogeneous and mottled with hyperechoic focal areas similar to that seen in the left adrenal.

REFERRING VET

Dr. Alexandra Moore

Spleen

The spleen is subjectively normal in size, echotexture is homogenous, and the splenic capsule is smooth with no irregularities. The blood flow through the hilus and splenic parenchyma appears normal. No focal parenchymal abnormalities are visualized.

INVOICE

37723

DATE

5/17/22



Portable Animal Welfare Sonography, Inc.

IMAGING PERFORMED BY
pawsonography@gmail.com 530-786-8340

PATIENT

Peaches Maliniak

SPECIES

Liver

The liver is large in size and hyperechoic. The parenchyma is heterogenous in echotexture with subtle, indistinct focal mottling. The visible portions of the vasculature and biliary tract appear normal. No focal nodules or cystic lesions are observed.

Canine

BREED

The gall bladder lumen is moderately distended. The wall of the gall bladder is not thickened and has a smooth mucosal surface. There is a moderate hyperechoic shadowing debris, most consistent with sandy debris or stones. The cystic and common bile ducts are normal/not visible.

Chihuahua

SEX

Gastrointestinal

The stomach contains minimal luminal contents. It measures at a normal thickness of <0.7cm with some variability due to the presence of rugal folds. The distinction of the gastric wall layers is adequate and there is no impression of reduced peristaltic activity. No masses or focal lesions were observed.

Spayed Female

AGE

The visualized areas of duodenum, jejunum and ileum have a relatively uniform diameter with minimal fluid distension. Wall thickness is normal. Bowel loops follow a curvilinear path with distinct wall layering maintaining the typical 1:3 muscularis:mucosa layer ratio. The duodenum measured as normal (between 0.3-0.5cm in wall thickness) and the jejunum measured as normal (between 0.2-0.47cm.) Visualized peristalsis appears appropriate. There were no focal lesions consistent with obstruction or a mass effect observed.

14 Years

WEIGHT

The ileocecal junction was visualized and exhibited normal intact wall layering and is subjectively of normal thickness. Sections of colon are visualized with formed fecal material and gas shadowing distally. There is no observed focal or generalized colon wall thickening or loss of layering.

10 Pounds

INTERPRETED BY

Pancreas

The pancreas is normal and isoechoic to surrounding mesentery. There is no evidence of nodules or cystic lesions. There is no evidence of regional mesenteric inflammation or fluid.

Kathleen Sennello DVM,
MS, Diplomate ACVIM
(Small Animal Internal
Medicine)

IMAGING BY

Free Abdomen

Evaluation of the peritoneal cavity did not reveal any evidence of effusion, or subjective lymphadenomegaly. The Medial iliac nodes appear normal and there was no evidence of a caudal aortic thrombus at the bifurcation. The omentum is of normal uniform echogenicity.

Loetitia Saint-Jacques,
LVT

Other

A brief view of the heart was submitted. No significant pericardial effusion was seen.

HOSPITAL NAME

Monte Vista AH

PRIMARY FINDINGS

REFERRING VET

- Borderline bilateral adrenomegaly with ill-defined hyperechoic mottling/foci in both adrenals – The bilateral adrenomegaly could be consistent with bilateral hyperplasia (e.g., secondary to pituitary-dependent hyperadrenocorticism), bilateral infiltrative neoplasia, inflammatory adrenal disease, other. Correlation with clinical findings is recommended. Other less likely differentials would include metastatic disease, bilateral neoplasia, etc.

Dr. Alexandra Moore

INVOICE

37723

- Large, hyperechoic, heterogeneous liver – The diffuse hepatic changes are non-specific

DATE

5/17/22



Portable Animal Visceral Sonography, Inc.

IMAGING PERFORMED BY
pawsonography@gmail.com 530-786-8340

PATIENT

Peaches Maliniak

and could be consistent with vacuolar hepatopathy, nodular hyperplasia, inflammatory/immune-mediated disease, fibrosis, extramedullary hematopoiesis, toxic hepatopathy (e.g., copper), infiltrative neoplasia (less likely) or other hepatopathy.

SPECIES

Canine

- Moderate shadowing hyperechoic gallbladder debris – most consistent with sandy debris/small gallbladder stones. No obstruction is observed.

BREED

Chihuahua

SECONDARY FINDINGS

- Decreased corticomedullary distinction in both kidneys with cortical cysts – The bilateral renal findings are consistent with age-related change.

SEX

Spayed Female

INTERPRETATION OF THE FINDINGS & FURTHER RECOMMENDATIONS

No focal lesions are observed in the liver, but it does appear large and somewhat heterogeneous and hyperechoic. Given the abnormal bile acids testing, I would consider fine needle aspirate of the liver (provided coagulation parameters are ok) and continued monitoring, in addition to treatment with Ursodiol and Denamarin. If liver function remains abnormal, and cytology is not diagnostic, then a liver biopsy may need to be considered.

AGE

14 Years

Consider three view thoracic radiographs to rule out concurrent thoracic disease/involvement.

WEIGHT

10 Pounds

Both adrenal glands are somewhat mottled and irregular in appearance. The left adrenal gland is borderline enlarged. The significance of these findings is somewhat unclear. If signs of Cushing's are present, consider arenal function testing. Recommend blood pressure evaluation. Consider continued monitoring with ultrasound to determine if these lesions are progressing or if this could represent an early mass effect.

INTERPRETED BY

Kathleen Sennello DVM,
MS, Diplomate ACVIM
(Small Animal Internal
Medicine)

IMAGING BY

Loetitia Saint-Jacques,
LVT

HOSPITAL NAME

Monte Vista AH

REFERRING VET

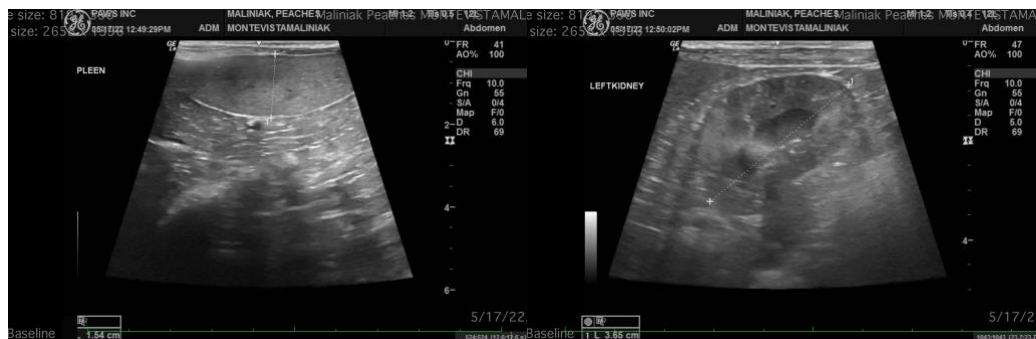Dr. Alexandra Moore

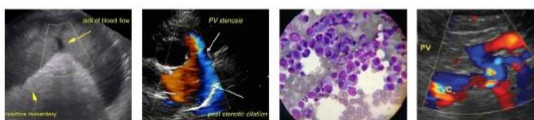
INVOICE

37723

DATE

5/17/22





Portable Animal Vets Sonography, Inc.

IMAGING PERFORMED BY
pawsonography@gmail.com 530-786-8340

PATIENT

Peaches Maliniak

SPECIES

Canine

BREED

Chihuahua

SEX

Spayed Female

AGE

14 Years

WEIGHT

10 Pounds

INTERPRETED BY

Kathleen Sennello DVM,
MS, Diplomate ACVIM
(Small Animal Internal
Medicine)

IMAGING BY

Loetitia Saint-Jacques,
LVT

HOSPITAL NAME

Monte Vista AH

REFERRING VET

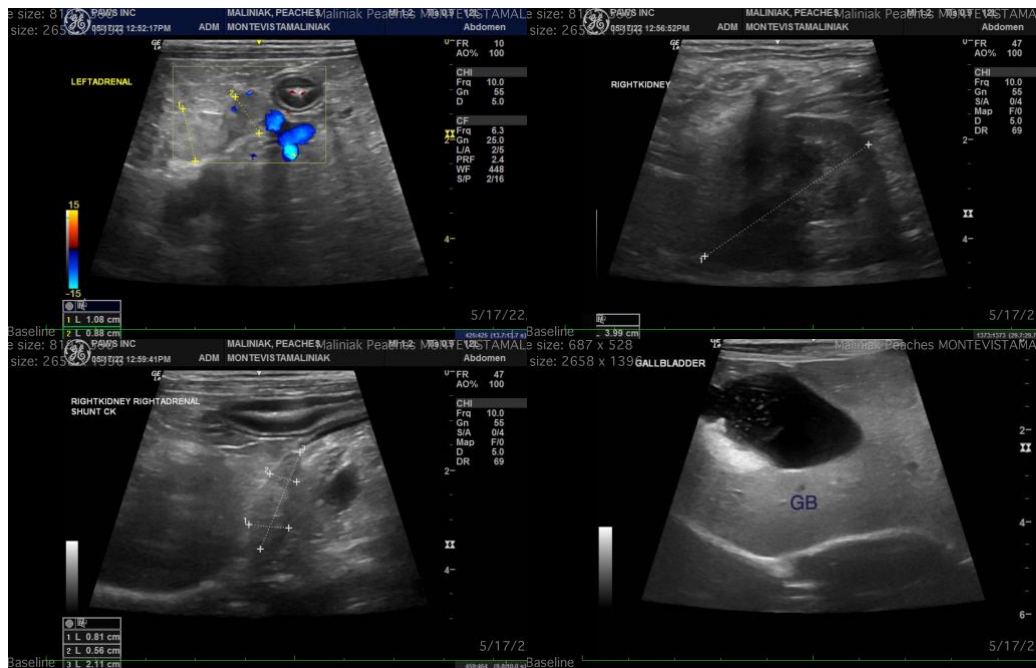
Dr. Alexandra Moore

INVOICE

37723

DATE

5/17/22



The information and recommendations provided are based on the images presented by the referring veterinarian/sonographer. No evaluation can be communicated regarding pathology that was not visible in the image/video clips provided.

Thank you for this referral. If the clinical or image interpretation does not parallel your findings or if I can be of any further assistance please contact me.

Kathleen Sennello DVM,MS, Diplomate ACVIM (Small animal Internal Medicine)
kathleen.sennello@sonopath.com