SonoPath
Clinical Sonography & Telecytology
EDUCATIONAL TELECONSULTATION SERVICES™
1-800-838-4268 info@sonopath.com SonoPath.com

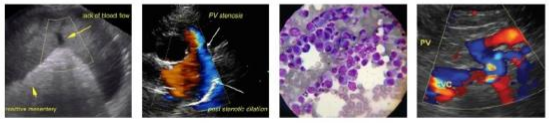

IMAGING PERFORMED BY
pawsonography@gmail.com 530-786-8340

PATIENT

Dahlia Gibbon

SPECIES

Canine

BREED

Pomeranian

SEX

Spayed Female

AGE

11 Years

WEIGHT

9.3 Pounds

INTERPRETED BY

Kathleen Sennello DVM, MS, Diplomate ACVIM (Small Animal Internal Medicine)

IMAGING BY

Loetitia Saint-Jacques, LVT

HOSPITAL NAME

Monte Vista AH

REFERRING VET

Dr. Alexandra Moore

INVOICE

37725

DATE

5/17/22

PRESENTING CLINICAL SIGNS

Addendum lab results (04/04/2022): UP:C Ratio High (2.4). UA- Cystocentesis, USG 1.049, pH 5.5, 3+ Protein, Blood 1+, WBC 2-5, RBC 15-20, 3+ Calcium Oxalate dihydrate (21-50)/HPF, All Else WNL. Urine C/S/MIC: Isolate: Enterococcus faecalis- 1,000-10,000 CFU per ml. Sensitive to Clavamox and Enrofloxacin. A: Hematuria, Calcium Oxalate Urolithiasis, Urine Hypersthenuric, Proteinuria- R/O True vs. Active Sediment- UTI, R/O Urolithiasis. P: Recommend starting on 10 days of Clavamox, recheck urine c/s/mic 5 days post-Tx. Recommend abdominal imaging (radiographs and ultrasound). Continue with current plan as directed (see below). AM Lab Results (03/30/2022): CBC- Platelets High (622), All Else WNL. Chemistry Panel- All WNL. Hemolysis 2+, In absence of anemia likely due to collection artifact. Lipemia 2+ Total T4- Normal (2.2). BP Readings: 191/121 (144) Average of 4 readings. A: Being treated for presumed Lyme Nephritis. Hypertension. No evidence of hypoalbuminemia or Azotemia at this time. Thrombocytosis- R/O Primary vs. Secondary. UA/UP:C/Urine c/s/mic results are pending. P: Recommend abdominal ultrasound to assess urinary tract, can repeat echo at same time. Continue on renal protectants and renal diet as directed. Continue on 28 day course of Doxycycline (longer pending C6 response-1 to 3 months). Continue on Nexgard and Pimobendan as directed. Continue on Benazepril at 0.5 mg/kg, PO q 24 h (can increase to total 2 mg/kg/day if needed in 0.5 mg increments). If no response to Benazepril can switch to Telmisartan at 1 mg/kg SID (Monitor for hyperkalemia). Add on Amlodipine 0.2 mg/kg, PO, q 24 h for hypertension (>160-180 mmHg). Recheck BP 3-5 days after starting Amlodipine. *Start on Clopidogrel at 1.1 mg/kg, PO, q 24 h if hypoalbuminemia develops, can taper off if proteinuria/values return to normal quickly. *Add on mycophenolate if GN confirmed by histopathology results or not responding to Tx or rapidly progressing Azotemia. Recheck CBC/Chem/UA/BP/UP:C at 30 days. Then once stable CBC/Chem/UA/BP/UP:C/PE and body weight q 3-4 months. Recheck Lyme Quant C6 at 3 and 6 months post-Tx. Ensure that Dahlia is off all NSAIDs. Monitor for signs of hypotension. If not tolerating dose of Benazepril can decrease to 0.25 mg/kg/day.
Abnormal PE/Chem/CBC/UA Results: - AUS to look at kidneys- had an echo with sonopath in 2020

ULTRASONOGRAPHIC EXAMINATION OF THE ABDOMEN

Urinary System

The urinary bladder is moderately distended with anechoic urine. The Bladder wall, trigone, ureteral papillae and visible urethra (to a depth of 2cm) appear normal with no evidence of wall thickening, mucosal irregularities, masses or cystic calculi.

The left kidney has a normal shape and size (3.89 cm). Overall echogenicity is slightly hyperechoic with poor corticomedullary distinction and a typical 1:3 cortex:medulla ratio. There is no evidence of perinephric inflammation or effusion. There is no evidence of pyelectasia, nephroliths, infarcts or hydroureter. Renal vasculature is normal.

The right kidney has a normal shape and size (3.99 cm). Overall echogenicity is slightly hyperechoic with poor corticomedullary distinction and a typical 1:3 cortex:medulla ratio. There is no evidence of perinephric inflammation or effusion. There is no evidence of pyelectasia, nephroliths, infarcts or hydroureter. Renal vasculature is normal.

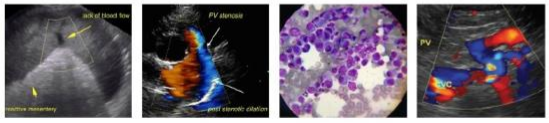

PATIENT

Dahlia Gibbon

SPECIES

Canine

BREED

Pomeranian

SEX

Spayed Female

AGE

11 Years

WEIGHT

9.3 Pounds

INTERPRETED BY

Kathleen Sennello DVM, MS, Diplomate ACVIM (Small Animal Internal Medicine)

IMAGING BY

Loetitia Saint-Jacques, LVT

HOSPITAL NAME

Monte Vista AH

REFERRING VET

Dr. Alexandra Moore

INVOICE

37725

DATE

5/17/22

Adrenal Glands

The left adrenal gland is large in size measuring 0.57 cm at the cranial pole, 0.92 cm at the caudal pole, and 1.7 cm in lenth. It is observed in its normal position cranial to the left renal artery. It is somewhat abnormal in appearance in that the caudal pole is enlarged and rounded, most consistent with a focal caudal adrenal nodule. There is no obvious evidence of vascular invasion.

The right adrenal gland is normal in size measuring 0.35 cm at the caudal pole. It is observed in its normal position between the cranial aspect of the right kidney and the caudal vena cava. It is normal in appearance (uniformly hypoechoic) and shape with no evidence of a mass effect.

Spleen

The spleen is subjectively normal in size, echotexture is homogenous, and the splenic capsule is smooth with no irregularities. The blood flow through the hilus and splenic parenchyma appears normal. No focal parenchymal abnormalities are visualized.

Liver

The liver is large in size, and normal in echogenicity with smooth peripheral margins. The parenchyma is heterogenous in echotexture with subtle, indistinct focal mottling. The visible portions of the vasculature and biliary tract appear normal. No focal nodules or cystic lesions are observed.

The gallbladder lumen is moderately distended. The wall of the gall bladder is not thickened and has a smooth mucosal surface. Luminal contents are primarily anechoic. The cystic and common bile ducts are normal/not visible.

Gastrointestinal

The stomach contains minimal luminal contents. It measures at a normal thickness of <0.7cm with some variability due to the presence of rugal folds. The distinction of the gastric wall layers is adequate and there is no impression of reduced peristaltic activity. No masses or focal lesions were observed.

The visualized areas of duodenum, jejunum and ileum have a relatively uniform diameter with minimal fluid distension. Wall thickness is normal. Bowel loops follow a curvilinear path with distinct wall layering maintaining the typical 1:3 muscularis:mucosa layer ratio. The duodenum measured as normal (between 0.3-0.5cm in wall thickness) and the jejunum measured as normal (between 0.2-0.47cm.) Visualized peristalsis appears appropriate. There were no focal lesions consistent with obstruction or a mass effect observed.

The ileocecal junction was visualized and exhibited normal intact wall layering and is subjectively of normal thickness. Sections of colon are visualized with formed fecal material and gas shadowing distally. There is no observed focal or generalized colon wall thickening or loss of layering.

Pancreas

The pancreas is normal and isoechoic to surrounding mesentery. There is no evidence of nodules or cystic lesions. There is no evidence of regional mesenteric inflammation or fluid.

Free Abdomen

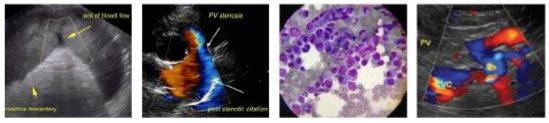

PATIENT

Dahlia Gibbon

SPECIES

Canine

BREED

Pomeranian

SEX

Spayed Female

AGE

11 Years

WEIGHT

9.3 Pounds

INTERPRETED BY

Kathleen Sennello DVM, MS, Diplomate ACVIM (Small Animal Internal Medicine)

IMAGING BY

Loetitia Saint-Jacques, LVT

HOSPITAL NAME

Monte Vista AH

REFERRING VET

Dr. Alexandra Moore

INVOICE

37725

DATE

5/17/22

Evaluation of the peritoneal cavity did not reveal any evidence of effusion, or subjective lymphadenomegaly. The Medial iliac nodes appear normal and there was no evidence of a caudal aortic thrombus at the bifurcation. The omentum is of normal uniform echogenicity.

ULTRASONOGRAPHIC FINDINGS

- Enlarged caudal pole of the left adrenal gland – findings are concerning for a possible left adrenal nodule.
- Decreased corticomedullary distinction in both kidneys – Mild loss of corticomedullary distinction in both kidneys could be consistent with chronic degenerative disease or interstitial nephrosis.
- Large, heterogeneous liver – The diffuse hepatic changes are non-specific and could be consistent with vacuolar hepatopathy, nodular hyperplasia, inflammatory/immune-mediated disease, fibrosis, extramedullary hematopoiesis, toxic hepatopathy (e.g., copper), infiltrative neoplasia (less likely) or other hepatopathy.

INTERPRETATION OF THE FINDINGS & FURTHER RECOMMENDATIONS

There is an enlarged caudal pole of the left adrenal gland. This appears relatively smooth and regular in shape and doesn't appear to be deforming the adrenal gland significantly. These nodules can be benign or malignant and can secrete hormones or be non-active. Options moving forward include:

- If signs of cushings are present, consider adrenal function testing. I prefer an ACTH stimulation test combined with an adrenal panel to the University of Tennessee's endocrine lab to look for atypical adrenal hormones as well as cortisol. (other testing can suffice)
- If adrenal dependent cushings is suspected and supported by adrenal function testing consider medical therapy with lysodren or trilostane or consider surgical removal (recommend referral to a board certified veterinary surgeon and possible pre op CT)
- Recommend blood pressure evaluation-if hypertensive consider testing catecholamine levels for a possible pheochromocytoma
- If no symptoms of cushings are present, consider either referral for surgery or continued monitoring with ultrasound (in 3-4 months).
- Many of these nodules can be benign and incidental in nature, unfortunately that is difficult to determine with a single ultrasound.

Consider three view thoracic radiographs to rule out concurrent thoracic disease/involvement.

The changes associated with the liver could be consistent with a steroid hepatopathy secondary to the adrenal nodule.

SonoPath
Clinical Sonography & Telecytology
EDUCATIONAL TELECONSULTATION SERVICES™
1-800-838-4268 info@sonopath.com SonoPath.com

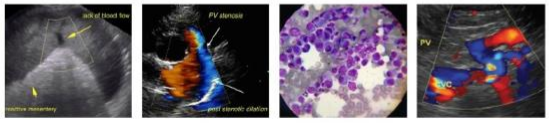

IMAGING PERFORMED BY
pawsonography@gmail.com 530-786-8340

PATIENT

Dahlia Gibbon

SPECIES

Canine

BREED

Pomeranian

SEX

Spayed Female

AGE

11 Years

WEIGHT

9.3 Pounds

INTERPRETED BY

Kathleen Sennello DVM, MS, Diplomate ACVIM (Small Animal Internal Medicine)

IMAGING BY

Loetitia Saint-Jacques, LVT

HOSPITAL NAME

Monte Vista AH

REFERRING VET

Dr. Alexandra Moore

INVOICE

37725

DATE

5/17/22

The changes observed in the kidneys are consistent with chronic progressive age related disease. Recommend continued monitoring/treatment for hypertension, screening and treatment for urinary tract infections, etc.

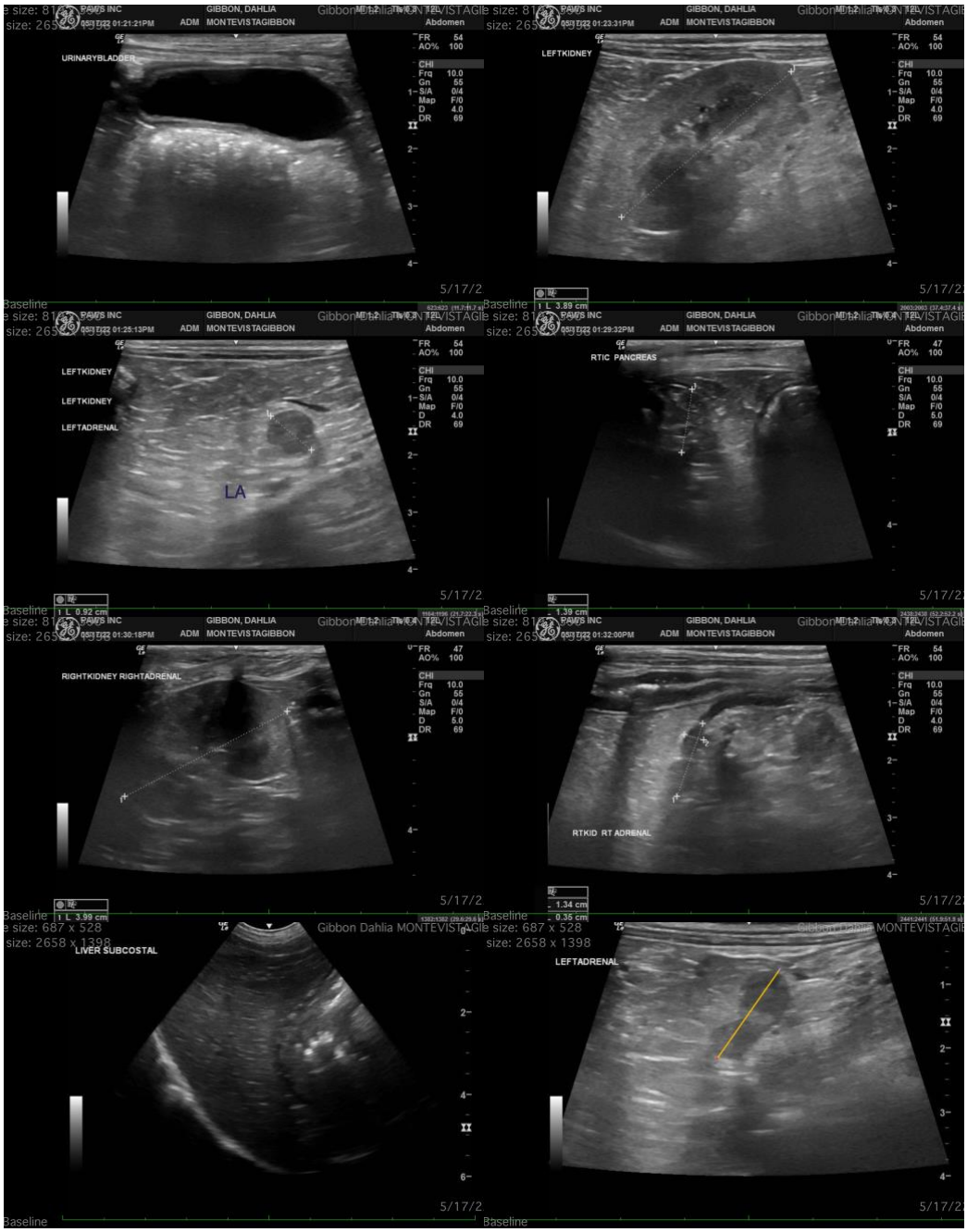

SonoPath
Clinical Sonography & Telecytology
EDUCATIONAL TELECONSULTATION SERVICES™
1-800-838-4268 info@sonopath.com SonoPath.com

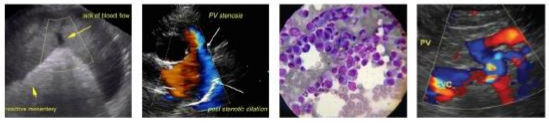

IMAGING PERFORMED BY
pawsonography@gmail.com 530-786-8340

PATIENT

Dahlia Gibbon

SPECIES

Canine

BREED

Pomeranian

SEX

Spayed Female

AGE

11 Years

WEIGHT

9.3 Pounds

INTERPRETED BY

Kathleen Sennello DVM, MS, Diplomate ACVIM (Small Animal Internal Medicine)

IMAGING BY

Loetitia Saint-Jacques, LVT

HOSPITAL NAME

Monte Vista AH

REFERRING VET

Dr. Alexandra Moore

INVOICE

37725

DATE

5/17/22

The information and recommendations provided are based on the images presented by the referring veterinarian/sonographer. No evaluation can be communicated regarding pathology that was not visible in the image/video clips provided.

Thank you for this referral. If the clinical or image interpretation does not parallel your findings or if I can be of any further assistance please contact me.

Kathleen Sennello DVM,MS, Diplomate ACVIM (Small animal Internal Medicine)
kathleen.sennello@sonopath.com