

**DATE PRESENTING CLINICAL SIGNS**

5/17/22 Pet presenting with vomiting to the ER on May 13. Bloodwork revealed elevations of liver values higher than last testing at our clinic in 2019.

PATIENT PE normal except has diarrhea. Rads: (read at ER) essentially normal no obvious foreign body.

Bentley Sanikop Current Medications: Fortiflora One packet Daily, Omeprazole One 10mg Capsule BID, denamarin 120mg sid, Cerenia inj x 1

SPECIES Lab Results: May 13, 2022 Results: ALB= 4.1 g/dL (2.2-3.9), ALT= 166 U/L (10-125), ALKP= 812 U/L (23-212), K= 3.3mmol/L (3.5-5.8). Other chem normal. No other labs done. January 15, 2019: ALB= 3.5, ALT= 66, ALKP= 185 (18-214). USG 1.041, 1+ struvite crystals. Other chem and microscopic normal.

Canine Date of Previous IntraPet Ultrasound: No previous.

BREED Sedation: Full sedation.
Stat Report: Not requested.

Fox Terrier X

ULTRASONOGRAPHIC EXAMINATION OF THE ABDOMEN**SEX**

Neutered Male

Urinary System

The urinary bladder is moderately distended with anechoic urine. The Bladder wall, trigone, ureteral papillae and visible urethra (to a depth of 2cm) appear normal with no evidence of wall thickening, mucosal irregularities, masses or cystic calculi.

AGE

9/6/11

The prostate is normal in size (0.86 cm) and shape for this neutered male dog. The parenchyma is homogenous and the external margins are smooth. The prostatic urethra appears normal with no evidence of irregularity, invasion, mass effect or calculi.

WEIGHT

26.6 Pounds

The left kidney has a normal shape and size (5.0 cm). Overall echogenicity is normal with adequate corticomedullary distinction and a typical 1:3 cortex:medulla ratio. There is no evidence of perinephric inflammation or effusion. There is no evidence of pyelectasia, nephroliths, infarcts or hydroureter. Renal vasculature is normal.

INTERPRETED BY

Kathleen Sennello DVM,
MS, Diplomate ACVIM
(Small Animal Internal
Medicine)

The right kidney has a normal shape and size (4.41 cm). Overall echogenicity is normal with adequate corticomedullary distinction and a typical 1:3 cortex:medulla ratio. There is no evidence of perinephric inflammation or effusion. There is no evidence of pyelectasia, nephroliths, infarcts or hydroureter. Renal vasculature is normal.

IMAGING PERFORMED BY

Rachel Brillhart RDMS

Adrenal Glands

The left adrenal gland is normal in size measuring 0.60 cm at the caudal pole. It is observed in its normal position cranial to the left renal artery. It is normal in appearance (uniformly hypoechoic) and shape with no evidence of a mass effect.

HOSPITAL NAME

Friendly Paws VC

The right adrenal gland is normal in size measuring 0.53 cm at the caudal pole. It is observed in its normal position between the cranial aspect of the right kidney and the caudal vena cava. It is normal in appearance (uniformly hypoechoic) and shape with no evidence of a mass effect.

REFERRING VET

Dr. Price

Spleen

The spleen is subjectively normal in size, echotexture is homogenous, and the splenic capsule is smooth with no irregularities. The blood flow through the hilus and splenic parenchyma appears normal. There is a small indistinct hypoechoic lesion most consistent with a small nodule, measuring 1.01 cm in the parenchyma.

INVOICE

37683

Liver

The liver is subjectively normal in size, and echogenicity with smooth peripheral margins. The parenchyma is heterogenous in echotexture with subtle, indistinct focal mottling. The visible portions of the vasculature and biliary tract appear normal. No focal nodules or cystic lesions are observed.

The gall bladder lumen is moderately distended. The wall of the gall bladder is not thickened and has a smooth mucosal surface. There is a mild amount of non-organized echogenic debris. The cystic and common bile ducts are normal/not visible.

Gastrointestinal

The stomach contains minimal luminal contents. It measures at a normal thickness of 0.47 cm and appears slightly prominent, with some variability due to the presence of rugal folds. The distinction of the gastric wall layers is adequate and there is no impression of reduced peristaltic activity. No masses or focal lesions were observed.

The visualized areas of duodenum, jejunum and ileum have a relatively uniform diameter with minimal fluid distension. Wall thickness is normal. Bowel loops follow a curvilinear path with distinct wall layering maintaining the typical 1:3 muscularis:mucosa layer ratio. The duodenum measured as normal (between 0.3-0.5cm in wall thickness) and the jejunum measured as normal (between 0.2-0.47cm.) Visualized peristalsis appears appropriate. There were no focal lesions consistent with obstruction or a mass effect observed.

The ileocecal junction was visualized and exhibited normal intact wall layering and is subjectively of normal thickness. Sections of colon are visualized with formed fecal material and gas shadowing distally. There is no observed focal or generalized colon wall thickening or loss of layering.

Pancreas

The pancreas is prominent and hypoechoic as compared to the surrounding isoechoic mesentery. There is no evidence of nodules or cystic lesions. There is no evidence of regional mesenteric inflammation or fluid.

Free Abdomen

Evaluation of the peritoneal cavity did not reveal any evidence of effusion, or subjective lymphadenomegaly. The Medial iliac nodes appear normal and there was no evidence of a caudal aortic thrombus at the bifurcation. The omentum is of normal uniform echogenicity.

Other

A brief view of the heart was submitted. No significant pericardial effusion was seen.

PRIMARY FINDINGS

- Small, ill-defined, hypoechoic nodule in the spleen – There is a non-cavitated, hypoechoic splenic nodule visualized. Differentials include lymphoid hyperplasia, extramedullary hematopoiesis, infiltrative neoplasia, inflammation, other. Cytology or histopathology would be necessary to get a definitive diagnosis.
- Hypoechoic, prominent pancreas – The pancreatic changes are most consistent with mild pancreatitis or a recent episode of pancreatic inflammation.
- Mildly heterogeneous liver – The diffuse hepatic changes are non-specific and could be consistent with vacuolar hepatopathy, nodular hyperplasia, inflammatory/immune-mediated disease, fibrosis, extramedullary hematopoiesis, toxic hepatopathy (e.g., copper), infiltrative neoplasia (less likely) or other hepatopathy.

- Subjectively prominent gastric wall – The stomach wall thickening could be consistent with inflammation, edema, infiltrative neoplasia, imaging artifact due to rugal folds, other.

SECONDARY FINDINGS

- Mild gallbladder debris – likely an incidental finding.

INTERPRETATION OF THE FINDINGS & FURTHER RECOMMENDATIONS

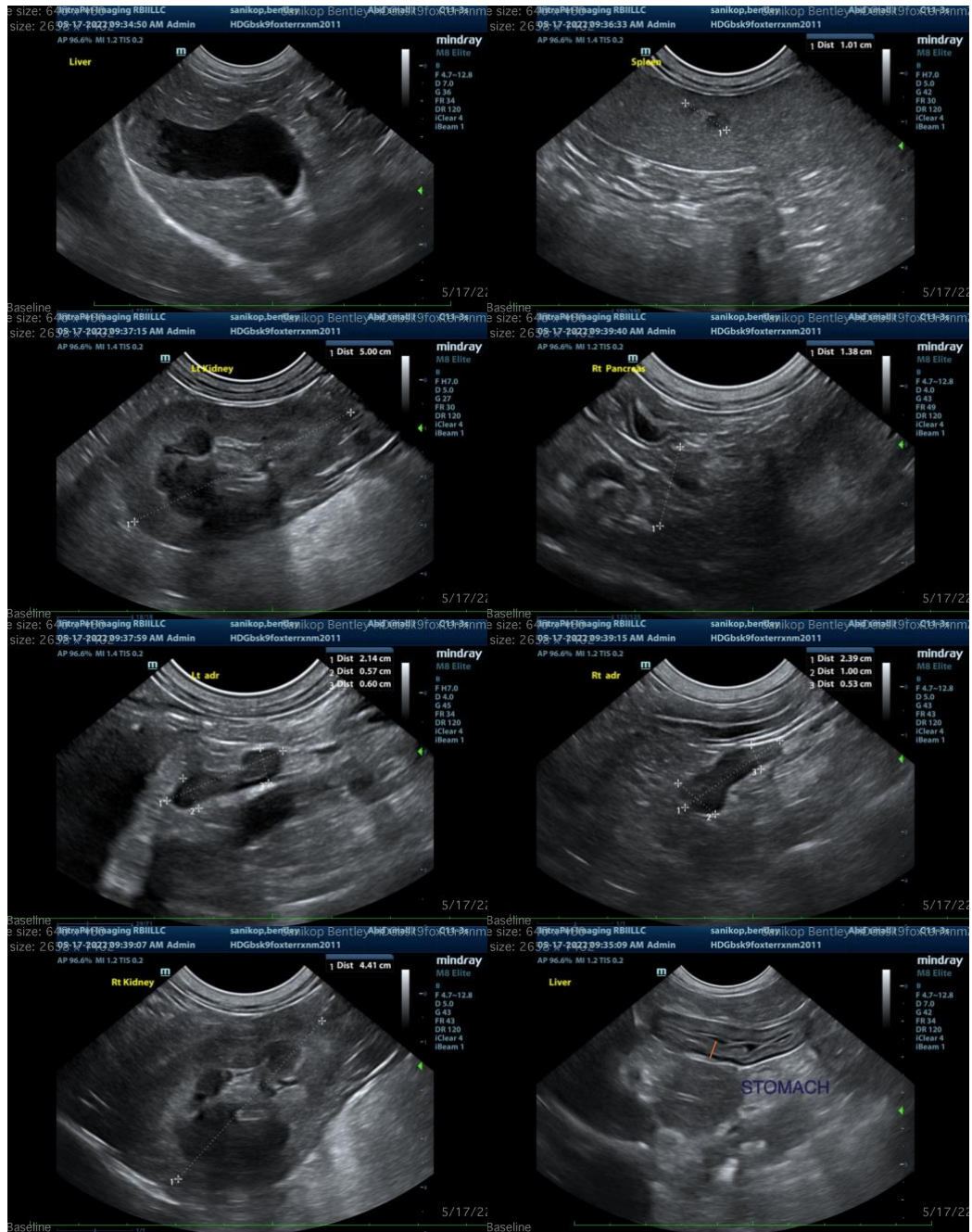
The lesions observed on today's scan are relatively mild. No significant focal gastrointestinal lesions were observed to explain the vomiting and GI signs reported. The pancreas is slightly prominent. The severity of the ultrasonographic lesions does not always correlate with the severity of the clinical signs present. Consider a GI panel to Texas A&M with a qualitative PLI, TLI, cobalamin and folate to further evaluate the pancreas and small intestine. Additionally, recommend supportive treatment for pancreatitis.

No focal lesions are observed associated with the liver. There is very mild debris visualized in the gallbladder, and the liver is somewhat heterogeneous. This is a non-specific finding and can be seen in some normal older pets.

- Consider close evaluation of history for possible toxic changes examine medications, diet, dietary indiscretion etc...
- Consider PCR on urine/serum for leptospirosis (if not on antibiotics)/serology if recent antibiotic history
- If not already done, consider pre and post prandial bile acids to evaluate liver function
- If the ALP is significantly elevated relative to the ALT and symptoms consistent with cushings are present, consider adrenal function testing (ACTH stim)
- Consider Fine needle aspirate if round cell neoplasia is on your differentia list (25 g needle, normal coags)
- If no response to medical care (denamarin, antibiotics,+/- ursodiol etc...) Consider liver biopsy with samples obtained for histopathology, culture, and copper levels.

If the GI signs do not respond to supportive care for pancreatitis, and liver enzyme elevations do not improve over time, consider serial imaging and bloodwork with possible biopsies of the GI tract and liver.

Consider three view thoracic radiographs to rule out concurrent thoracic disease/involvement.



The information and recommendations provided are based on the images presented by the referring veterinarian/sonographer. No evaluation can be communicated regarding pathology that was not visible in the image/video clips provided.

Thank you for this referral. If the clinical or image interpretation does not parallel your findings or if I can be of any further assistance please contact me.

Kathleen Sennello DVM,MS, Diplomate ACVIM (Small animal Internal Medicine)
kathleen.sennello@sonopath.com